

SUPPLEMENTARY DATA

Table 1 of the supplementary data

Technical and clinical definitions

Events/anatomical features	Definition
<i>Blunt entry shape^a</i>	Occluded segment not ended in a funnel-shape.
<i>Severe calcification^b</i>	Severe calcification defined as radiopacities seen without cardiac motion before contrast injection, usually affecting both sides of the arterial lumen.
<i>Procedural success^c</i>	Opening of artery occluded with grade III TIMI flow and < 30% residual stenosis without life-threatening complications.
<i>Periprocedural complication^d</i>	Combined intra cath-lab events: cerebrovascular event, tamponade, access site bleeding, access site hematoma/pseudoaneurysm, Myocardial infarction and coronary perforation/dissection/loss of patency.
<i>Periprocedural death^d</i>	All-cause mortality intra cath-lab.
<i>Periprocedural cerebrovascular event^d</i>	Intra cath-lab sudden onset of neurological signs or symptoms fittings a focal or multifocal vascular territory within the brain, spinal cord or retina. Signs and symptoms typically include an acute onset of one of the following: focal weakness and/or numbness, impaired language production or comprehension, homonymous hemianopia or quadrantanopia, diplopia, altitudinal monocular blindness, hemispatial neglect, dysarthria, vertigo, or ataxia.
<i>In-hospital complication^d</i>	Combination of any event requiring clinical or surgical interventions to prevent life-threatening illness or injury or permanent impairment (bleeding, stroke, access site bleeding, access site hematoma/pseudoaneurysm, myocardial infarction).
<i>In-hospital mortality^d</i>	All-cause mortality during index procedure hospitalization.
<i>Myocardial infarction^d</i>	Absolute rise in cardiac troponin (from baseline) ≥ 35 times upper reference limit, plus 1 (or more) of the following criteria: new significant* Q waves or equivalent, flow-limiting angiographic complications and new "substantial" loss of myocardium on imaging.
<i>Cerebrovascular event^d</i>	Sudden onset of neurological signs or symptoms fittings a focal or multifocal vascular territory within the brain, spinal cord or retina during hospitalization of index procedure. Signs and symptoms typically include an acute onset of 1 of the following: focal weakness and/or numbness, impaired language production or comprehension, homonymous hemianopia or quadrantanopia, diplopia, altitudinal monocular blindness, hemispatial neglect, dysarthria, vertigo, or ataxia.

^aBased on: Morino Y, Abe M, Morimoto T, Kimura T, Hayashi Y, Muramatsu T, et al. Predicting successful guidewire crossing through chronic total occlusion of native coronary lesions within 30 minutes: the J-CTO (Multicenter CTO Registry in Japan) score as difficulty grading and time assessment tool. *JACC Cardiovasc Interv.*2011;4:213-221.

^bBased on: Mintz G. Intravascular imaging of coronary calcification and its clinical implications. *JACC Cardiovasc Imaging.* 2015;8:461-471.

^cBased on: Nombela L, Urena M, Jerez M, Manh C, Barbosa H, Bataille Y, et al. Validation of the J-chronic total occlusion score for chronic total occlusion percutaneous coronary intervention in an independent contemporary cohort. *Circ Cardiovasc Interv.* 2013;6:635-643.

^d Based on: Garcia-Garcia H, McFadden E, Farb A, Mehran R, Stone GW, Spertus J, et al. Standardized End Point Definitions for Coronary Intervention Trials: The Academic Research Consortium-2 Consensus Document. *Circulation.* 2018;137:2635-2650.

Table 2 of the supplementary data

Description of the main plaque modification techniques included in this study*

Technique	Description
BALLOON TECHNIQUES	
<i>Very high-pressure noncompliant balloons (OPN NC SIS MEDICAL AG, Germany)</i>	OPN high-pressure balloons are balloons with double layer technology, which allows inflation up to 35-40 atmospheres, without risk if there is balloon breakage. ⁹
<i>Cutting, shear balloons and incision balloons</i>	The cutting balloon (Boston Scientific, United States) is a noncompliant angioplasty balloon with 3 to 4 longitudinal blades or microtomes that is designed to make longitudinal incisions in the atherosclerotic plaque. The incision balloons are semicompliant balloons surrounded by any material that produces incisions in the plaque and include the AngioSculpt balloon (Angioscore Inc, Spain), surrounded by a nitinol coil, the Scoreflex (OrbusNeich, Hong Kong), with a double guide system, ¹⁰ and the NSE Alpha angioplasty catheter (Braun, Germany) which consists of a balloon with 3 surgical incision elements that are attached only to the proximal and distal region of the balloon. While it is inflated, the surrounding element concentrates the radial force thus obtaining greater anchoring, reducing the possibility of coronary dissection and balloon displacement and allowing precise dilation over the plaque. ¹¹
<i>Intracoronary lithotripsy balloons (Shockwave Medical Lithoplasty System, United States)</i>	Intravascular lithotripsy is based on the same concept as urinary tract lithotripsy, acting by transforming pulses of electrical energy into mechanical and pulsatile energy during inflation of a low-pressure balloon. Plaque modification occurs through the transmission of sound waves from the balloon catheter to the vessel wall, acting selectively on superficial and deep calcium deposits with potential lower risk of occlusion, perforation, or embolization. ¹² Its feasibility was demonstrated with the DISRUPT CAD I study that reported 95% clinical success and its safety and effectiveness were evaluated in DISRUPT CAD II, with clinical success of 94%. ¹³
Debulking techniques	
<i>Rotational atherectomy (Rotablator Boston Scientific, United States)</i>	Rotational atherectomy ablates the calcified plaque using an elliptical diamond-encrusted warhead, which rotates on its axis at speeds of 140 000 to 180 000 RPM. In contrast to angioplasty balloons, which produce intimal and medial dissection, rotational atherectomy produces less tissue injury and results in smooth and more cylindrical surfaces. ¹⁴ Several studies have proved its safety and efficacy. Certain experience regarding its use in CTO lesions has been published suggesting a lower success rate when rotablation was required but similar long-term outcomes. ¹⁵
<i>Orbital Atherectomy (Diamondback 360 Cardiovascular System Inc., United States)</i>	This system consists of a diamond-coated crown mounted eccentrically on a drive shaft, which upon contact with the lesion, ablates it by rotating from 80 000 RPM to 120 000 RPM. This rotation can be bidirectional reducing the risk of entrapment in the lesion. At a lower advance speed, there is a greater luminal gain, so the plaque modification owes its success to the consistent and slow advance of the crown. ¹⁶ Despite the positive results of the ORBIT I ¹⁷ and II trials, ¹⁸ this technology is still not available for coronary use in our setting and was not including in this research.
<i>Excimer laser coronary atherectomy (CVX-300 spectranetics, United States)</i>	Excimer laser atherectomy acts by releasing energy in an ultraviolet range in very small pulses, which allow tissue removal through 3 mechanisms: photochemical, photothermal and photokinetic. Initial randomized trials were controversial, but it is currently used for nondilatable and uncrossable lesions, underexpanded stents or to facilitate the modification of the proximal stump of a CTO(19) with a reported procedural success of 91% and a low complication rate (3%). ^{20,21}

CTO, chronic total occlusion; NC, noncompliant; OPN, high-pressure balloon; RPM, revolutions per minute.

*See references from the main text.

Table 3 of the supplementary data

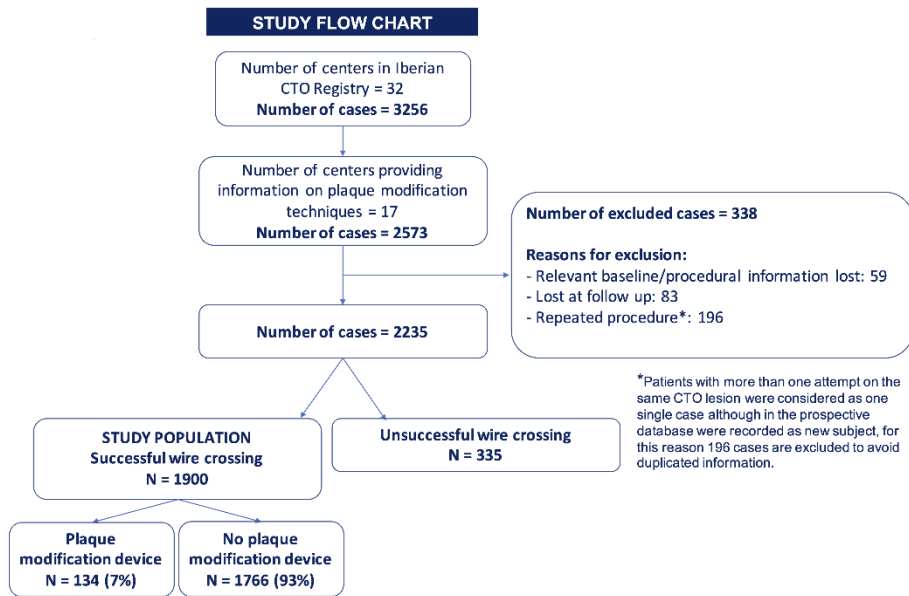
Number of CTO cases and plaque modification devices used according to the institution

Institution	No. of CTO	Use of PMD*	Rotational atherectomy	Laser	Cutting/scoring balloon	Lithotripsy	OPN	1 PMD	2 PMD	3 PMD
1	37	3	1	0	2	0	0	3		
2	59	7	3	0	6	0	1	5	1	1
3	265	10	10	0	1	0	1	8	2	
4	121	10	1	0	6	3	0	10		
5	66	7	2	0	5	1	2	4	3	
6	141	22	6	9	13	0	2	18	6	
7	52	5	1	1	0	2	1	5		
8	104	9	3	0	6	0	1	8	1	
9	158	8	3	0	4	0	1	8		
10	188	17	16	0	3	1	2	15	5	
11	388	4	4	0	0	0	2	3	2	
12	277	13	6	0	7	1	0	12	1	
13	50	2	0	0	0	0	0	0	0	
14	51	11	6	5	1	0	1	9	2	
15	112	2	0	2	0	0	0	2	0	
16	66	3	3	0	0	0	0	1		
17	100	1	1	0	0	0	0	1		
N of patients	2335	134	66	17	54	7	14	110	23	1

CTO, chronic total occlusion; OPN, high-pressure balloon; PMD, plaque modification device.

Figure 1 of the supplementary data.

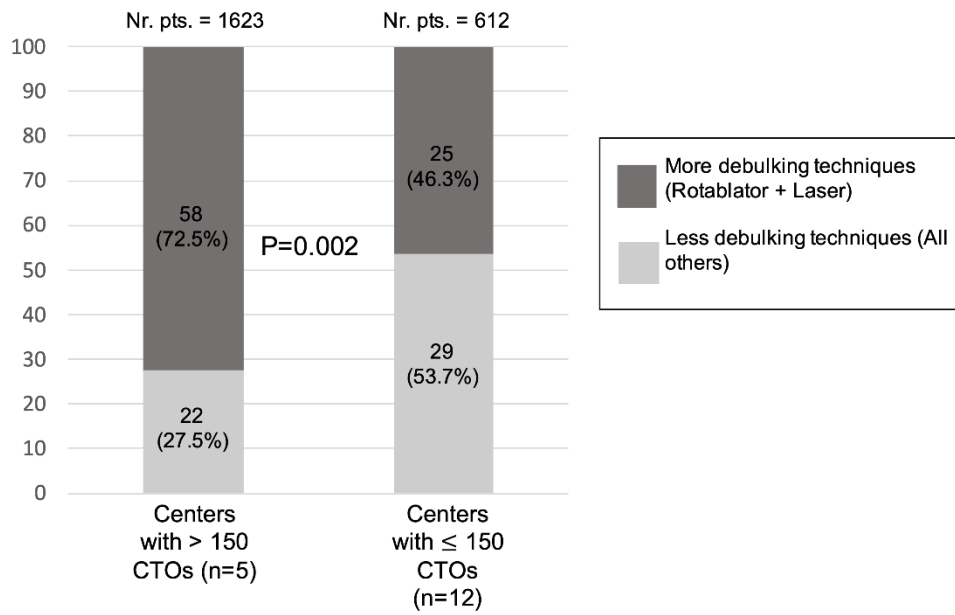
Study flow chart



CTO, chronic total occlusions.

Figure 2 of the supplementary data.

Rate of use of more debulking and less debulking techniques according to center CTO volume during the 2-year study period



CTO, chronic total occlusions.