

SUPPLEMENTARY FIGURE

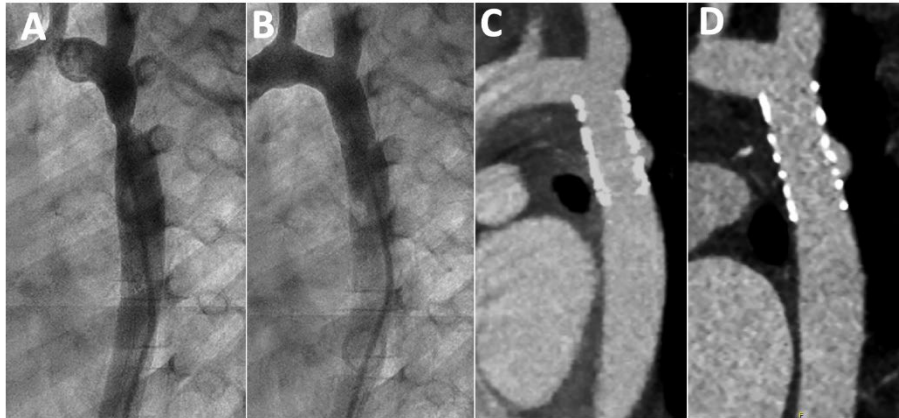


Figure 1 of the supplementary data. Serial CT follow-up of a patient with a small aneurysm. A, baseline angiography; B, immediate result after stent implantation; C, CT at 4 years; D, CT at 6 years of stent implantation. CT, computed tomography.