

SUPPLEMENTARY DATA

Biomarker assay

Serum Epithelial cell adhesion molecule levels were analyzed using the Olink CARDIOVASCULAR III panel (Olink Proteomics, Uppsala, Sweden). The Proximity Extension Assay technology used for the Proseek Multiplex protocol has been well described.¹

In brief, pairs of oligonucleotide-labeled antibody probes bind to their targeted protein; if the 2 probes are brought into close proximity, the oligonucleotides will hybridize in a pair-wise manner. The addition of a DNA polymerase leads to a proximity-dependent DNA polymerization event, generating a unique polymerase chain reaction target sequence. The resulting DNA sequence is subsequently detected and quantified using a microfluidic real-time polymerase chain reaction instrument (Biomark HD, Fluidigm). Data are then quality controlled and normalized using an internal extension control and an inter-plate control to adjust for intrarun and interrune variation. The final assay readout is presented in normalized protein expression values, which is an arbitrary unit on a log₂ scale in which a high value corresponds to a higher protein expression. All assay validation data (eg, detection limits, intraassay and interassay precision data) are available on the manufacturer's website.

Cardiac magnetic resonance acquisition, sequences, and quantification

Images were acquired by a phased-array body surface coil during breath-holds and were triggered by electrocardiography. Cine images were acquired in 2-, 3-, and 4-chamber views, and in short-axis views using a steady-state free precession sequence (repetition time/echo time: 2.8/1.2 ms; flip angle: 58 degrees; matrix: 256 × 300; field of view: 320 × 270 mm; slice thickness: 7 mm).^{2,3}

Late gadolinium enhancement imaging was performed 10 to 15 minutes after administration of 0.1 mmol/kg of gadolinium diethylenetriaminepentaacetic acid (Magnograf, Juste S.A.Q.F., Madrid, Spain) in the same locations as in the cine images using a segmented inversion recovery steady-state free

precession sequence (repetition time/echo time: 750/1.26 ms; flip angle: 45 degrees; matrix: 256 × 184; field of view: 340 × 235 mm; slice thickness: 7 mm). Inversion time was adjusted to null normal myocardium.^{2,3}

Black blood, T₂-weighted short TI inversion recovery sequences were obtained in the same short-axis view as the cine sequences, all in mid-diastole. A half-Fourier acquisition single-shot turbo-spin echo multisection sequence was used (recovery time: 2 R-R intervals; echo time: 33 ms; inversion time: 170 ms; slice thickness: 8 mm; interslice interval: 2 mm; flip angle: 160 degrees; matrix: 256 × 151; bandwidth: 781 Hz/pixel). Additionally, a segmented turbo-spin echo sequence was obtained with 1 slice per breath-hold (recovery time: 2 R-R intervals; echo time: 100 ms; inversion time: 170 ms; slice thickness: 8 mm; interslice interval: 2 mm; flip angle: 180 degrees; matrix: 256 × 146; bandwidth: 235 Hz/pixel).^{2,3}

Left ventricular (LV) ejection fraction (LVEF, %), LV end-diastolic volume index (LVEDVI, mL/m²), LV end-systolic volume index (LVESVI, mL/m²), and LV mass index (g/m²) were calculated by manual planimetry of endocardial and epicardial borders in short-axis view cine images.^{2,3}

Areas showing late gadolinium enhancement were visually quantified by manual planimetry. Infarct size (% of LV mass) was assessed as the percentage of LV mass showing late gadolinium enhancement. Microvascular obstruction (MVO, % of LV mass) was quantified by manual planimetry and defined as the percentage of LV mass showing a lack of contrast uptake in the tissue core showing late gadolinium enhancement.^{2,3}

Myocardial edema was regarded as areas of high T₂ signal intensity. A core of low signal intensity surrounded by an area with high signal intensity indicated myocardial hemorrhage (included in the area of myocardial edema). For all sections, only the T₂-weighted sequence with the highest image quality was used to analyze edema and hemorrhage. All short-axis sections were separately analyzed, and the presence of signal intensity at least 2 SD greater than that of a remote noninfarcted area in the same section indicated edema. Then, myocardial edema and myocardial hemorrhage were

manually revised and expressed as the percentage of LV mass. The myocardial salvage index was calculated by subtracting the mass of infarcted myocardium from myocardium showing edema and expressed as the percentage of LV mass with myocardial edema.^{2,3}

REFERENCES

1. Assarsson E, Lundberg M, Holmquist G, et al. Homogenous 96-plex PEA immunoassay exhibiting high sensitivity, specificity, and excellent scalability. *PLoS One* 2014;9:e95192.
2. Gavara J, Rodriguez-Palomares JF, Valente F, et al. Prognostic value of strain by tissue tracking cardiac magnetic resonance after ST-segment elevation myocardial infarction. *JACC Cardiovasc Imaging*. 2018;11:1448-1457.
3. Miñana G, Núñez J, Bayés-Genís A, et al. ST2 and left ventricular remodeling after ST-segment elevation myocardial infarction: A cardiac magnetic resonance study. *Int J Cardiol*. 2018;270:336-342.

Table 1 of the supplementary data. Baseline characteristics, angiographic indices, and biomarkers of patients with or without 1-week MVO

	With MVO	Without MVO	P
Number of patients	53	53	
Baseline characteristics			
Age, y	58 ± 12	60 ± 13	.407
Male sex, %	39 (74)	42 (79)	.604
Diabetes mellitus, %	14 (26)	8 (15)	.136
Hypertension, %	30 (57)	25 (47)	.203
Dyslipidemia, %	22 (42)	26 (49)	.488
Smoker, %	31 (59)	35 (66)	.632
Killip class, %			.558
1	44 (83)	42 (79)	
2	8 (15)	7 (13)	
3	0 (0)	1 (2)	
4	1 (2)	3 (6)	
Time to reperfusion, min	208 [145-395]	180 [143-345]	.578
GRACE risk score	134 ± 35	133 ± 36	.970
TIMI risk score	2 [1-4]	2 [1-4]	.820
Angiographic indices			
Anterior infarction, %	29 (55)	25 (47)	.283
Multivessel disease, %	14 (26)	18 (34)	.379
TIMI flow grade before PCI, %			.093
0	38 (72)	28 (53)	
1	1 (2)	5 (9)	
2	3 (6)	4 (8)	
3	11 (20)	16 (30)	
TIMI flow grade after PCI, %			.571
0	0 (0)	0 (0)	
1	1 (2)	0 (0)	
2	4 (8)	5 (10)	
3	48 (90)	48 (90)	
Biomarkers			
hs-TnT	3555 [2279-6156]	2313 [919-3680]	.002
Maximum eosinophil count (x 10 ³ cells/mL)	210 [140-333]	200 [170-300]	.802
Minimum eosinophil count (x 10 ³ cells/mL)	20 [10-60]	40 [20-90]	.045
Maximum lymphocyte count (x 10 ³ cells/mL)	2395 [1913-3205]	2510 [1885-3610]	.417
Minimum lymphocyte count (x 10 ³ cells/mL)	1175 [910-1535]	1370 [1025-1880]	.114
EpCAM, pg/mL	4.3 ± 0.9	4.8 ± 1.0	.009

EpCAM, epithelial cell adhesion molecule, GRACE, Global Registry of Acute Coronary Events, hs-TnT, high-sensitive troponin T, MVO, microvascular obstruction, PCI, percutaneous coronary intervention, TIMI, Thrombolysis in Myocardial Infarction.

Data are expressed as No. (%), mean \pm standard deviation, or median [range].

Table 2 of the supplementary data. CMR characteristics of the entire cohort and of patients with and without 1-week MVO

	With MVO	Without MVO	P
<i>Number of patients</i>	53	53	
<i>1-week CMR</i>			
LVEF, %	49 ± 10	56 ± 12	.001
LV end-diastolic volume index, mL/m ²	79 ± 16	75 ± 19	.212
LV end-systolic volume index, mL/m ²	41 ± 12	33 ± 15	.007
LV mass, g/m ²	81 ± 16	74 ± 13	.009
Edema (% of LV mass)	38 ± 14	23 ± 16	<.001
MVO (% of LV mass)	2.3 [0.9-5.2]	0 [0-0]	<.001
Infarct size (% of LV mass)	29 ± 13	13 ± 10	<.001
Myocardial salvage index, %	24 ± 21	39 ± 32	.005
Intramyocardial hemorrhage (No. of segments)	2 [0-3]	0 [0-0]	<.001
<i>6-month CMR</i>			
LVEF, %	54 ± 13	62 ± 9	<.001
LV end-diastolic volume index, mL/m ²	83 ± 23	70 ± 15	.001
LV end-systolic volume index, mL/m ²	40 ± 20	27 ± 9	<.001
LV mass, g/m ²	74 ± 18	68 ± 15	.062
MVO (% of LV mass)	0 [0-0]	0 [0-0]	.143
Infarct size (% of LV mass)	23 ± 10	12 ± 9	<.001

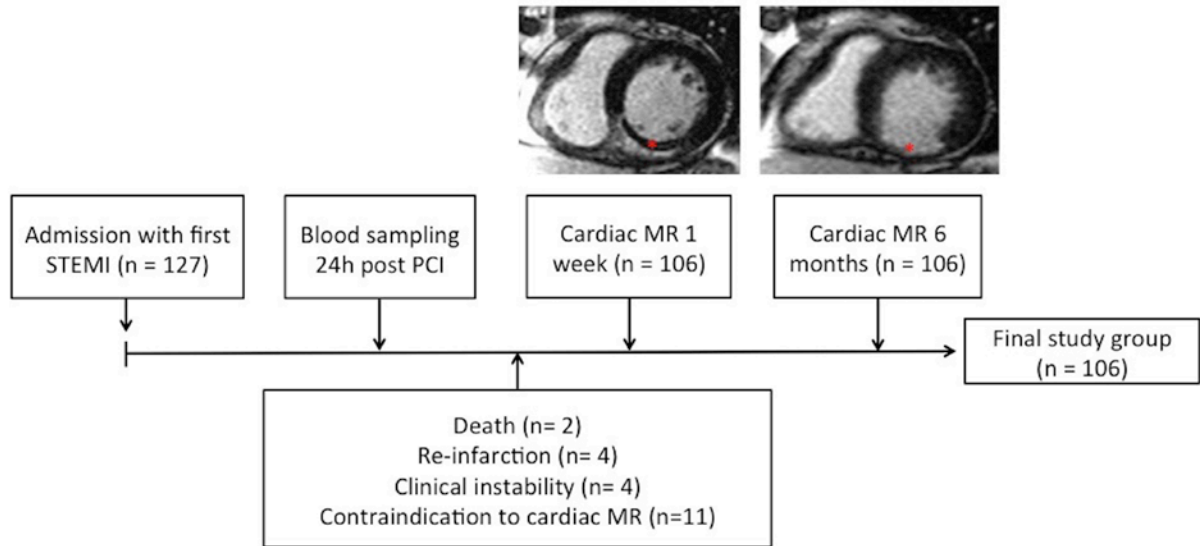
CMR, cardiovascular magnetic resonance, LV, left ventricular, LVEF, left ventricular ejection fraction,

MVO, microvascular obstruction.

Data are expressed as mean ± standard deviation or median [range].

FIGURE LEGENDS

Figure 1 of the supplementary data. Flowchart of the enrolment protocol for STEMI patients. Asterisks indicate regions with MVO.



MR, magnetic resonance. MVO, microvascular obstruction, PCI, percutaneous coronary intervention, STEMI, ST-segment elevation myocardial infarction.