Official publication of the Brazilian Society of Dermatology

Anais Brasileiros de Dermatologia

Volume 100 ■ Number 5 ■ 2025

FI = 3,6

Kaposi's sarcoma overlying Mpox scars–Case report
Ribeiro Júnior J.P., et al

- Pressure injury: update on general concepts, clinical aspects, and laboratory findings – Part I
- Bullous pemphigoid: epidemiological, clinical, and therapeutic analysis of 189 patients in a tertiary center in Brazil
- Chronic spontaneous urticaria: update on pathogenesis and therapeutic implications
- Phenol in dermatology: updated evidence on efficacy and safety
- Artificial intelligence on inflammatory dermatoses: where we are and where are we going?

www.anaisdedermatologia.org.br

ANAIS BRASILEIROS DE DERMATOLOGIA V. 100 N. 5 SEPTEMBER/OCTOBER 2025

SOCIEDADE BRASILEIRA DE DERMATOLOGIA

Anais Brasileiros de
Dermatologia

www.anaisdedermatologia.org.br

Volume 100. Number 5. September/October 2025

CONTENTS

Continuing Medical Education

Original Article

Review

Special Article

Letter - Research

Letter - Clinical

Letter - Dermatopathology

Letter - Tropical/Infectious and parasitic dermatology

Letter - Therapy

Anais Brasileiros de Dermatologia 2025;**100(5)**:501187

SOCIEDADE BRASILEIRA DE DERMATOLOGIA

Anais Brasileiros de Dermatologia

www.anaisdedermatologia.org.br

CONTINUING MEDICAL EDUCATION

Pressure injury: update on general concepts, clinical aspects, and laboratory findings – Part I☆

Bruna Cristina Velozo [a], Michelle Venâncio Hong [a], Larissa Cassiano Bernardo [a], Meire Cristina Novelli e Castro [a], Jose Contreras-Ruiz [b], Luciana Patricia Fernandes Abbade [c,*]

[a] *Department of Nursing, Faculty of Medicine, Universidade Estadual Paulista, Botucatu, SP, Brazil*
[b] *Polanco Dermatological Center Los Cabos, Dr. Manuel Gea González General Hospital, Mexican Institute for Advanced Wound Care, Mexico*
[c] *Department of Infectology, Dermatology, Imaging Diagnosis and Radiotherapy, Faculty of Medicine, Universidade Estadual Paulista, Botucatu, SP, Brazil*

Received 23 January 2025; accepted 9 March 2025
Available online 18 August 2025

KEYWORDS
Classification;
Epidemiology;
Pressure ulcer;
Risk factors

Abstract Pressure injuries remain a significant challenge in healthcare services. They negatively impact these services by increasing workload, financial burden, and direct and indirect costs related to detection, prevention, treatment, and rehabilitation. It is of utmost importance that dermatologists and other healthcare professionals are knowledgeable about these lesions. The first part of this review discusses the history and terminology of pressure injuries, epidemiology in different settings, from adults to pediatric and neonatal patients; etiopathogenesis, demonstrating the current scheme of the vicious cycle of ischemia and tissue death; associated risk factors, both intrinsic and extrinsic; classification of all stages of pressure injuries with clinical images; and the main anatomical areas at risk in each position – lateral, seated, supine, prone, and with medical devices. Differential diagnoses were detailed, including incontinence-associated dermatitis, and the ''Kennedy terminal ulcer'', providing support for proper evaluation and guidance on preventive measures and treatment, which will be further detailed in Part II of this review. The primary focus was to provide resources for healthcare professionals to holistically assess, prescribe, and monitor patients at risk for or with pressure injuries.

☆ Study conducted at the Department of Infectology, Dermatology, Imaging Diagnosis and Radiotherapy, Faculty of Medicine, Universidade Estadual Paulista, Botucatu, SP, Brazil.

* Corresponding author.
E-mail: fernandes.abbade@unesp.br (L.P. Abbade).

https://doi.org/10.1016/j.abd.2025.501187

Introduction

The pressure injury (PI), also known as a ''pressure ulcer'', is a localized area of injury to the skin and/or underlying tissue, usually over a bony prominence. It may present as an area of seemingly intact skin with non-blanchable erythema, blistering, or an ulcer with complete loss of skin and possible involvement of underlying deep tissues such as muscles and bones. Medical-device-related PI was defined as resulting from the use of devices designed and applied for diagnostic or therapeutic purposes. The resulting PI conforms to the device's pattern or shape.[1]

PI is a persistent healthcare condition. It represents one of the most challenging clinical problems that negatively impact patients' lives in emotional, psychological, physical, and social aspects, thus globally reducing their quality of life.[2] PI also has repercussions on healthcare institutions, leading to increased workload and financial burden. Unfortunately, its incidence and burden remain at high levels,[3] mainly after the COVID-19 pandemic.[4]

The economic impact of PI includes expenses for detection, prevention, treatment, and rehabilitation.[5] The cost of treating a PI per patient per day varies between 1.71 and 470.49 euros in all scenarios.[6] In Intensive Care Units (ICUs), PI can generate even higher costs, especially with more severe and deeper wounds.[5]

Based on the best available scientific evidence, this review highlights the importance of dermatologists and other healthcare professionals knowing about Pressure Injuries (PIs), particularly their ability to diagnose and differentiate PIs from other similar lesions effectively. Additionally, it considers the most current mechanisms of PI development, classifications, and clinical aspects to support healthcare professionals in their clinical routines. This includes assessing patients for potential risk factors to take assertive preventive measures and facilitating early identification of PIs to intervene and prevent complications promptly.

History of pressure injuries

PIs have been a part of human history since ancient times. The earliest known historical reference comes from paleopathologists who identified extensive PI on the ischial bones and scapulas of a mummy belonging to an elderly priestess of Amun from the 21st Dynasty of ancient Egypt (1070 to 945 BC).[7] The first written record of PI corresponds to Hippocrates (460–370 BC), who described the appearance of such lesions in a paralyzed patient with bladder and bowel dysfunctions.[8]

During the Renaissance, Ambroise Paré (1510–1590), considered the father of modern surgery, made the first documented description of a PI, focusing on addressing its cause to facilitate healing.[7]

Effective measures in the prevention and treatment of PI were already being implemented in the early 19th century. For example, in 1806, J.E. Aronssen from Berlin emphasized the importance of the bed in patient care and presented plans for a new and improved invalid chair of his invention.[9]

The term ''bedsore'' was documented by nurse Florence Nightingale in 1859.[10] This term maintains its association with the bed, despite the understanding at the time that PI can occur whenever soft tissues are in contact with support surfaces, and the significant role played by shear forces and shear deformation. The addition of ''sore, implied a raw'' or painful place on the body.[1]

From the second half of the last century, awareness of PI increased alongside advances in healthcare, prompting various authors to study their etiology. Reichel in 1958[11] and Kosiak in 1959[12] with studies on ischemic injuries contributed significantly to the understanding of etiopathogenesis. The search for Norton et al. in 1962[13] resulted in the first risk assessment scale for PI. The term ''pressure ulcer'' started to gain popularity in the 1970s and 1980s, replacing terms like ''bedsores'' or ''decubitus ulcers'' and ''pressure sores''. The formation of groups such as the National Pressure Ulcer Advisory Panel (NPUAP) in the United States in the 1970s, along with national groups such as the National Group for the Study and Advisory of Pressure Ulcers and Chronic Wounds in Spain (GNEAUPP) in 1994, and the European Pressure Ulcer Advisory Panel (EPUAP) in 1996, propelled the advancement of knowledge about PI during that time.[7]

Significant contributions to the understanding and prevention of PI include the conceptual model by Bergstrom et al. in 1987[14] who developed the Braden Scale, and Coleman et al. who presented direct and indirect causal factors,[15] and the work of García Fernández et al. in 2014,[16] who introduced the term ''pressure injuries related to dependency''. This work modified the existing classification that GNEAUPP had already adopted and paved the way for reconsidering the term ''pressure injuries'' instead of ''pressure ulcers''. This term was later adopted by the Pan Pacific Pressure Injury Alliance in 2014 and recently, albeit controversially, by the American NPUAP, generating intense debate due to the English connotations of the concept of ''injury''.[17] Thus, the NPUAP incorporated the ''injury'' (National Pressure Injury Advisory Panel – NPIAP),[1] however, in Europe, the EPUAP term pressure ulcer remains without this modification.[1]

Epidemiology

Assessing PI incidence is of utmost importance in demonstrating the relevance of this adverse event in hospital settings. It is crucial for healthcare professionals at the bedside and service managers, as it indicates the quality of care provided,[18] becoming a threat to patient safety.[19]

The prevalence of PI remains high in the global population, proportional to aging and the increasing prevalence of precipitating factors such as obesity, diabetes, and cardiovascular diseases.[20] Conversely, the incidence varies widely according to the clinical setting and is higher among high-risk groups. It is reported to be up to 60% among quadriplegics and people with spinal cord injuries, 66% among patients

undergoing prolonged surgeries, and 70% among older people patients with hip or femoral fractures.[20]

The global prevalence of PI reported in a systematic review in hospitalized patients is 12.8%, with an incidence rate of 5.4 per 10,000 patient days.[21] The same review found that 61.8% of PIs were acquired in hospitals, and 30% of all lesions were considered severe (Stages 3 and 4).[21]

Brazil is the country that reports the most studies on the incidence and prevalence of PI in Latin America.[22] According to the National Report on Healthcare-Related Incidents reported to the National Health Surveillance Service from 2014 to 2022, out of 1,100,352 reported incidents, 223,378 (20.3%) were related to PIs. During this period, PIs were the second most frequently reported type of event by the Patient Safety Nucleus (NSP) of healthcare services in the country and the fifth leading cause of death related to incidents in healthcare.[23]

Data on the prevalence and incidence of PI should be analyzed cautiously in different studies since authors use different methodologies to calculate these indicators. The main problems are the inclusion of all stages of PI or only those with ulcers and the inclusion of the entire population or only those at risk of developing PI. These differences significantly impact the incidence and prevalence results found in different studies and countries. This limitation has already been found in a systematic review, for example, where not all stages of PIs were included in the studies.[21]

Intensive therapy

In ICUs, patients are considered at high risk for developing PI due to clinical condition-related risk factors, such as immobility, inadequate nutrition, and support therapies like mechanical ventilation and hemodialysis.[19,24] The cumulative incidence and prevalence were 10.0% to 25.9% and 16.9% to 23.8%, respectively in a global systematic review encompassing all diagnostic restrictions and types of ICU.[24]

Pediatric and neonatal

The prevalence and incidence of PI in pediatric populations can vary considerably depending on the clinical context. Few studies focus on this population, but Razmus and Bergquist-Beringer conducted a study covering 678 pediatric acute care units with 39,984 patients in the United States.[25] They reported that the rate of PI acquired in all facilities ranged from 0.57% to 3.7% in the pediatric ICU and 4.6% in rehabilitation settings.[25]

A study in Brazilian hospitals, tracking 314 children, found an average prevalence of 7.1% and an average incidence of 21.8%, with 22 children having 31 cases of PIs. According to the types of wards, the average prevalence was 1.8% in clinical pediatrics, 4.0% in surgical pediatrics, and 32.8% in pediatric ICUs.[26] In another Brazilian study assessing 83 children in a tertiary hospital ICU in the interior of São Paulo, the incidence of PI was 21.6%.[27]

In neonates, injuries from medical devices are more common, especially in the ICU.[28] A study that assessed the incidence of PI in both children and neonates identified a 50% higher risk of PI, primarily due to medical devices, with injuries to the septum from enteral tubes and the use of tracheostomies.[29] Another study evaluated 625 children and neonates, among which those under eight years old developed one or more injuries from medical devices, with an incidence of 7%.[30]

A recent systematic review found the overall pediatric prevalence ranging from 0.47% to 31.2%. The combined prevalence among neonates was 27.0%, among children under 1-year old was 19.2%, and among children over 1-year old was 12.3%. The cumulative incidence of hospital-acquired PI in neonates was 9.8%.[31]

Older people

An increasingly frequent scenario is the institutionalization of older people. Due to the natural characteristics of the aging process and the clinical issues that limit mobility, PI is considered a concern for the safety of elderly individuals living in these institutions.[32]

A systematic review with meta-analysis showed that the prevalence, incidence, and occurrence of PI acquired in elderly care homes were 8.5%, 11.6% and 14.3%, respectively. The most common stages were Stages 1 and 2. The calcaneal and sacral regions were the most frequently affected sites. Additionally, it was observed that the amount of PI among the older people in these institutions is like that found in hospitalized patients.[32]

COVID-19

In patients with COVID-19, particularly those during the pandemic admitted to the ICU, the rates of PIs were significantly high. A study in Brazil demonstrated that out of 80 patients admitted to the ICU due to COVID-19, 44 (55%) developed PI during hospitalization.[33] Another Brazilian study, among the 393 medical records analyzed, identified a prevalence of PI at 167 cases (42.5%), with patients having up to four PI.[34]

In terms of the location of the PI, a difference was noted during the pandemic related to the prone position, in which patients remained for 16 to 24 consecutive hours daily. PI frequently occurred on the bony prominences subjected to this position such as frontal, nasal, pectoral, breast and knee.[35,36] The incidence of PI ranges from 25.7% to 48.5% in the prone position.[37]

A concern about PI related to the use of personal protective equipment by healthcare professionals has also been reported during the pandemic. A systematic review found a high incidence of these injuries, ranging from 30% to 92.8%, predominantly stage 1 PI[38] and 58.8% in another study of the same stage.[39] This is supported by a Brazilian study of ICU professionals, where 91.8% had some form of injury/erythema, primarily in the nasal region (74.1%) and the zygomatic region (45.9%).[40]

Etiopathogenesis

The pathological impact of excessive pressure can be attributed to three factors: the intensity of the pressure, the duration of the pressure, and the capacity of the tissues (including the skin and other structures) to withstand the pressure without sustaining damage.[20] The influence

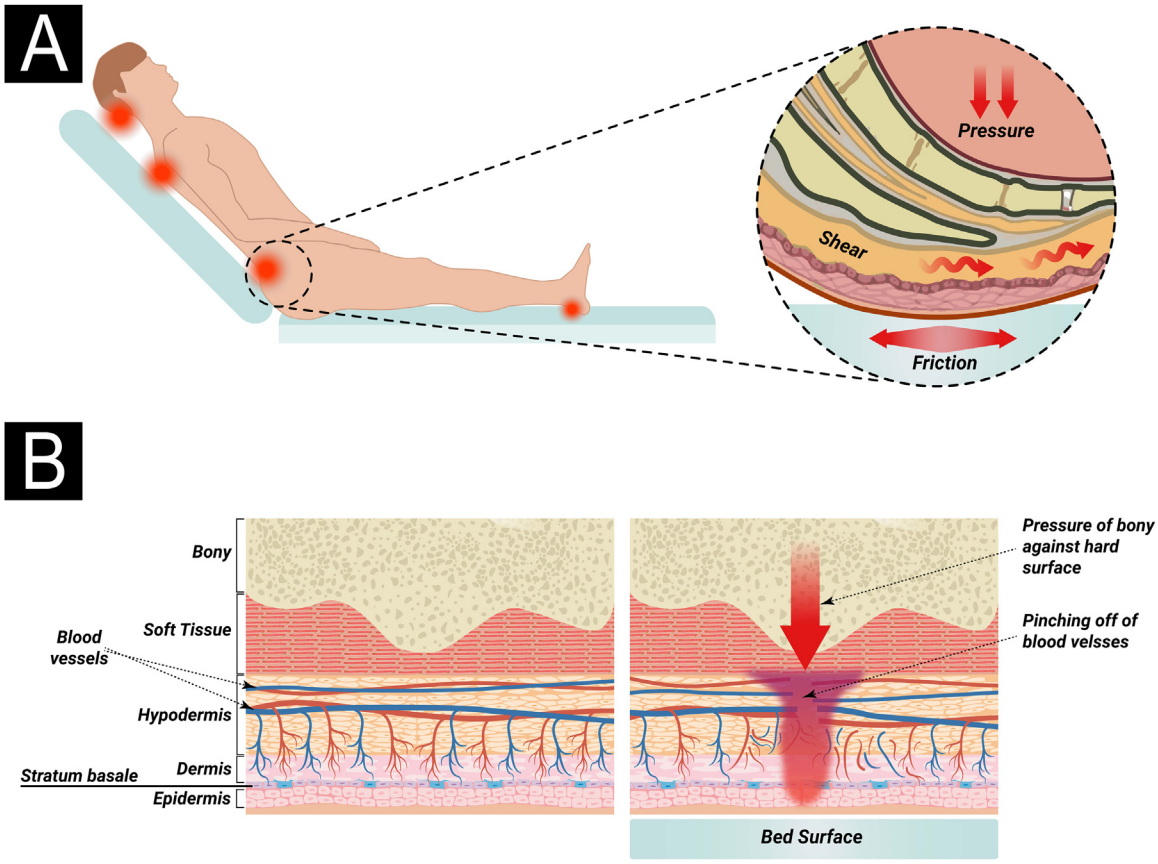

Figure 1 (A) Actions of pressure, friction, and shear over the bony prominence. (B) External pressure and compression of capillaries (from surfaces such as a bed or chair) interfere with local blood flow and, consequently, tissue perfusion, leading to the development of pressure injury. Source: Authors own.

of capillary pressure and capillary closing pressure is crucial in the development of PIs, as insufficient perfusion due to capillary occlusion can lead to cell and tissue death through ischemia, mechanical deformation, and biochemical stress.[41] Compression of capillaries by external pressure can interfere with local blood flow and tissue perfusion. This reduces the supply of oxygen and nutrients to the tissues, resulting in the development of PI in areas subjected to mechanical loads composed of prolonged pressure, shear, and friction forces[41] (Fig. 1A).

In individuals with normal sensitivity, mobility, and mental state, prolonged pressure triggers a feedback response that results in frequent adjustments in body positioning. However, when this feedback response is absent or compromised, sustained and continuous pressure can lead to ischemia, injury, and tissue damage.[42]

Tissue damage occurs due to intense and/or prolonged exposure of soft tissues to sustained mechanical loads, such as compression, traction, or shear forces, or a combination of these loading modes. Sustained loading (quasi-static loading) refers to loads applied continuously over long periods, ranging from minutes to hours or even days[43] (Fig. 1B).

A new conceptual model on the etiopathogenesis of PI was updated by the NPIAP authors in 2022, represented by the PI vicious circle[44] (Fig. 2).

The injury mechanism affects various tissues, from deformation to inflammatory cell damage.[45] Inflammation may intensify due to a pre-existing ischemic condition, especially if reperfusion occurs, for example, immediately after repositioning.[44,46] Reperfusion after a long period of ischemia can further worsen tissue damage, as it leads to the release of harmful free radicals.[47] Persistent deformations in cells, blood vessels, and tissues drive this entire damage pathway, impacting the integrity and function of cellular organelles and leading to tissue and organ malnutrition.[43] These deformations not only cause direct damage to cellular structures but also trigger inflammation and edema, distort the capillary network, reduce nutrient supply to tissues, and obstruct the lymphatic system, impairing the removal of metabolic waste products.[44] Localized tissue deformations can quickly lead to microscopic damage; however, it may take several hours of continuous pressure for this initial cellular and tissue damage to become clinically visible.[41]

Although pressure is the primary triggering factor, the capacity of soft tissues to tolerate sustained deformations varies depending on the type of tissue.[43] It is influenced by other factors, known as intrinsic and extrinsic factors, which will be described next.

Risk factors

The PI occurs due to well-established factors such as pressure, friction, and shear, but several risk factors also

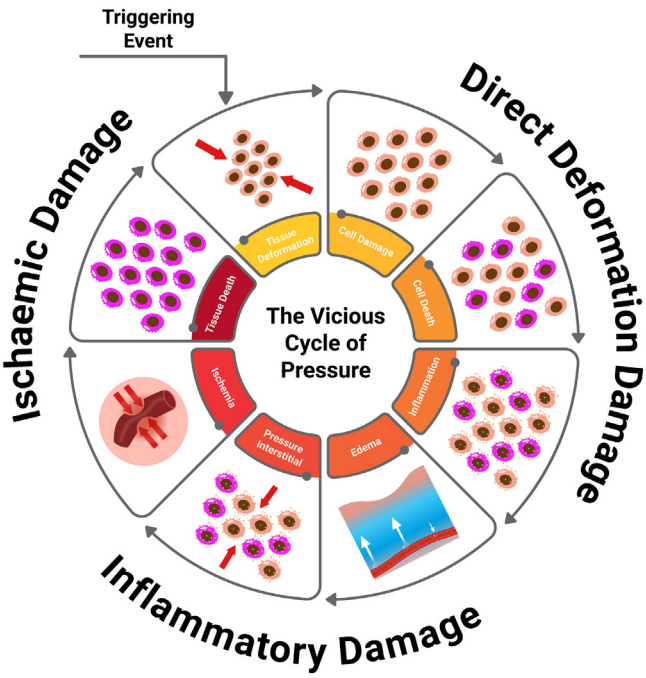

Figure 2 Vicious cycle of PI: direct deformation damage (cellular damage, cell death, and inflammation), inflammatory damage (edema, increased interstitial pressure), ischemic damage (ischemia, tissue death), leading to cellular deformation. Figure adapted from Gefen.[44]

contribute to the development of these injuries.[48] These risk factors are divided into two main domains: extrinsic and intrinsic factors.[49]

Extrinsic factors refer to external conditions or aspects of healthcare practices that can increase the risk of developing PI, such as prolonged pressure, friction and/or shear, moisture, improper handling, medications, hygiene care, and the use of medical devices.[1,50]

Intrinsic factors are related to the individual and physiological characteristics of the patient that can increase their vulnerability to developing PI, such as advanced age, clinical conditions, reduced mobility, urinary and fecal incontinence, hemodynamic status, arterial insufficiency, and malnutrition.[1]

A systematic review with meta-analysis of 39 studies, including over 2.5 million patients worldwide, identified the elderly as a vulnerable patient group. The increase in age is one of the primary risk factors for developing PI, as older individuals tend to have poor skin conditions, inadequate nutrition, and reduced mobility.[21]

Urinary and fecal incontinence results in excess moisture, leading to skin maceration and making it more susceptible to injuries from friction and repositioning.[21,51]

A comprehensive review published in 2024 analyzed several meta-analyses, which systematically highlighted an increased risk of developing PI in patients with diabetes mellitus. Other factors, such as the duration of surgery and the length of stay in the ICU, were also identified as crucial risk elements.[52]

Populations potentially characterized by multiple risk factors include: those who are critically ill and/or in intensive care, individuals with hip fractures, spinal cord injuries, chronic neurological conditions, diabetes mellitus, older people, those residing in long-term care facilities or community care settings, and individuals undergoing trauma and/or prolonged surgery.[1]

Clinical and laboratory assessment and documentation

When collecting the history of the current PI, it is important to pay attention to the qualitative information about the patient, including location, duration, potential causes or triggering factors, dimensions and changes in size, pain (type, severity, frequency, factors that relieve or worsen), characteristics such as exudate, types of tissue and odor, as well as a history of other PI and scars.[42]

It is necessary to evaluate all bony prominences and critical areas related to positioning and invasive devices (Fig. 3). The main sites affected in adults are typically the sacro-coccigeal region and the heels, the latter mainly from being in the dorsal or seated position.[1,21,53] Other frequently affected areas include the ischial region in patients who remain seated and the hip (particularly the trochanter) in patients who lie in the lateral position.[1]

In children, the most affected area, especially in infants who are bedridden in the supine position, is the occipital region, followed by the sacral area and heels. Other locations in children include the ears and nose due to the use of medical devices.[1,54]

Staging

The change in terminology from ''pressure ulcer'' to ''pressure injury'' encompasses both intact skin and ulcerated lesions.[17] Thus, PI describes Stage 1 lesions and deep tissue injuries without ulcerated skin. The staging and examples of anatomical involvement are described in Table 1.[1]

PI is not limited to the skin; it can also occur on mucous membranes, including the respiratory, gastrointestinal, and genitourinary tracts. Mucosal PI is primarily associated with medical devices, typically caused by tubes and/or their stabilization equipment exerting sustained compressive and shear forces on vulnerable mucous membranes and underlying tissues.[1]

The representation of the affected skin layers and images of representative pressure injuries according to each classification are in Figs. 4–10.

Evidence-based recommendations for additional assessment techniques, such as skin temperature evaluation, subepidermal moisture measurement, and skin tone color charts, should be used when assessing skin and tissues and classifying PI, particularly in darker skin tones.[1] Assessment of the skin using subepidermal moisture measurement scanners has gained international attention as it can detect the onset of PI approximately five days before becomes visually apparent,[55] making it a promising advancement in the clinical practice of PI prevention.[56]

Some tools guide the assessment and documentation of PIs, such as the widely used PUSH (Pressure Ulcer Scale for Healing), which provides a guide for evaluating exudate, size, and tissue type, serving as a support for clinical progression.[57,58] Another more current and compre-

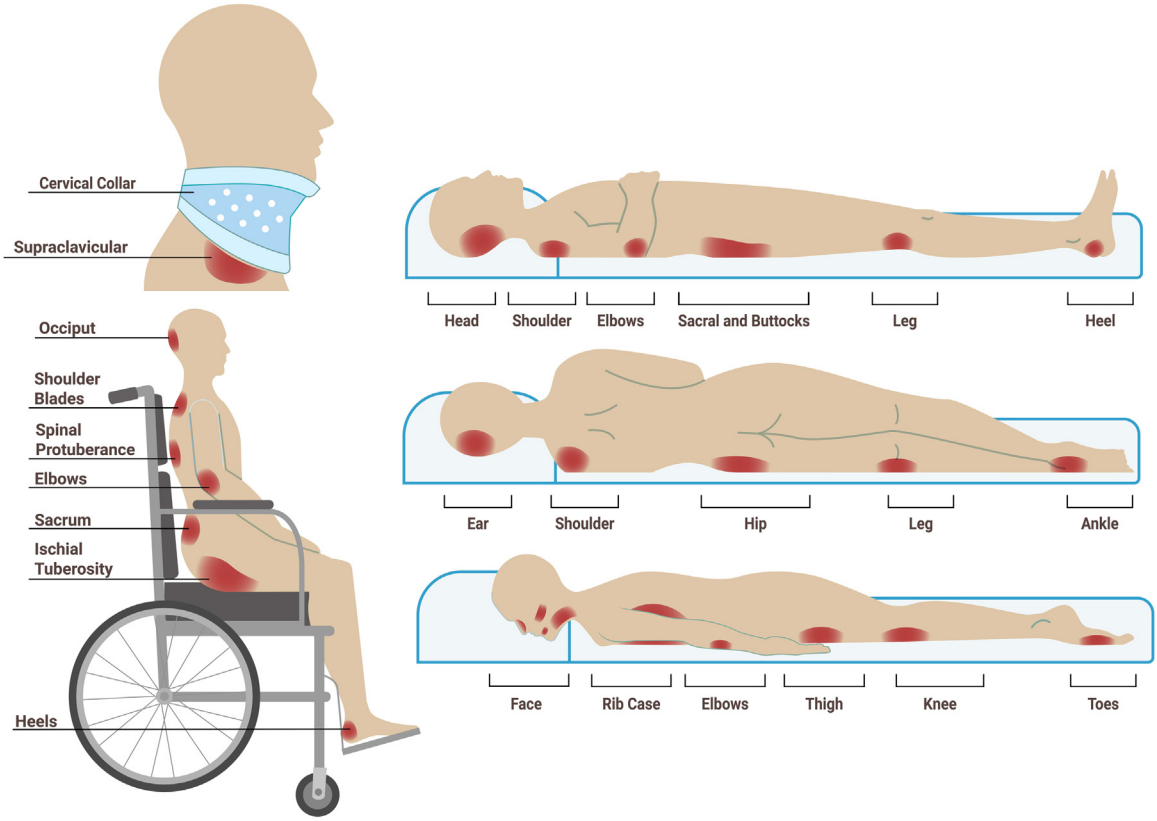

Figure 3 Main bony prominences at risk of developing pressure injuries according to dorsal, lateral, supine, and sitting positions, as well as those related to invasive devices. Sources: Authors' own.

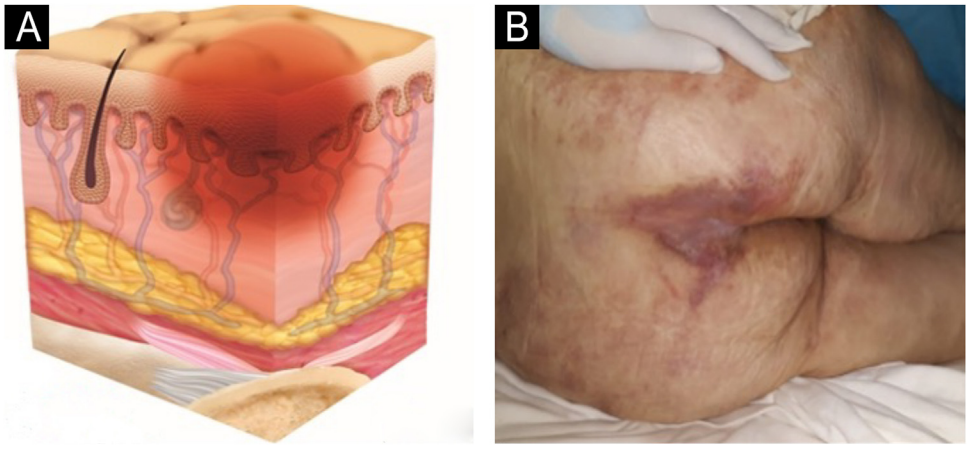

Figure 4 (A) Stage 1 pressure injury. Source with permission of the National Pressure Injury Advisory Panel. (B) Patient with non-blanchable erythema in the sacral region. Source: Authors' own.

hensive tool that supports professionals is the Bates-Jensen Wound Assessment Tool (BWAT)[59] – adapted for Brazil in 2015[60] and its reliability was internationally validated in 2019.[61] The BWAT consists of 13 wound characteristics: size, visible depth, wound edges, undermining and tunneling, type and amount of necrotic tissue, type and amount of exudate, surrounding skin discoloration, peripheral tissue edema, peripheral tissue induration, granulation tissue, and epithelialization.[60,61]

Laboratory aspects

Laboratory tests help assess conditions that can hinder or delay PI healing, such as infection, anemia, poor nutritional status, and diabetes mellitus. It is recommended that a comprehensive metabolic panel, a complete blood count with differential, albumin and prealbumin (to evaluate nutritional status), and hemoglobin A1C be performed.[62]

Table 1 Classification and definition of pressure injuries according to the European Pressure Ulcer Advisory Panel.[1]

Staging	Definition
Stage 1	Intact skin with non-blanchable erythema, does not lighten with pressure in a localized area. Darkly pigmented skin may not show visible blanching; its color may differ from the surrounding areas. The area may be painful, firm, soft, warmer, or cooler compared to the adjacent tissue (Fig. 4A–B).
Stage 2	Partial-thickness loss of dermal thickness, appearing as a superficial ulcer with a red-pink wound bed, without necrotic tissue or bruising. It may also present as an intact or ruptured blister. These injuries do not have necrotic tissue and heal by epithelialization rather than granulation tissue. This stage does not apply to moisture-associated skin damage, such as incontinence-associated dermatitis, intertriginous dermatitis, injury related to medical adhesives, or traumatic wounds like skin tears, burns, and abrasions (Fig. 5A–B).
Stage 3	Full-thickness loss of skin. Subcutaneous tissue may be visible, but bones, tendons, or muscles are not exposed. There may be eschar or slough. Tunneling, undermining, erosions, and epíbole may also be present in Fig. 6A–B.
Stage 4	Full-thickness tissue loss where exposure may reach bone, tendon, or muscle. Slough or eschar may be present in some parts of the wound bed. Often includes erosion and tunneling. Exposed bone/tendon is visible or directly palpable, which may lead to osteomyelitis (Fig. 7A–B).
Deep Tissue Pressure Injury	Persistent discoloration of intact skin or the presence of a blister (bulla), characterized by a translucent lesion that may contain blood-stained, clear, serous, or purulent fluid, suggesting possible deep damage to the underlying tissue (Fig. 8A–B).
Unstageable Pressure Injury	Full-thickness skin and tissue loss in which the base of the wound is covered by eschar (yellow, beige, gray, green, or brown) and/or necrotic tissue (beige, brown, or black) on the wound bed. The stage cannot be determined until the necrotic tissue or eschar is removed to reveal the base of the wound. Excludes PI reclassified to Stage 3 or 4 after exposure or debridement (Fig. 9A–B).
Medical Device-Related Pressure Injury	Caused by using devices designed and utilized for diagnostic or therapeutic purposes. These injuries exhibit a pattern or shape consistent with the device that applies pressure to the skin. They should be classified using a recognized staging system, similar to other PI (Fig. 10A).
Pressure Injury to Mucous Membranes	These injuries occur on the moist membranes lining the respiratory, gastrointestinal, and genitourinary tracts. Medical devices, such as tubes and stabilization equipment primarily cause them. Due to the unique anatomy of these tissues, these injuries cannot be classified into Stage 1 through Stage 4 (Fig. 10B).

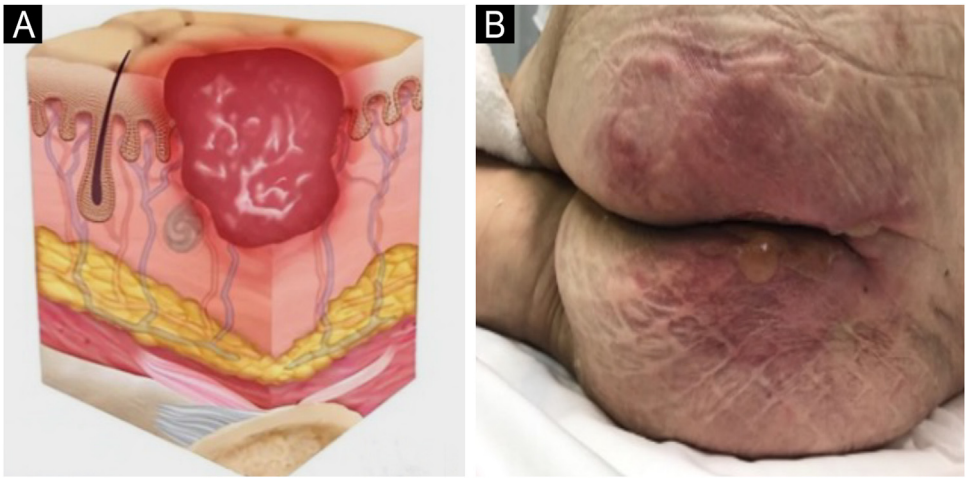

Figure 5 (A) Stage 2 pressure injury. Source with permission of the National Pressure Injury Advisory Panel. (B) Patient with partial-thickness skin loss and an intact blister in the gluteal region. Source: Authors' own.

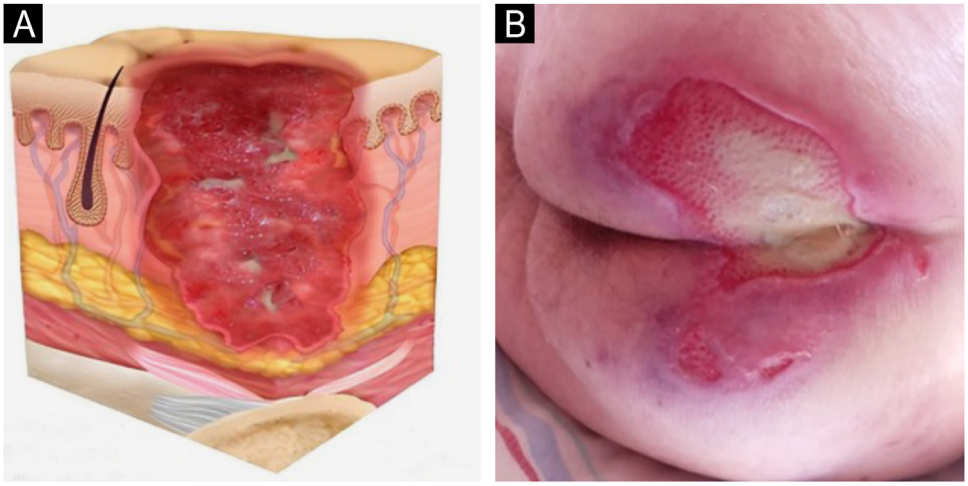

Figure 6 (A) Stage 3 pressure injury. Source with permission of the National Pressure Injury Advisory Panel. (B) Patient with full-thickness dermal loss in the gluteal region and the presence of slough. Source: Authors' own.

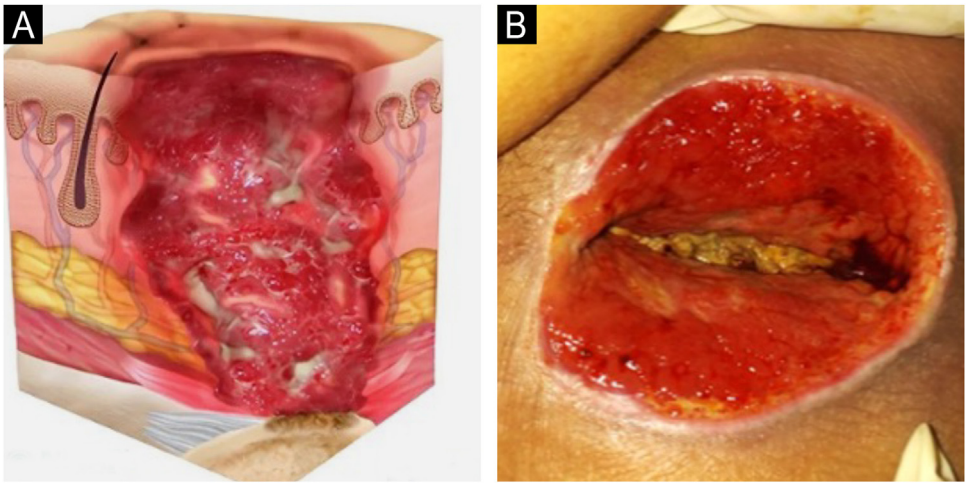

Figure 7 (A) Stage 4 pressure injury. Source with permission of the National Pressure Injury Advisory Panel. (B) Patient with full-thickness skin loss in the sacral region and exposure bone. Source: Authors' own.

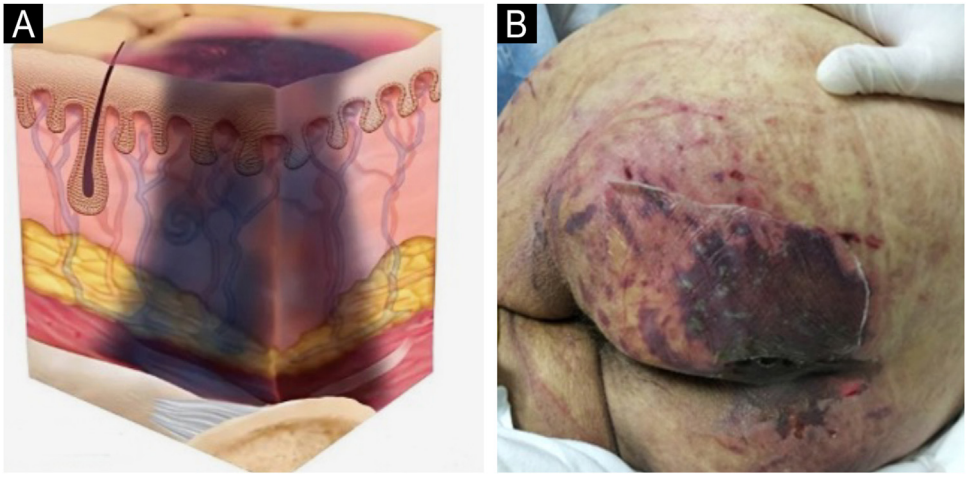

Figure 8 (A) Deep tissue pressure injury. Source with permission of the National Pressure Injury Advisory Panel. (B) Patient with extensive purpuric lesion in the gluteal region. Source: Authors' own.

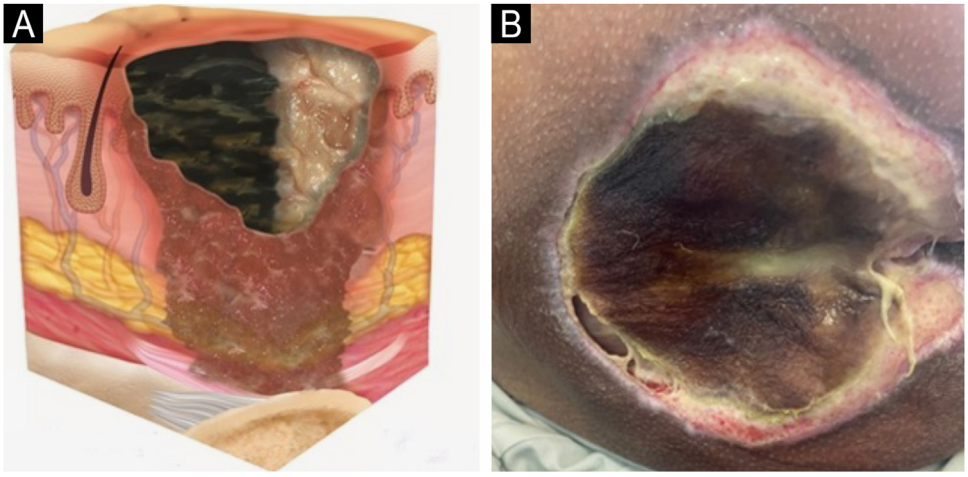

Figure 9 (A) Unstageable pressure injury. Source with permission of the National Pressure Injury Advisory Panel. (B) Patient with liquefactive necrosis and an area of coagulative necrosis in the sacral region, making it impossible to assess the depth of the pressure injury. Source: Authors' own.

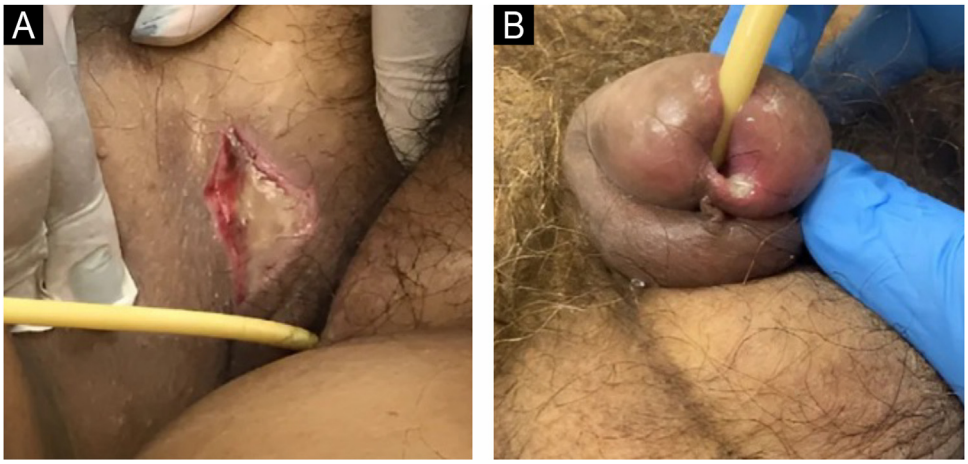

Figure 10 (A) Medical device-related pressure injury in a patient with a pressure injury on the inner surface of the right thigh caused by pressure from an indwelling urinary catheter. (B) Urethral mucosal pressure injury in a patient with an indwelling urinary catheter. Source: Authors' own.

Although swabs to assess for infection remain the most common method for wound sample collection due to their simplicity and low cost,[63] wound cultures from superficial swabs may not be clinically valuable. They often reflect colonization rather than infection, leading to false-positive results.[64–66]

Tissue biopsy is considered the gold standard due to its precision, although it is more invasive, costly, and requires specialized skills for its performance.[63] Additionally, biopsy has greater sensitivity for wounds infected with multidrug-resistant bacteria.[65]

Differential diagnoses

Incontinence-associated dermatitis

Lesions caused by excessive moisture (sweat, exudate, and bodily fluids) compromise the epidermal barrier and can cause skin damage that may be confused with PI.[1] Incontinence-Associated Dermatitis (IAD) is an irritant contact dermatitis and is the most common form of moisture-associated skin damage, as chronic exposure of the skin to urine and feces chemically injures the skin.[1]

The IAD is characterized as an inflammatory dermatosis with erythema, exudation, and excoriation.[67] It also presents with persistent pigmentation changes, edema, maceration, vesicles, or blisters.[68] It affects the perineum, the lower folds of the buttocks, the scrotal region, the thighs, and sometimes even the abdomen (Fig. 11A).

Kennedy terminal ulcer

End-of-life injuries are those that appear hours or weeks before a patient's death.[69] Many synonyms describe the same type of injury, with the most well-known term being the eponym ''Kennedy Terminal Ulcer'' (KTU). KTU was first reported by Karen Lou Kennedy[70] describing a discolored

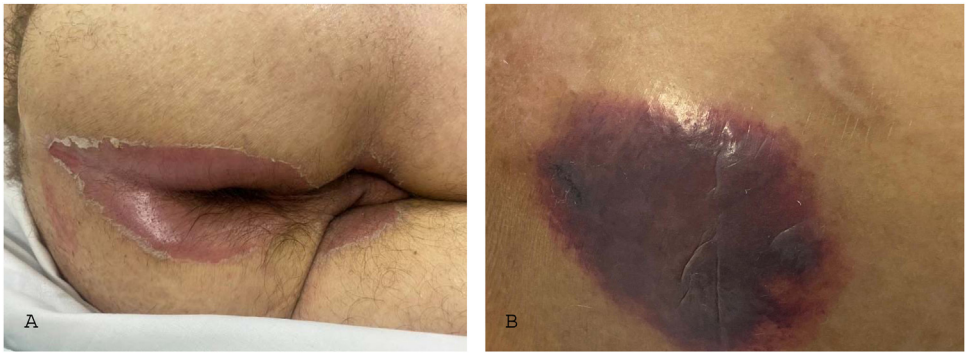

Figure 11 Differential diagnosis of pressure injury. (A) Incontinence-associated dermatitis in a patient with urinary and fecal incontinence who developed intense erythema in the regions intergluteal, perianal and scrotum. (B) Kennedy's terminal ulcer in a patient with multiple organ failure who rapidly developed (within 24 hours) a purpuric plaque in the sacral region.
Source: Authors' own.

skin patch (purple, red, blue or black) usually located in the sacral or coccyx region, although it can affect other body parts, with a butterfly, pear, or horseshoe shape (Fig. 11B). Its progression is very rapid, with full-thickness ulcers evolving over the course of hours or a few days, indicating the imminence of death.[1]

There is debate as to whether KTU is a particular type of PI. However, there is a difference in the pathophysiology between them.[71] PI is caused by unrelieved pressure, often accompanied by shear and friction, resulting in local ischemia and tissue damage. On the other hand, KTU is caused by hypoperfusion and multiorgan failure, and the hypoperfusion of the skin results in visible signs of tissue death. In this scenario, the ischemia associated with multiorgan failure, rather than the damaging effects of unrelieved pressure or shear, results in an unavoidable skin ulcer.[69]

Due to similar purple or brown discoloration and location, it can be challenging to differentiate it from deep tissue PI.[72]

Final considerations

This article aimed to support healthcare professionals and dermatologists in identifying risk factors and mechanisms of PI based on the most current concepts available in the scientific literature. The primary focus was providing resources to help them holistically assess, prescribe, and monitor patients. Additionally, it aimed to assist in evaluating each risk classification and distinguishing other skin conditions like PI.

Some key points of this review include: 1) The prevalence of PI remains high in the global population, with emphasis on patients in ICUs, institutionalized older adults, individuals with hip fractures, trauma or prolonged surgeries, spinal cord injuries, and chronic neurological conditions; 2) Children and neonates are also at risk of PI; 3) PI is not limited to the skin; it can also occur on mucous membranes primarily associated with medical devices; 4) Temperature assessment, subepidermal moisture measurement, and skin tone color charts can be used when assessing skin and tissue and grading PI, particularly in darker skin tones; 5) In cases of PI with suspected infection, wound cultures from superficial swabs are not indicated. A biopsy for microbiological analysis has greater sensitivity in detecting wounds infected with multidrug-resistant bacteria.

The authors invite you to read the subsequent article, which addresses the main complications inherent to PI, practical preventive measures, conventional treatments, and advanced technologies currently in use. Additionally, the next article provides a practical guide focusing on combating biofilm and updating debridement techniques.

Research data availability

The entire dataset supporting the results of this study was published in this article.

Editor

Hiram Larangeira de Almeida Jr.

Financial support

None declared.

Authors' contributions

Bruna Cristina Velozo: Study design and planning; literature review; article writing; critical literature review; critical manuscript review; approval of the final version of the manuscript.

Michelle Venâncio Hong: Study design and planning; literature review; article writing; critical literature review; critical manuscript review; approval of the final version of the manuscript.

Larissa Cassiano Bernardo: Study design and planning; literature review; article writing; critical literature review; critical manuscript review; approval of the final version of the manuscript.

Meire Cristina Novelli e Castro: Study design and planning; literature review; article writing; critical literature review; critical manuscript review; approval of the final version of the manuscript.

Luciana Patrícia Fernandes Abbade: Study design and planning; literature review; article writing; critical litera-

ture review; critical manuscript review; approval of the final version of the manuscript.

Conflicts of interest

None declared.

References

1. European Pressure Ulcer Advisory PanelNational Pressure Injury Advisory PanelPan Pacific Pressure Injury Alliance. In: Prevention and treatment of pressure ulcers/injuries: clinical practice guideline. The International Guideline. 3rd ed. EPUAP/NPIAP/PPPIA; 2019 [cited 2024 Nove 21]. Available from: https://npiap.com/page/Guideline
2. Roussou E, Fasoi G, Stavropoulou A, Kelesi M, Vasilopoulos G, Gerogianni G, et al. Quality of life of patients with pressure ulcers: a systematic review. Med Pharm Rep. 2023;96:123–30.
3. Siotos C, Bonett AM, Damoulakis G, Becerra AZ, Kokosis G, Hood K, et al. Burden of pressure injuries: findings from the global burden of disease study. Eplasty. 2022;22:e19.
4. Bourkas AN, Zaman M, Sibbald RG. COVID-19 and hospital-acquired pressure injuries: a systematic review. Adv Skin Wound Care. 2023;36:421–34.
5. McEvoy N, Avsar P, Patton D, Curley G, Kearney CJ, Moore Z. The economic impact of pressure ulcers among patients in intensive care units. A systematic review. J Tissue Viability. 2021;30:168–77.
6. Demarre L, Van Lancker A, Van Hecke A, Verhaeghe S, Grypdonck M, Lemey J, et al. The cost of prevention and treatment of pressure ulcers: a systematic review. Int J Nurs Stud. 2015;52:1754–74.
7. Torra-Bou JE, Verdú-Soriano J, Sarabia-Lavin R, Paras-Bravo P, Soldevilla-Ágreda JJ, López-Casanova P, et al. A contribution to the historic framework of pressure ulcers. Gerokomos. 2017;28:151–7.
8. Agrawal K, Chauhan N. Pressure ulcers: back to the basics. Indian J Plast Surg. 2012;45:244–54.
9. Parish LC, Witkowski JA, Crissey JT, editors. The decubitus ulcer in clinical practice. Heidelberg: Springer Berlin, Springer Science & Business Media; 2012., http://dx.doi.org/10.1007/978-3-642-60509-3.
10. Nightingale F. Notes on nursing: what it is, and what it is not. [Internet]. Facsimile of the 1st ed. Originally published: London: Harrison, 1859. Reproduced by Philadelphia: J.B. Lippincott Company; 1946. [cited 2024 Nov 26]. Available from: https://archive.org/details/notesnursingwhat00nigh/page/n9/mode/1up.
11. Reichel SM. Shearing force as a factor in decubitus ulcers in paraplegics. J Am Med Assoc. 1958;166:762–3.
12. Kosiak M. Etiology and pathology of ischemic ulcers. Arch Phys Med Rehabil. 1959;40:62–9.
13. Norton D, McLaren R, Exton-Smith AN. An investigation of geriatric nursing problems. Churchill Livingstone; 1962. p. 69–99.
14. Bergstrom N, Braden BJ, Laguzza A, Holman V. The Braden scale for predicting pressure sore risk. Nurs Res. 1987;36:205–10.
15. Coleman S, Gorecki C, Nelson EA, Closs SJ, Defloor T, Halfens R, et al. Patient risk factors for pressure ulcer development: systematic review. Int J Nurs Stud. 2013;50:974–1003.
16. García-Fernández F, Soldevilla Agreda J, Pancorbo-Hidalgo P, Verdú Soriano J, López-Casanova P, Rodríguez-Palma M (Technical Documents GNEAUPP nº II National Group for the Study and Counselling on Pressure Ulcers and Chronic Wounds Logroño) [cited 2024 Nov 27]. Available from: https://gneaupp.info/clasificacion-categorizacion-de-las-lesiones-relacionadas-con-la-dependencia-2/, 2014.
17. National Pressure Ulcer Advisory Panel. In: National Pressure Ulcer Advisory Panel (NPUAP) announces a change in terminology from pressure ulcer to pressure injury and updates the stages of pressure injury. [Internet]. Washington (DC): National Pressure Ulcer Advisory Panel; 2016 [cited 2024 Nov 26]. Available from: https://www.npuap.org/national-pressure-ulcer-advisory-panel-npuap-announces-a-change-in-terminology-from-pressure-ulcer-to-pressure-injury-and-updates-the-stages-of-pressure-injury/
18. de Almeida Medeiros AB, da Conceição Dias Fernandes MI, de Sá Tinôco JD, Cossi MS, de Oliveira Lopes MV, de Carvalho Lira ALB. Predictors of pressure ulcer risk in adult intensive care patients: a retrospective case-control study. Intensive Crit Care Nurs. 2018;45:6–10.
19. Labeau SO, Afonso E, Benbenishty J, Blackwood B, Boulanger C, Brett SJ, et al. Prevalence, associated factors and outcomes of pressure injuries in adult intensive care unit patients: the DecubICUs study. Intensive Care Med. 2021;47:160–9.
20. Hajhosseini B, Longaker MT, Gurtner GC. Pressure injury. Ann Surg. 2020;271:671–9.
21. Li Z, Lin F, Thalib L, Chaboyer W. Global prevalence and incidence of pressure injuries in hospitalised adult patients: a systematic review and meta-analysis. Int J Nurs Stud. 2020;105:103546.
22. Sánchez-Cruz LY, Martínez-Villarreal AA, Lozano-Platonoff A, Cárdenas-Sánchez A, Contreras-Ruiz J. Epidemiología de las úlceras cutáneas en latinoamérica. Med Cutan Iber Lat Am. 2016;44:183–97.
23. Agência Nacional de Vigilância Sanitária (BR). In: Notificação ANVISA 2022: eventos adversos LP [Internet]. Brasília (DF): ANVISA; 2023 [cited 2024 Nov 26]. Available from: https://www.gov.br/anvisa/pt-br/centraisdeconteudo/publicacoes/servicosdesaude/relatorios-de-notificacao-dos-estados/eventos-adversos/2023/brasil/view
24. Chaboyer WP, Thalib L, Harbeck EL, Coyer FM, Blot S, Bull CF, et al. Incidence and prevalence of pressure injuries in adult intensive care patients: a systematic review and meta-analysis. Crit Care Med. 2018;46:e1074–81.
25. Razmus I, Bergquist-Beringer S. Pressure injury prevalence and the rate of hospital-acquired pressure injury among pediatric patients in acute care. J Wound Ostomy Continence Nurs. 2017;44:110–7.
26. Pellegrino DMd S, Chacon JMF, Blanes L, Ferreira LM. Prevalence and incidence of pressure injuries in pediatric hospitals in the city of São Paulo, SP, Brazil. J Tissue Viability. 2017;26:241–5.
27. Vocci MC, Miot HA, Fontes CMB, Abbade LPF. Pressure injury risk assessment in pediatric intensive care: a prospective validation study of the Glamorgan scale and predictive comparison with the Braden Q scale. Adv Skin Wound Care. 2023;36:1–7.
28. Behr JH, Wardell D, Rozmus CL, Casarez RL. Prevention strategies for neonatal skin injury in the NICU. Neonatal Netw. 2020;39:321–9.
29. Marufu TC, Setchell B, Cutler E, Dring E, Wesley T, Banks A, et al. Pressure injury and risk in the inpatient paediatric and neonatal populations: a single centre point-prevalence study. J Tissue Viability. 2021;30:231–6.
30. Stellar JJ, Hasbani NR, Kulik LA, Shelley SS, Quigley S, Wypij D, et al. Medical device–related pressure injuries in infants and children. J Wound Ostomy Continence Nurs. 2020;47.
31. Triantafyllou C, Chorianopoulou E, Kourkouni E, Zaoutis TE, Kourlaba G. Prevalence, incidence, length of stay and cost of healthcare-acquired pressure ulcers in pediatric populations: a systematic review and meta-analysis. Int J Nurs Stud. 2021;115:103843.
32. Sugathapala RDUP, Latimer S, Balasuriya A, Chaboyer W, Thalib L, Gillespie BM. Prevalence and incidence of pressure injuries among older people living in nursing homes: a systematic review and meta-analysis. Int J Nurs Stud. 2023;148:104605.

33. Povoas Costa L, Silva Barcellos Caetano D, Silva dos Santos J, Silva Solano Ramos dos Santos P. Risk factors for pressure injury in patients with covid-19 in intensive care unit/Fatores de Risco para Lesão Por Pressão em Pacientes com COVID-19 em Unidade de Terapia Intensiva. Rev Pesq Cuid Fund Online. 2022;14:e-11787.
34. Sianes-Gallén M, Pujol-García AM, Rus García M, Partera Luque C, López Postigo M, Call Mañosa S, et al. Pressure injuries during the SARS-CoV-2 pandemic: a retrospective, case-control study. J Tissue Viability. 2021;30:478–83.
35. Yu JN, Wu BB, Feng LP, Chen HL. COVID-19 related pressure injuries in patients and personnel: a systematic review. J Tissue Viability. 2021;30:283–90.
36. Seque CA, Enokihara MMSES, Porro AM, Tomimori J. Skin manifestations associated with COVID-19. An Bras Dermatol. 2022;97:75–88.
37. Patton D, Latimer S, Avsar P, Walker RM, Moore Z, Gillespie BM, et al. The effect of prone positioning on pressure injury incidence in adult intensive care unit patients: a meta-review of systematic reviews. Aust Crit Care. 2022;35:714–22.
38. Tezcan B, Eraydin C, Karabacak BG. Protective equipment-related pressure ulcers in healthcare workers during COVID-19 pandemic: a systematic review. J Tissue Viability. 2022;31:213–20.
39. Su H, Zhou W, Kong Y, Zhu F, Xu B, Shen X, et al. Incidence of facial pressure injuries in health-care professionals during the COVID-19 pandemic: a systematic review and meta-analysis. Int J Nurs Pract. 2023;29:e13125.
40. Spadotto Sd F, Velozo BC, Serafim CTR, Cyrino CMS, Abbade LPF, Nunes HRd C, et al. Lesões por pressão relacionadas ao uso de máscaras N95 na pandemia por COVID-19. Nursing. 2022;25:7606–17.
41. Gefen A. The complex interplay between mechanical forces, tissue response and individual susceptibility to pressure ulcers. J Wound Care. 2024;33:620–8.
42. Mervis JS, Phillips TJ. Pressure ulcers: pathophysiology, epidemiology, risk factors, and presentation. Am Acad Dermatol. 2019;81:881–90.
43. Gefen A, Edsberg L. The etiology of pressure injuries. In: Haesler E, editor. Prevention and treatment of pressure ulcers/injuries: clinical practice guideline. 2nd ed. Perth (Australia): EPUAP/NPIAP/PPPIA; 2019. p. 16–27.
44. Gefen A, Brienza DM, Cuddigan J, Haesler E, Kottner J. Our contemporary understanding of the aetiology of pressure ulcers/pressure injuries. Int Wound J. 2022;19:692–704.
45. Gefen A. The future of pressure ulcer prevention is here: detecting and targeting inflammation early. EWMA J. 2018;19:7–13.
46. Loerakker S, Manders E, Strijkers GJ, Nicolay K, Baaijens F, Bader DL, et al. The effects of deformation, ischemia, and reperfusion on the development of muscle damage during prolonged loading. J Appl Physiol (1985). 2011;111:1168–77.
47. Bullkich E, Kimmel E, Golan S. A novel ischemia reperfusion injury hereditary tissue model for pressure ulcers progression. Biomech Model Mechanobiol. 2019;18:1847–66.
48. de Campos MMY, de Sousa MFC, Whitaker IY. Risk factors for pressure ulcers development in intensive care unit patients. Revista Cuidarte. 2021;12:e1196.
49. National Pressure Ulcer Advisory PanelEuropean Pressure Ulcer Advisory PanelPan Pacific Pressure Injury Alliance. In: Haesler E, editor. Prevention and treatment of pressure ulcers: clinical practice guideline [Internet]. Osborne Park (AU): Cambridge Media; 2014 [cited 2024 Nov 29]. Available from: https://npiap.com/general/custom.asp?page=2014Guidelines
50. Coleman S, Nelson EA, Keen J, Wilson L, McGinnis E, Dealey C, et al. Developing a pressure ulcer risk factor minimum data set and risk assessment framework. J Adv Nurs. 2014;70:2339–52.
51. Almeida RMF, Tura LFR, Silva RCD. Preventive measures for pressure injuries: structure of social representations of nursing teams. Rev Esc Enferm USP. 2022;56.
52. Wang I, Walker RM, Gillespie BM, Scott I, Sugathapala R, Chaboyer W. Risk factors predicting hospital-acquired pressure injury in adult patients: an overview of reviews. Int J Nurs Stud. 2024;150:104642.
53. Jiao Y, Yuan C, Wu T, Zhang H, Wei Y, Ma Y, et al. Incidence of pressure injuries in fracture patients: a systematic review and meta-analysis. J Tissue Viability. 2022;31:726–34.
54. Zhang H, Ma Y, Wang Q, Zhang X, Han L. Incidence and prevalence of pressure injuries in children patients: a systematic review and meta-analysis. J Tissue Viability. 2022;31:142–51.
55. Moore Z, McEvoy NL, Avsar P, Byrne S, Budri AMV, Nugent L, et al. Measuring subepidermal moisture to detect early pressure ulcer development: a systematic review. J Wound Care. 2022;31:634–47.
56. Avsar P, Patton D, Cuddigan J, Moore Z. A systematic review on the impact of sub-epidermal moisture assessments on pressure ulcer/injury care delivery pathways. Int Wound J. 2024;21:e14928.
57. Santos VL, Azevedo MA, Silva TS, Carvalho VM, Carvalho VF. Adaptação transcultural do pressure ulcer scale for healing (PUSH) para a língua portuguesa [Crosscultural adaptation of the pressure ulcer scale for healing to the portuguese language]. Rev Lat Am Enfermagem. 2005;13:305–13.
58. Stotts NA, Rodeheaver GT, Thomas DR, Frantz RA, Bartolucci AA, Sussman C, et al. An instrument to measure healing in pressure ulcers: development and validation of the pressure ulcer scale for healing (PUSH). J Gerontol A Biol Sci Med Sci. 2001;56:M795–9.
59. Harris C, Bates-Jensen B, Parslow N, Raizman R, Singh M, Ketchen R. Bates-Jensen wound assessment tool: pictorial guide validation project. J Wound Ostomy Continence Nurs. 2010;37:253–9.
60. Alves DFS, Almeida AO, Silva JLG, Morais FI, Dantas SRPE, Alexandre NMC. Translation and adaptation of the Bates-Jensen wound assessment tool for the brazilian culture. Texto Contexto-Enfermagem. 2015;24:826–33.
61. Bates-Jensen BM, McCreath HE, Harputlu D, Patlan A. Reliability of the Bates-Jensen wound assessment tool for pressure injury assessment: the pressure ulcer detection study. Wound Repair Regen. 2019;27:386–95.
62. Podd D. Beyond skin deep: managing pressure injuries. JAAPA. 2018;31:10–7.
63. Travis J, Malone M, Hu H, Baten A, Johani K, Huygens F, et al. The microbiome of diabetic foot ulcers: a comparison of swab and tissue biopsy wound sampling techniques using 16S rRNA gene sequencing. BMC Microbiol. 2020;20:163.
64. Livesley NJ, Chow AW. Infected pressure ulcers in elderly individuals. Clin Infect Dis. 2002;35:1390–6.
65. Copeland-Halperin LR, Kaminsky AJ, Bluefeld N, Miraliakbari R. Sample procurement for cultures of infected wounds: a systematic review. J Wound Care. 2016;25:S4–6. S8–10.
66. Tedeschi S, Negosanti L, Sgarzani R, Trapani F, Pignanelli S, Battilana M, et al. Superficial swab versus deep-tissue biopsy for the microbiological diagnosis of local infection in advanced-stage pressure ulcers of spinal-cord-injured patients: a prospective study. Clin Microbiol Infect. 2017;23:943–7.
67. Gray M, Bliss DZ, Doughty DB, Ermer-Seltun J, Kennedy-Evans KL, Palmer MH. Incontinence-associated dermatitis: a consensus. J Wound Ostomy Continence Nurs. 2007;34:45–54.
68. Maskan Bermudez N, Sa BC, Yaghi M, Hargis A, Elman SA. Incontinence-associated dermatitis: a practical guide for the consulting dermatologist. Curr Derm Rep. 2023;12:291–5.

69. Roca-Biosca A, Rubio-Rico L, De Molina-Fernández MI, Martinez-Castillo JF, Pancorbo-Hidalgo PL, García-Fernández FP. Kennedy terminal ulcer and other skin wounds at the end of life: an integrative review. J Tissue Viability. 2021;30:178–82.
70. Kennedy KL. The prevalence of pressure ulcers in an intermediate care facility. Decubitis. 1989;2:44–5.
71. Yastrub DJ. Pressure or pathology: distinguishing pressure ulcers from the Kennedy terminal ulcer. J Wound Ostomy Continence Nurs. 2010;37:249–50.
72. Black JM, Brindle CT, Honaker JS. Differential diagnosis of suspected deep tissue injury. Int Wound J. 2016;13:531–9.

SOCIEDADE BRASILEIRA DE DERMATOLOGIA

Anais Brasileiros de Dermatologia

www.anaisdedermatologia.org.br

ORIGINAL ARTICLE

A randomized clinical trial of silver hydrofiber dressing versus collagenase ointment for venous ulcer: analysis of biofilm-producing bacteria and bacterial clonality☆

Taís Lopes Saranholi [a], Natalie Carlos Ferreira Mello Sampaio [b], Hélio Amante Miot [c], Stéfani Thais Alves Dantas [d], Vera Lucia Mores Rall [d], Luciana Patricia Fernandes Abbade [c,*]

[a] *Nursing Department, Faculty of Medicine, Universidade Estadual Paulista, Botucatu, SP, Brazil*
[b] *Faculty of Medicine, Universidade Estadual Paulista, Botucatu, SP, Brazil*
[c] *Department of Infectology, Dermatology, Imaging Diagnosis and Radiotherapy, Faculty of Medicine, Universidade Estadual Paulista, Botucatu, SP, Brazil*
[d] *Department of Chemical and Biological Sciences, Sector of Microbiology and Immunology, Instituto de Biociências, Universidade Estadual Paulista, Botucatu, SP, Brazil*

Received 20 July 2024; accepted 13 October 2024
Available online 14 July 2025

KEYWORDS
Clinical trial;
Varicose ulcer;
Wound infection

Abstract
Background: Superficial infection in venous ulcers (VU) hinders healing.
Objective: To evaluate the action of hydrofiber dressing with silver (HAg) compared to collagenase ointment (Col) in VU.
Methods: Randomized controlled clinical trial in which patients with VU with superficial infection were randomized to the intervention (HAg) or comparison (Col) group. After 30 days (T30), the primary outcomes evaluated were: rate of ulcers without signs of superficial infection, decrease in bacterial load, presence of biofilm-producing bacteria, and bacterial clonality.
Results: Thirty-four patients (56 ulcers) were included – 18 patients (28 ulcers) in the HAg group and 16 (28 ulcers) in the Col group. There was a reduction in ulcers with superficial infection in both groups over time but with no differences (p = 0.422). There was no decrease in total bacterial load over time (p = 0.054) or between the groups (p = 0.113). There was a reduction in the rate of ulcers with biofilm-forming bacteria over time (p = 0.047) but no differences between groups (p = 0.558). Regarding the clonality of *Staphylococcus aureus*, 92.8% of ulcers in the HAg group and 85% in the Col group, the clones identified at T0 were the same at T30 (p = 0.553). There was no change in the identity of *Pseudomonas aeruginosa* in any ulcer in either group.

☆ Study conducted at the Department of Infectology, Dermatology, Imaging Diagnosis and Radiotherapy, Faculty of Medicine, Universidade Estadual Paulista, Botucatu, SP, Brazil.

* Corresponding author.
E-mail: fernandes.abbade@unesp.br (L.P. Abbade).

https://doi.org/10.1016/j.abd.2025.501162

Study limitations: Short follow-up time.
Conclusion: Both interventions improved the clinical and some microbiologic characteristics, but there was no difference between both interventions. In addition, most ulcers showed indistinguishable genetic profiles of *S. aureus* and *P. aeruginosa* between T0 and T30, with no difference between the groups.

Introduction

Venous ulcers (VU) and other chronic ulcers are contaminated by microorganisms that may come from endogenous secretions, bandages, and their environment. Therefore, it is essential to understand the difference between colonization, critical colonization (superficial infection), and deep infection. The colonization will occur when bacteria replicate on the ulcer wound bed but do not cause damage to the host. However, the environment is susceptible to bacterial infections that happen when there is an increment in the microbial load on the surface of the ulcer (critical colonization or superficial/local infection). Consequently, the levels of pro-inflammatory cytokines increase and promote the deterioration of the granulation tissue and exudate in excess, hampering the healing process. Deep infection occurs when bacteria penetrate peri-wound tissues, replicate, and cause damage to the host, surpassing the immunological defense capacity, manifesting as erythema, edema, increase in temperature, pain at the perilesional region, and fever.[1–3]

Depending on the ulcer environment, different types of biofilms can be produced. Its formation starts when a bacterium in its planktonic form adheres to an exposed surface, which can be biotic or abiotic. After, the microorganisms connect among themselves and attach in an unreversible format. Then, they start to proliferate, activating the *quorum sensing*. The biofilm grows and differentiates itself, becoming a mature biofilm community, and presenting structural characteristics. Next, a matrix of water and polymeric substances such as polysaccharides, proteins, and extracellular DNA is formed. Finally, the mature biofilm starts a dispersion process with the detachment of cells or microcolonies. Dispersion can result in the colonization of new niches and, consequently, new sites of infections with biofilm.[4]

The resistance of biofilm-producing bacteria is a crucial problem in handling and treating chronic ulcers. In a mature biofilm, the bacteria grow slowly due to the deficiency of nutrients, resulting in resistance to topical and systemic antibiotics. Besides, penetration of these substances in the bacterial structure is reduced or incomplete and the biofilm in the ulcer is renewed quickly.[5] Sharp debridement and silver dressing such as hydrofiber with silver (HAg) are lines of treatment described to combat biofilm.[6] However, no method is entirely effective for biofilms, and scientific evidence is short to ensure the best form of removal from the chronic ulcer bed.

Products that promote enzymatic debridement, such as collagenase, are not described to combat biofilm. Collagenase is mentioned as an enzyme derived from the bacterium *Clostridium histolyticum*. It is effective and selective for acting in the collagen in the necrotic tissue without harming the granulation tissue. Thus, the use of it is pointed as possible after sharp debridement.[7] Due to the frequent use of collagenase ointment in clinical practice as a routine treatment in health services, it is possible to use it as a comparative intervention. The study of VU's microenvironment and the search for interventions to combat superficial infection and biofilm are relevant aspects to consider when choosing the best therapeutic strategies to promote healing.

The objective of this study was to evaluate the action of the hydrofiber dressing with silver compared to collagenase ointment, both after sharp debridement, in the control of superficial infection, interfering in the formation of biofilm by *Staphylococcus aureus* and *Pseudomonas aeruginosa*, and in the clonality of the strains isolated in the initial and final time, in patients with VU that had used these interventions for 30-days. This time frame was chosen once the primary objectives were assessing the local superficial infection and microbiological outcomes instead of healing, which needs more time for follow-up.

Materials and methods

A randomized, controlled, open-label clinical trial with a two-arm parallel group design, blinded outcome assessment was conducted with patients with VU with clinical signs of superficial infection. It was registered in the Brazilian clinical trials (ReBEC – RBR – 4kkq2h), and it was approved by the Research Ethics Committee of ''The Medical School (FMB) of São Paulo State University (Unesp), Botucatu Campus,'' under the number 3.055.504. Also, the study was reported following the CONSORT statement.[8]

It was performed on adult patients treated in the Chronic Ulcers Outpatient Clinic of Clinical Hospital of Botucatu Medical School – Unesp, between October 2020 and November 2021.

Participants of the study

The individuals who met all the following inclusion criteria and none of the exclusion criteria were eligible to be included. The criteria were: 1) Age equal or older than 18-years old; 2) Chronic VU (ulcer being active over six weeks) with clinical signs of superficial infection, following the mnemonic criteria rule NERDS[9] if there were at least two of the following: i) N = Nonhealing wounds; ii) E = Exudative wounds; iii) R = Red and bleeding wound surface granulation tissue); iv) D = Debris-yellow or black necrotic tissue on the wound surface; v) S = Smell or unpleasant odor from the wound; 3) Agreement with the procedures proposed in the

study; 4) Sign the written informed consent form (patient or guardian). Exclusion criteria: 1) Ulcers from other etiologies (peripheral arterial disease, hematologic, neoplastic, infectious causes, etc.); 2) Ulcers with deep tissue infections associated with erysipelas, cellulitis or lymphangitis due to the necessity of systematic antibiotic therapy; 3) History of hypersensitivity to proposed treatments; 4) VU associated to peripheral arterial disease that was classified when the Ankle-Brachial Index (ABI) was lower than 0.8 and absence of distal pulses, mainly tibial.

Randomization and interventions

The randomization protocol was implemented using Software Rv 3.1.2, performed per patient, not per wound. To ensure allocation concealment, the randomization list was cared for by an unrelated individual in the clinical selection of participants. Therefore, the randomization was performed at basal Time (T0), and the participant could be allocated into the Collagenase group (Col group) or the Hydrofiber dressing with silver (HAg group).

After enrollment, the area of all ulcers was measured at baseline for all participants. Then, the ulcer was cleaned with a 0.9% saline solution. Next, the collection of material using a swab for microbiologic analysis and sharp debridement of the wound bed was done. This last procedure was performed with local topical anesthesia (lidocaine 4% cream) and kept under an occlusive dressing for 30-minutes. Afterward, the debridement was performed with a curette throughout the ulcerated bed.

Following the superficial debridement, the participants were randomized into two groups. The first group was made of participants treated with the hydrofiber dressing with silver (HAg – AQUACEL® Ag + Extra™) in the shape of a pad with changes needed when saturation was reached (approximately four days). In the second group, the participants were treated with collagenase ointment (Col), which was not associated with the antibiotics (Kollagenase®). The presentation of collagenase was in ointment, and the quantity applied varied with the size of the wound. Still, it should be enough to cover all the wounded beds with a minimum layer of 2 mm, and after being covered with gauze, needing to be changed once a day.

In both groups, the compressive elastic band (Surepress®) was associated with the treatment, having to be applied once daily (in the morning and removed at the end of the day). The compressive elastic band is a compression system made of a unique layer, with pressure around 25 to 35 mmHg on the ankle. In addition, all the participants and the caretakers received instructions to take care of the wound at home during the study period.

Outcomes

The outcomes evaluated after 30-days (T30) were the following.

Primary: (i) Rate of wounds with no sign of superficial infection following the clinical criteria in the mnemonic rule NERDS;[9] (ii) Microbiologic analysis – the rate of ulcers with reduction of bacterial load; rate of ulcers with biofilm-forming bacteria; rate of ulcers with bacterial identity changes (clonality).

Secondary: (i) Clinical improvement of VU assessed by the PUSH scale (Pressure Ulcer Scale for Healing).[10] The total score can range from 0 to 17; higher scores represent the worst conditions for the ulcer; (ii) Decrement of ulcer area using the planimetric method; (iii) Healing rate assessed clinically by the observation of the total epithelialization without the presence of crusts at the place of VU; (iv) Adverse local events related to the interventions.

All the outcomes were evaluated by an independent clinician blinded to treatment allocation.

Microbiologic analysis

The ulcers were irrigated with a 0.9% saline solution over mechanical pressure to collect the samples. A sterile gauze mold with a central opening of 1 cm^2 was placed onto the wound bed with the appearance of the most unviable tissues. The swab was moistened with a sterile saline solution (0.9%) and rubbed along the exposed area. Later, the swab was conditioned in a tube with 3 mL of sterile 0.9% saline solution, which was placed under refrigeration and immediately transferred to microbiologic analysis.

The microbiologic analyses were made in the Laboratory of Microbiology of the Botucatu Institute of Biosciences (São Paulo State University – Unesp). In this study, the most prevalent biofilm-forming bacteria in the VU mentioned in the literature – *S. aureus* and *P. aeruginosa* – were selected to be analyzed. The *Staphylococcus epidermidis* was also assessed for being a bacterium that forms biofilm.[11] The other bacteria in the cultures were only described as present and their load. Still, they were not evaluated regarding the ability to form biofilm and the bacterial identity between T0 and T30. To calculate the number of colony-forming units per square centimeter (CFU/cm^2), the number of confirmed colonies was multiplied by 10 (100 μL inoculum) and then by 3 (total of 3 mL in the swab tube).

Biofilm production on polystyrene microplate

For each culture of *S. aureus*, *S. epidermidis*, and *P. aeruginosa*, growth in BHI under 35 °C/24 hours was diluted to approximately 1.5×10^8 CFU (0.5 MacFarland scale), with the support of Densicheck (Biomeriéux For), using the BHI supplementing with 0.5% of glucose. The Optical Density (OD) was measured using an ELISA reader (Babsystems, MultiSkan EX) at 570 nm. BHBI not inoculated was used as a negative control of the reactions. The positive control of *P. aeruginosa* was the ATCC 9027 and the Staphylococcus was *S. epidermidis* ATVV 35983. From the average of the four repetitions (OD) and according to the relation between the OD (test sample) and the OD (negative control), the strains were classified into the following categories: no biofilm producers, weak, moderate, or strong biofilm producers, as mentioned by Stepanovic et al.[12]

Identification of the bacterial typing by Pulsed Field Gel de Eletroforese (PFGE)

The molecular typing using the PFGE technique was performed for the *S. aureus and P. aeruginosa bacteria* when the same species were found in one ulcer on T0 and T30. For the

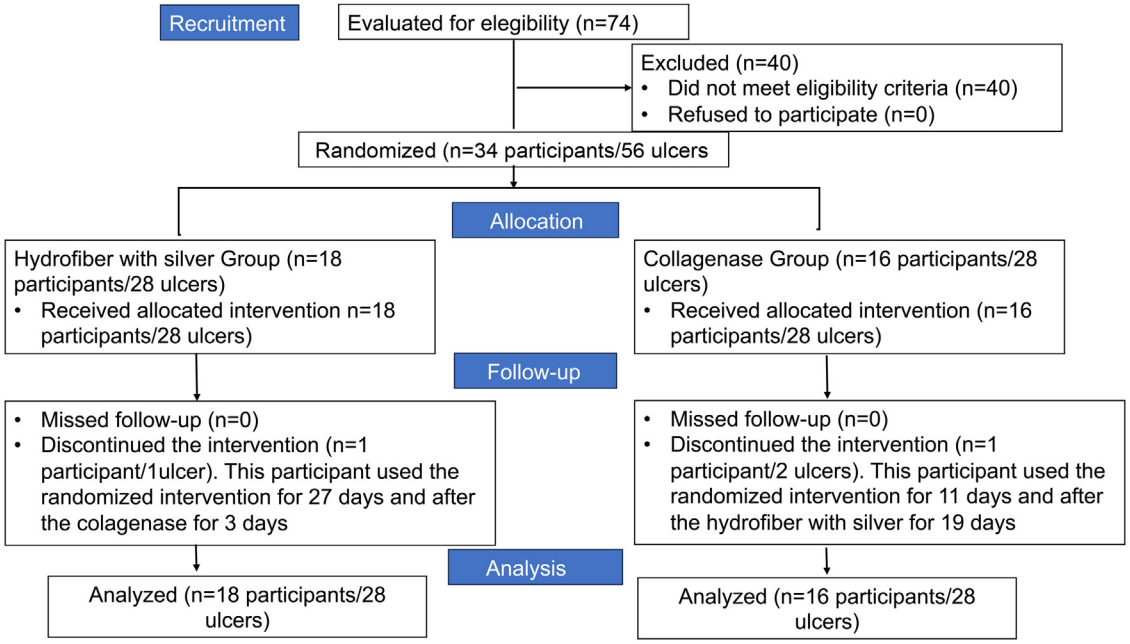

Fig. 1 Flowchart of the study according to CONSORT.

strains of *S. aureus*, the methodology used was described for PulseNet.[13] For the strains of *P. aeruginosa*, the methodology of Gram-negative of Selim et al.[14] was employed.

Sample size and statistical analysis

For the sample size, the authors assumed that 20% of VU would remain with superficial infection in the HAg group and 60% in the Col group. The difference between the groups was based on previous studies that found almost 80% of superficial infection was controlled with HAg dressing[15,16] In the Col group, the authors assumed only 40% control of the infection since its action is enzymatic debridement.[7] Considering 80% of statistical power and a two-tailed significance level of 95%, 27 VU by each intervention group was necessary.

The statistical analysis was by intention to treat. It was executed respecting the assumptions determined by the variables' results, characteristics, and behavior. The binomial variables were compared by Chi-Square (c^2) and Fisher's Exact tests. The Student's *t*-test or Mann-Whitney *U* test compared the numerical variables. The normality was assessed by the Shapiro-Wilk test. The Longitudinal follow-up of ulcer areas, the PUSH score, was reached between the groups by a generalized linear mixed model with an adequate probability distribution for each variable. The magnitude of the effect on nominal data was assessed by the Relative Risk (RR) and its Confidence Interval of 95% (95% CI).[17] Data were analyzed using the software SPSS 22.0 and considered a significant value of $p < 0.05$.

Results

During the study period, 74 participants were evaluated to determine if they met the eligibility criteria (Fig. 1). Among them, 40 were excluded for not meeting the eligibility criteria. Thus, 34 participants with 56 venous ulcers were eligible and randomized for the study. Eighteen participants with 28 VU were randomized for the HAg group and 16 participants with 28 VU for the Col group. After 30 days of follow-up, one participant from the HAg group with one ulcer and one from the Col group discontinued the interventions.

Table 1 presents the demographic and clinical data from the participants in the basal time (T0), distributed by group of study. It is observed that the study groups are homogenous and not statistically different among the variables.

Primary outcomes

Rate of ulcer without clinical signs of superficial infection at T30

There was a reduction of ulcers with criteria of superficial infection in both groups over time. In 29/56 ulcers (51.8%; 95% CI 39.0%–64.3%), there were no signs of superficial infection at T30, 13/28 from HAg group (46.4%; 95% CI 28.6%–65.4%) and 16/28 from Col group (67.1%; 95% CI 40.0%–73.4%), not having statistic difference between the groups ($p = 0.422$). The RR for non-superficial infection at the end of 30 days among the HAg group compared to the Col group was 0.81 (95% CI 0.39–1.68).

Rate of ulcers with bacterial load reduction

It was possible to identify that no decrease of the bacterial load over time occurred ($p = 0.054$) nor did it happen between the groups ($p = 0.113$) (Figs. 2 A, B, and C).

At T0, 37/56 of ulcers had growth of *S. aureus* (66.1%, 95% CI 53%–77.1%); in the HAg group occurred in 16/28 (57.1%; 95% CI 39.1–73.5%) and the Col group in 21/28 ulcers (75%; 95% CI 56.6%–87.3%). At T30, 46/56 had growth of *S. aureus* (82.1%; 95% CI 70.1%–90%), in the HAg group

Table 1 Distribution of the 34 participants (56 ulcers) by study group according to demographic and clinical data on basal Time (T0).

Variables related to patients	Group		Total, n = 34 (%)	p-value
	Col, n = 16 (%)	HAg, n = 18 (%)		
Average age (in years) (±SD)	70.7 (±9.2)	68.6 (±8.9)	69.6 (±9.0)	0.94
Women	11 (68.8)	13 (72.2)	24 (70.6)	0.83
Men	5 (31.3)	5 (27.8)	10 (29.4)	0.83
SAH	11 (68.8)	14 (77.8)	25 (73.5)	0.58
DM	5 (31.3)	6 (33.3)	11 (32.3)	0.90
Vascular surgical procedure history	6 (37.5)	4 (22.2)	10 (24.49)	0.36
Reduced ankle mobility	9 (56.2)	10 (55.5)	19 (55.8)	0.97
History of DVT	5 (31.3)	3 (16.7)	8 (23.5)	0.35
ABI - median (max–min)	1.07 (0.80–1.50)	1.05 (0.93–1.21)	1.06 (0.80–1.50)	0.25
Variables related to the wounds Median (min–max)	n = 28 ulcers	n = 28 ulcers	Total (n = 56 ulcers)	p-value
Ulcers' time (months)	24.0 (1.0–168.0)	42.0 (2.0–600.0)	30 (1.0–600.0)	0.25
Ulcer's area (cm^2)	10.3 (1.0–96.9)	14.3 (1.0–123.3)	11.2 (1.0–123.3)	0.74

SHA, Systemic Arterial Hypertension; DM, Diabetes Mellitus; DVT, Deep Venous Thrombosis; ABI, Ankle Brachial Index.

occurred in 20/28 ulcers (71.4%; 95% CI 52.4%–84.75%) and the Col group in 26/28 ulcers (92.8%; 95% CI 77.5%–98.0%). There was no difference with statistical significance over time (p = 0.345) and according to the intervention groups (p = 0.336).

As for *P. aeruginosa*, on T0, there was a growth in 16/56 ulcers (28.5%; 95% CI 18.4%–41.5%); in the HAg group, it occurred in 11/28 (39.3%; 95% CI 23.6%–57.6%) and the Col group occurred in 5/28 (17.8%; 95% CI 7.9%–35.6%). At T30, 13/56 ulcers had growth of *P. aeruginosa* (23.2%; 95% CI 14.1%–35.8%), in the HAg group occurred in 7/28 ulcers (25%; 95% CI 12.7%–43.3%) and the Col group in 6/28 ulcers (21.4%, 95% CI 10.2%–39.5%). The *S. epidermidis* only occurred in three ulcers on T0.

Rate of ulcers with biofilm-forming bacteria

There was a reduction in the rate of ulcers with biofilm-forming bacteria from T0 to T30 (p = 0.047), but there was no statistically significant difference between the groups at T30 (p = 0.558).

At T30, in the HAg group, 13/28 (46.4%; 95% CI 28%–63%) did not present bacteria that form biofilm; in the Col group also 13/28 (46.4%; 95% CI 28%–63%). Thus, the RR of ulcers with bacteria that do not form biofilm was 1.0 (95% CI 0.46–2.16; p = 1.000). The results of the biofilm production by a strain of bacteria are shown in Fig. 3.

Rate of ulcers with change in the bacterial identity

The molecular typing using the PFGE technique was performed for the bacteria (*S. aureus* and *P. aeruginosa*) from the same species in a specific ulcer on T0 and T30. However, typing was not performed for S epidermidis since there was no growth of this bacterium on T0 and T30 in the same ulcer.

Fig. 4 shows the results of the dendrogram of genetic similarity of *S. aureus* of ulcers that had growth of this bacterium on T0 and T30. It was possible to identify the existence of 17 total clones of bacteria in 22 participants at different moments and groups of this study. In that regard, there was a significant similarity, over 80%, in most ulcers, so the identical clones were identified on T0 and at T30. The clones of *S. aureus* identified on T0 were the same identified at T30 in 13/14 ulcers (92.8%; 95% CI 68.5%–98.7%) in the HAg group and in 17/20 ulcers (85%; 95% CI 64.0%–94.8%) in the Col group. The RR to have *S. aureus* with a change in the identity is 0.58 (95% CI 0.10–3.31; p = 0.553); therefore, there is no difference with statistical significance between the groups.

The PFGE analyses on strains of *P. aeruginosa* are observed in the dendrogram of Fig. 5. This dendrogram was created using one final partition of 8 groupings with a level of similarity of over 80%. All wounds of the dendrogram identified a high similarity of the clones on T0 and at T30. It was possible to identify eight clones in 7 participants with 11 ulcers. Of these eleven ulcers, 9/28 were from the HAg group (32.1%) and 2/28 (7.14%) from the Col group. There was no change in the identity of *P. aeruginosa* in any ulcer in both groups.

Secondary outcomes

Clinical improvement of VU

In the HAg group, the average PUSH value on T0 was 13.5 (±2.5), at T30, it was 12.7 (±3.3). In the Col group, the average value on T0 was 13.5 (±2.5), and at T30, it was 12.4(±2.9). Both groups showed improvement in the score over time (p = 0.001); however, there was no statistically significant difference between the groups (p = 0.0668). The average percentile score reductions of PUSH in the HAg group was -6.8 (95% CI −1.3 to −13.0); in the Col group, it was −7.6 (95% CI −1.10 to −14.1), confirming that there was no difference between the groups.

Reduction of ulcer area and total healing

The average reduction in ulcer area was 0.78 cm^2 (95% CI -0.20 to -1.36) in the HAg group, and 1.1 cm^2 (95% CI −0.20 to −2.00) in the Col group. There was a reduction in the

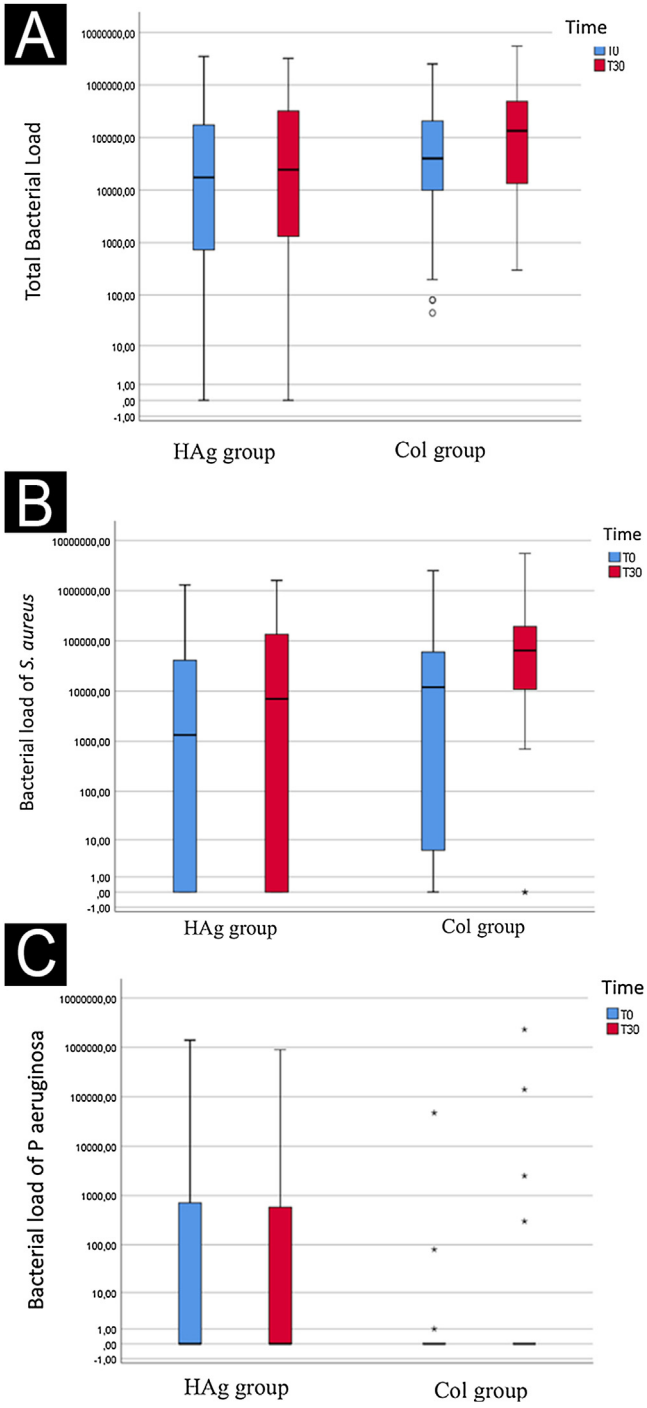

Fig. 2 Log of the bacterial load (CFU/cm^2) of the total evaluated species (A), *S aureus* (B), and *P. aeruginosa* (C) at baseline (T0) and after 30-days (T30), in the ulcers of the Hydrofiber with silver (HAg) and Collagenase (Col) group. The bacterial load over time (mean before vs. mean after) had a marginal significance (p = 0.054); however, it did not differ between the groups (p = 0.113).

area for both groups over time (p = 0.001) but no difference in statistical significance between the groups (p = 0.786). There were no ulcers with total healing in both analyzed groups.

Adverse events

There were no adverse events related to both interventions. One patient with four ulcers in the Col group had secondary myiasis, but this event was unrelated to the intervention.

Discussion

Evaluating interventions that act in the bacterial load and biofilms of VU is crucial, for there is a high prevalence of 62% to 89% of biofilms in chronic wounds.[18] This randomized clinical trial was specifically designed to evaluate, in a short period, the efficacy of the Hydrofiber dressing with silver on clinical outcomes such as local infection and microbiologic such as reduction of the bacterial load and inhibition of bacteria biofilm producers. It was assessed if the dressings could eliminate the bacteria that were initially colonizing the ulcer, using the bacterial clonality evaluation, comparing basal outcomes with the follow-up's final time.

The main results show that both interventions, Hydrofiber dressing with silver and collagenase ointment, have promoted the reduction of ulcers with criteria of superficial infection, a decrease in ulcer rate with biofilm-forming bacteria over time, but with no statistically significant difference between the groups. On the other hand, there was no reduction in total bacterial load over time, but there was a marginal significance (p = 0.054). So, the lack of detection of a difference may have been due to the small sample (underpowered). However, there was no suggestion of a difference between the groups.

Most of the ulcers presented indistinguishable PFGE profiles between T0 and T30, showing a lack of action to eliminate the bacteria that were initially colonizing the ulcer. The initial hypothesis presumed that the Hydrofiber dressing in silver would be superior to the Collagenase ointment since there is more evidence of its action against superficial infection and biofilms due to its antimicrobial properties.[15,16] Dressings containing silver are known for reducing the bacterial load and acting as an antimicrobial barrier to avoid higher contamination of the wound by external microorganisms. These dressings have a lower risk of bacterial resistance when there is an adequate dose of silver.[15] In addition, silver acts against Gram-negative bacteria, Gram-positive bacteria, fungi, and viruses,[19] even though there have been recent reports of bacterial resistance to silver.[20]

The clinical trials with dressings with silver generally evaluate outcomes of healing. However, the results related to the local control of the infection and microbiologic effects still need to be assessed, which hampers the present findings' comparison.

A Cochrane systematic review with meta-analyzes from 2010 concluded that there was no evidence to confirm if products with silver can promote wound healing.[21] However, other systematic revisions from recent years have found different results. A Cochrane systematic review in 2018 about dressings and topical agents for the treatment of VU found evidence that the dressings with silver can increase the probability of VU healing compared to non-adherent dressings (RR = 2.43; 95% CI 1.58 to 3.74) with evidence of moderate certainty.[22] The systematic review made in

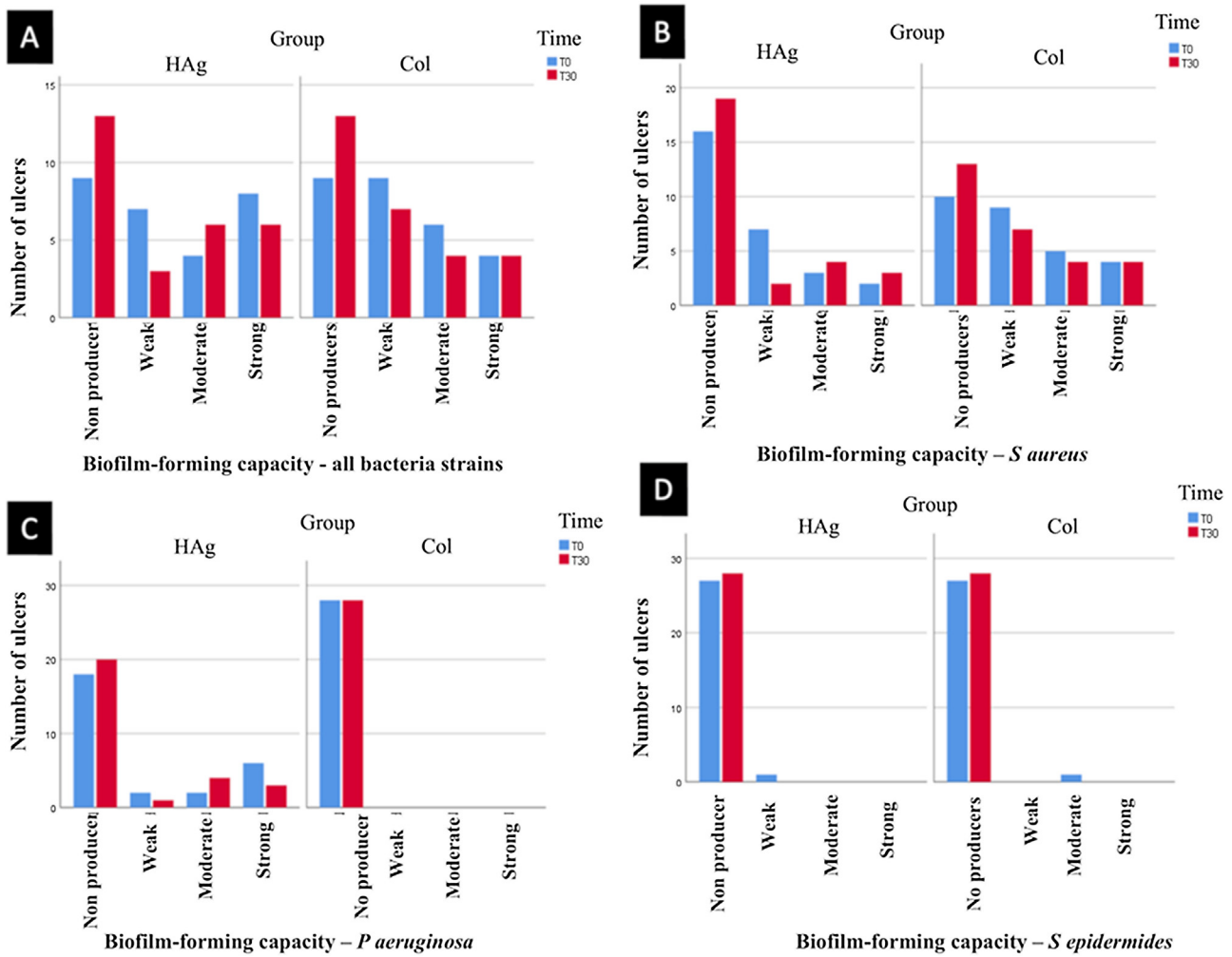

Fig. 3 Classification of bacteria strains that form biofilm. (A) Classification of all bacteria strains evaluated together (*S. aureus*, *P. aeruginosa*, and *S. epidermidis*). (B) The capacity of the *S aureus* to form biofilm. (C) The capacity of the bacteria *P. aeruginosa* to form biofilm. (D) The capacity of the bacteria *S epidermidis* to form biofilm. There was a reduction in the rate of ulcers with biofilm-forming bacteria from T0 to T30 (p = 0.047), but there was no statistically significant difference between the groups at T30 (p = 0.558).

2020 about dressings with silver, specifically for VU, included eight randomized clinical trials, totaling 1,057 patients, 526 participants with dressings with silver, and 531 controls. The evaluated outcomes were clinical, such as wound area reduction and healing. There was evidence that dressings with silver can increase the healing rate of VU and improve its recovery in a short period. However, compared to other dressings, clinical trials with a long time of follow-up are necessary to confirm if the dressings with silver are superior to the complete healing of the wound.[23]

In the present study, both groups were submitted to debridement by superficial surgical curettage before the randomization, which can explain the similar results between both groups. Debridement represents a treatment strategy against biofilms. Although, it cannot be eradicated because its formation occurs a few hours after the procedure. Thus, it is not recommended the isolated use. Still, it is a strategy that supports the best efficacy of topical therapies against biofilm performed after debridement, as it opens a window of opportunity.[24]

Biofilm and bacterial load of ulcers promote a delay in healing and can cause de development of infections.[25] Therefore, the knowledge of the most frequent microorganisms in chronic ulcers shows a way to create wound treatment strategies. The clinical-laboratory correlation regarding the bacterial flora of chronic ulcers is a challenge. The microbiologic sample can be analyzed in a qualitative and quantitative approach. In this study, the swab was performed in a predetermined area, making the quantitative analyses and identification of bacteria species possible. The swab technique is less invasive and can be used for qualitative, semi-quantitative, or quantitative analyses. It is mainly employed in outpatient settings.[26]

The swab technique is less invasive and can be used for qualitative, semi-quantitative, or quantitative analyses. It is predominantly employed in outpatient settings.

The most frequent bacteria in chronic ulcers are *S. aureus* and *P. aeruginosa*. At the same time, the prevalence of other types varies in the different studies.[27] The ulcer can evolve into an infection of deeper soft tissues

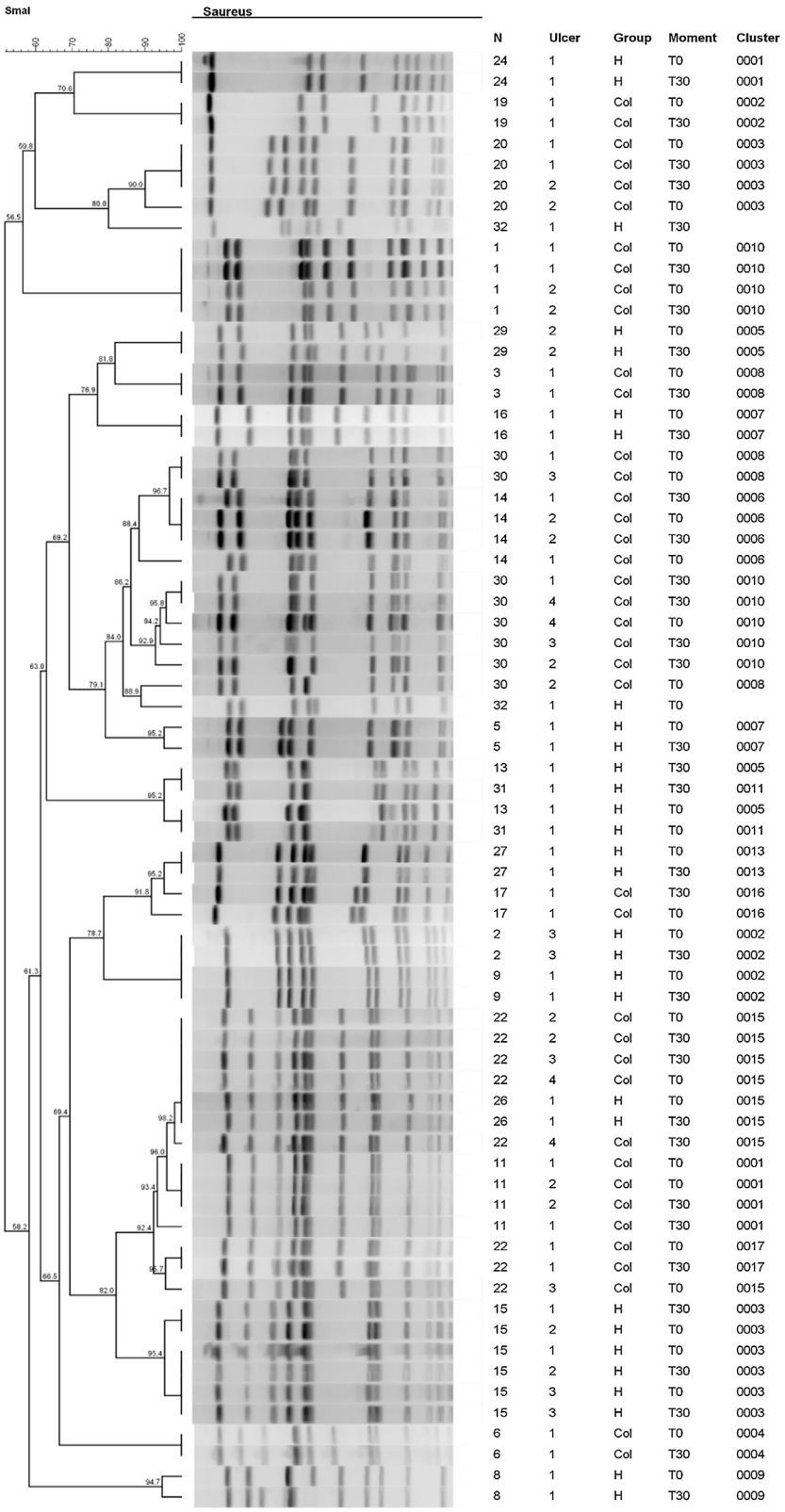

Fig. 4 Dendrogram of genetic similarity of ulcers with *S aureus*. The RR to have *S. aureus* with a change in the identity is 0.58 (95% CI 0.10–3.31; p = 0.553).



Fig. 5 Dendrogram of genetic similarity of ulcers with *P. aeruginosa*. There was no change in the identity of *P. aeruginosa* in any ulcer in both groups.

when the bacteria reach a critical level of 10^5 unities creators of colony per gram of tissue. When the number of bacteria increases over this level, the probability of infection increases as the host's immune system cannot control the bacteria's proliferation anymore.[28] The study that analyzed the microbiological characteristic of 754 VU, using the swab in a 1 cm^2 area, in a sample of 636 (84.3%) patients presented ulcers with positive for culture.[29] Among the pathogens identified in the study, *P. aeruginosa* was detected in 28.6% of cultures. In the present study, about 66% of the ulcers were colonized by *S. aureus* and 28.5% by *P. aeruginosa*.

The molecular typing, by the PFGE technique performed in this study, demonstrated the high similarity of clones on T0 and T30 in the strains of *S. aureus* and *P. aeruginosa*. Only one ulcer in the Hydrofiber dressing with a silver group and three from the Collagenase group presented different genetic profiles of *S. aureus*. PFGE profiles of *P. aeruginosa* were indistinguishable in any ulcers from both groups. Then, the present results show that the dressings are not efficacy in changing the bacterial clonality. Another study evaluated the colonization in wounds by *P. aeruginosa* via PFGE; it identified the bacteria in 48 isolated cultures of chronic ulcers that performed different types of dressings, including silver, demonstrating multi-resistance in three of them. *P. aeruginosa* was present in 75% of the samples of chronic wounds. In most ulcers, the strains showed the same genetic characteristics on both analyzed moments, indicating that the wound beds remained colonized and that the clones persisted for more than a month of treatment, a similar result found in this study. Most bacteria had virulence genes associated with the high potential to establish infection.[30]

The present study has some limitations. First, the follow-up time of 30-days is considered insufficient to evaluate the evolution of the healing process of chronic ulcers. However, the primary outcomes were associated with the assessment of the local superficial infection and microbiological outcomes, which could be achieved in the proposed period. Another limitation is the material collection procedure for the microbiological analyses, as the gold standard is tissue biopsy due to the capacity to evaluate the deeper bacteria. However, the biopsy has the disadvantage of being more invasive, painful, and expensive than the swab technique.[11] Also, the swab was collected in a small area of the wound bed. The distribution of bacteria and biofilms in chronic wounds may not be even. Therefore, one unique biopsy sample or swab in a small area can influence the results because other regions of the same injury can show different results. However, the swab was performed in the wound bed with traces of unviable tissue, increasing the chances of representing the site with the highest bacterial load and biofilm.

The results of this study allow for discussing the efficacy of interventions referred to as strategies for treating ulcers with superficial infection and biofilm, with clinical and microbiological evaluation of essential outcomes related to wound infections.

Conclusion

Both interventions improved the clinical and some microbiologic characteristics over time, but there was no difference between both interventions after 30-days of follow-up. In addition, most ulcers showed indistinguishable genetic profiles of *S. aureus* and *P. aeruginosa* between T0 and T30, with no difference between the groups.

Editor

Ana Maria Roselino.

Research data availability

The entire dataset supporting the results of this study was published in this article.

Authors' contributions

Taís Lopes Saranholi: Study design and planning; data collection, analysis, and interpretation of data; writing of the article; critical review of the literature; critical review of the manuscript; approval of the final version.

Natalie Carlos Ferreira Mello Sampaio: Data collection, analysis, and interpretation of data; writing of the article; critical review of the literature; critical review of the manuscript; approval of the final version.

Hélio Amante Miot: Analysis and interpretation of data; Statistical analysis; writing of the article; critical review of the manuscript; approval of the final version.

Stéfani Thais Alves Dantas: Data collection, analysis, and interpretation of data; writing of the article; critical review of the literature; critical review of the manuscript; approval of the final version.

Vera Lucia Mores Rall: Data collection, analysis, and interpretation of data; writing of the article; critical review of the literature; critical review of the manuscript; approval of the final version.

Luciana Patricia Fernandes Abbade: Study design and planning; data collection, analysis, and interpretation of data; writing of the article; critical review of the literature; critical review of the manuscript; approval of the final version.

Financial support

This study was financed by the Research Support Foundation of the State of São Paulo (FAPESP). Brazil. The funding agency had no role in the study design; in the collection, analysis, and interpretation of data; in the writing of the report; and in the decision to submit the article for publication.

Conflicts of interest

None declared.

References

1. Percival SL, Hill KE, Williams DW, Hooper SJ, Thomas DW, Costerton JW. A review of the scientific evidence for biofilms in wounds. Wound Repair Regen. 2012;20:647–57.
2. Percival SL, Emanuel C, Cutting KF, Williams DW. Microbiology of the skin and the role of biofilms in infection. Int Wound J. 2012;9:14–32.
3. Negut I, Grumezescu V, Grumezescu AM. Treatment strategies for infected wounds. Molecules. 2018;23:2392.
4. Goswami AG, Basu S, Banerjee T, Shukla VK. Biofilm and wound healing: from bench to bedside. Eur J Med Res. 2023;28:157.
5. Wolcott RD, Rumbaugh KP, James G, Schultz G, Phillips P, Yang Q, et al. Biofilm maturity studies indicate sharp debridement opens a time- dependent therapeutic window. J Wound Care. 2010;19:320–8.
6. Snyder RJ, Bohn G, Hanft J, Harkless L, Kim P, Lavery L, et al. Wound biofilm: current perspectives and strategies on biofilm disruption and treatments. Wounds. 2017;29:S1–17.
7. McCallon SK, Weir D, Lantis JC 2nd. Optimizing wound bed preparation with collagenase enzymatic debridement. J Am Coll Clin Wound Spec. 2015;6:14–23.
8. CONSORT GroupSchulz KF, Altman DG, Moher D. CONSORT 2010 statement: updated guidelines for reporting parallel group randomized trials. Ann Intern Med. 2010;152:726–32.
9. Sibbald RG, Woo K, Ayello EA. Increased bacterial burden and infection: the story of NERDS and STONES. Adv Skin Wound Care. 2006;19:447–61, quiz 461-463.
10. de Gouveia Santos VL, Sellmer D, Massulo MME. Inter rater reliability of Pressure Ulcer Scale for Healing (PUSH) in patients with chronic leg ulcers. Rev Lat Am Enfermagem. 2007;15:391–6.
11. Alves PJ, Barreto RT, Barrois BM, Gryson LG, Meaume S, Monstrey SJ. Update on the role of antiseptics in the management of chronic wounds with critical colonisation and/or biofilm. Int Wound J. 2021;18:342–58.
12. Stepanović S, Ćirković I, Mijač V, Švabić-Vlahović M. Influence of the incubation temperature, atmosphere and dynamic conditions on biofilm formation by Salmonella spp. Food Microbiol. 2003;20:339–43.
13. Centers for Disease Control and Prevention - CDC [Internet]. Oxacillin Resistant Aureus on PulseNet (OPN): Laboratory Protocol for Molecular typing of S. Aureus by Pulsed Field Gel Electrophoresis (PFGE). Atlanta: CDC. c2022 [cited 2022 Jul 22]. Available from: https://www.cdc.gov/staphylococcus-aureus/media/pdfs/MRAS-PFGE-P.pdf.
14. Selim S, El Kholy I, Hagagy N, El Alfay S, Aziz MA. Rapid identification of *Pseudomonas aeruginosa* by pulsed-field gel electrophoresis. Biotechnol Biotechnol Equip. 2015;29:152–6.
15. Forlee M, Rossington A, Searle R. A prospective, open, multicentre study to evaluate a new gelling fibre dressing containing silver in the management of venous leg ulcers. Int Wound J. 2014;11:438–45.
16. Coutts P, Sibbald RG. The effect of a silver-containing Hydrofiber dressing on superficial wound bed and bacterial balance of chronic wounds. Int Wound J. 2005;2:348–56.
17. Patino CM, Ferreira JC. Confidence intervals: a useful statistical tool to estimate effect sizes in the real world. J Bras Pneumol. 2015;41:565–6.
18. Malone M, Bjarnsholt T, McBain AJ, James GA, Stoodley P, Leaper D, et al. The prevalence of biofilms in chronic wounds: a systematic review and meta-analysis of published data. J Wound Care. 2017;26:20–5.
19. Vila Domínguez A, Ayerbe Algaba R, Miró Canturri A, Rodríguez Villodres Á, Smani Y. Antibacterial activity of colloidal silver against gram-negative and gram-positive bacteria. Antibiot (Basel). 2020;9:36.

20. Panáček A, Kvítek L, Smékalová M, Večeřová R, Kolář M, Röderová M, et al. Bacterial resistance to silver nanoparticles and how to overcome it. Nat Nanotechnol. 2018;13:65–71.
21. Storm-Versloot MN, Vos CG, Ubbink DT, Vermeulen H. Topical silver for preventing wound infection. Cochrane database Syst Rev. 2010:CD006478.
22. Norman G, Westby MJ, Rithalia AD, Stubbs N, Soares MO, Dumville JC. Dressings and topical agents for treating venous leg ulcers. Cochrane database Syst Rev. 2018;6:CD012583.
23. Zhao M, Zhang D, Tan L, Huang H. Silver dressings for the healing of venous leg ulcer: a meta-analysis and systematic review. Medicine (Baltimore). 2020;99:e22164.
24. Schultz G, Bjarnsholt T, James GA, Leaper DJ, McBain AJ, Malone M, et al. Consensus guidelines for the identification and treatment of biofilms in chronic nonhealing wounds. Wound Repair Regen. 2017;25:744–57.
25. Metcalf DG, Bowler PG. Biofilm delays wound healing: a review of the evidence. Burn Trauma. 2013;1:5–12.
26. Ramsay S, Cowan L, Davidson JM, Nanney L, Schultz G. Wound samples: moving towards a standardized method of collection and analysis. Int Wound J. 2016;13:880–91.
27. Serra R, Grande R, Butrico L, Rossi A, Settimio UF, Caroleo B, et al. Chronic wound infections: the role of *Pseudomonas aeruginosa* and *Staphylococcus aureus*. Expert Rev Anti Infect Ther. 2015;13:605–13.
28. Percival SL. Importance of biofilm formation in surgical infection. Br J Surg. 2017;104:e85–94.
29. Cwajda-Białasik J, Mościcka P, Jawień A, Szewczyk MT. Microbiological status of venous leg ulcers and its predictors: a single-center cross-sectional study. Int J Environ Res Public Health. 2021;18:12965.
30. de Oliveira FP, Pires BMFB, de Cássia Ferreira de Almeida Silva K, de Carvalho BTF, Teixeira LA, de Paula GR, et al. Prevalence, Antimicrobial Susceptibility, and Clonal Diversity of *Pseudomonas aeruginosa* in Chronic Wounds. J Wound Ostomy Continence Nurs. 2017;44:528–35.

SOCIEDADE BRASILEIRA DE DERMATOLOGIA

Anais Brasileiros de Dermatologia

www.anaisdedermatologia.org.br

ORIGINAL ARTICLE

Arsenic exposure and risk of skin cancer (melanoma and non-melanoma): a systematic review and meta-analysis☆

Lijiao He, Meiying Wei, Qikui Yang, Yun Huang, Zuyuan Wei *

Department of Dermatology, Wenshan Zhuang and Miao Autonomous Prefecture Hospital of Traditional Chinese Medicine, Wenshan, China

Received 9 July 2024; accepted 24 November 2024
Available online 17 July 2025

KEYWORDS
Arsenic;
Basal cell carcinoma;
Melanoma;
Meta-analysis;
Squamous cell carcinoma;
Systematic review

Abstract

Background: Arsenic, recognized as a potentially lethal substance and a carcinogen, has been associated with an increased risk of skin cancer; however, the findings have been inconsistent. The aim of this study was to assess the impact of arsenic exposure on skin cancer risk (including melanoma and non-melanoma) through a meta-analysis of the available data.

Objectives: To assess the risk of skin cancer from arsenic exposure.

Methods: Searches were performed in databases such as PubMed, Web of Science, Embase, and CNKI (as of June 10, 2024). The pooled odds ratio (OR) and its 95% Confidence Interval (95% CI) were calculated using a random effects model. Subgroup analyses were performed considering sample size, study centers, U.S. regions, arsenic exposure routes, and measurement methods.

Results: A total of 12 papers were included, comprising 48,003 participants. The findings indicated an association between arsenic exposure and the risk of skin cancer ([OR = 1.51], 95% CI 1.26–1.80). Specifically, the OR was 1.52 (95% CI 1.06–2.17) for melanoma, 1.64 (95% CI 1.16–2.32) for squamous cell carcinoma, and 1.36 (95% CI 1.04–1.77) for basal cell carcinoma. Subgroup analyses also revealed an association between arsenic exposure and skin cancer in the United States (OR = 1.52, 95% CI 1.25–1.87). Both ingestion and inhalation pathways of arsenic exposure showed a trend toward an increased risk of skin cancer.

Study limitations: An important limitation of this study is a degree of heterogeneity, and another is due to the limited number of research papers available.

Conclusion: This meta-analysis indicates that arsenic exposure may be associated with an elevated risk of skin cancer. Additional prospective research is necessary to verify the association between arsenic exposure and the incidence of skin cancer, encompassing both cutaneous malignant melanoma and non-melanoma skin cancer.

☆ Study conducted at the Department of Dermatology, Wenshan Zhuang and Miao Autonomous Prefecture Hospital of Traditional Chinese Medicine, Wenshan, China.

* Corresponding author.
E-mail: 2632645497@qq.com (Z. Wei).

https://doi.org/10.1016/j.abd.2025.501161

Introduction

Skin cancers can be categorized into two main groups: cutaneous malignant melanoma and non-melanoma skin cancer (NMSC). NMSC, predominantly formed of squamous cell carcinoma (SCC) and basal cell carcinoma (BCC), is the most commonly identified cancer, making up approximately one-third of all malignant tumors diagnosed globally each year.[1,2] BCC represents almost 80% of all NMSC cases detected each year,[3] with SCC making up the remaining 20%.[4,5] Melanoma, an aggressive type of skin cancer arising from melanocytes, accounts for under 5% of all skin cancer cases but poses a substantial threat. If left untreated, melanoma, responsible for 75% of all deaths related to skin cancer, has the ability to metastasize to different areas of the body.[6,7] Collectively, melanoma and NMSC impose a substantial economic and health burden, which is anticipated to keep increasing in the future.

Arsenic has been used as a medicine (Fowler's solution) for the treatment of syphilis, malaria and psoriasis for the past two centuries.[8] However, after 30-years of treatment, patients developed multiple skin cancers.[9] Subsequent research has progressively demonstrated that long-term chronic exposure to arsenic can result in a range of cancers, including skin, lung,[10,11] and, to a lesser extent, liver, kidney, and bladder cancers.[12–14] Consequently, many arsenic-containing drugs have been restricted or phased out entirely. The International Agency for Research on Cancer (IARC) classifies arsenic as a Group I human carcinogen.[15] Nonetheless, Arsenic is commonly found in soils, sediments, and groundwater, either occurring naturally or as a result of human activities such as food preparation, industrial processes, mining and pesticide use. Humans can be exposed to arsenic through various pathways.[16] According to recommendations from the World Health Organization (WHO), the level of arsenic in drinking water should not exceed 10 μg/L.[17] However, this guideline is often increased to 50 μg/L in numerous developing nations.[18] Globally, more than 100 million individuals are at risk of consuming arsenic levels over 50 μg/L in their drinking water.[19] Average dietary exposure to inorganic Arsenic (iAs) ranges from 0.1 to 3.0 μg/kg per day in Europe, Asia, and the United States.[20] The National Research Council (NRC) Risk Assessment from 2001 suggests that even exposure to lower concentrations of arsenic poses a relatively high risk of cancer.[21]

Extensive research has been conducted on the association between exposure to arsenic and NMSC.[22–28] Multiple epidemiological investigations have established a association between exposure to arsenic and a heightened likelihood of developing NMSC in different locations such as Taiwan, Mexico, Bangladesh, and Chile.[29–31] Research in Taiwan[31,32] revealed a significant dose-response relationship for this association, while other studies did not observe such an effect.[23,25,26,28] Conversely, research on the potential association between melanoma and exposure to arsenic has yielded divergent findings.[22,33–38] While some studies indicate a possible association between arsenic exposure and a heightened likelihood of developing skin cancer, the definitive nature of this link is still debated. To investigate this potential association more thoroughly, a meta-analysis was carried out to systematically review existing data concerning arsenic exposure and its association to skin cancer, encompassing both melanoma and non-melanoma cases.

Methods

Protocol

The meta-analysis was registered with PROSPERO (CRD42024556618) and adhered to the PRISMA guidelines for thorough reporting.[39] Supplementary Appendix 1 contains the PRISMA checklist. Approval from the institutional review board was not necessary for this study, as it consisted of a systematic review and meta-analysis of existing literature.

Literature search strategy

Two researchers, Li Jiao He and Mei Ying Wei, individually searched PubMed, Embase, Web of Science, Cochrane Library, and CNKI (as of June 10, 2024). Key terms such as arsenic, basal cell carcinoma, squamous cell carcinoma, and melanoma were employed. Search expansion was conducted using mesh terms in PubMed, such as Malignant Melanoma, Arsenic-75, Epidermoid Carcinoma, and Rodent Ulcer. No limitations were placed on language or time in the search strategy. Each author conducted an independent review of all titles and chose relevant abstracts, while duplicates and unrelated articles were excluded. Final decisions on study inclusion or exclusion were made by consensus. The analysis included studies that examined the association between exposure to arsenic and skin cancer, encompassing both melanoma and non-melanoma (Specific search strategies are supplemented in Supplementary Appendix 2).

Inclusion and exclusion criteria

The criteria for including studies were defined as: 1) Case-control or prospective cohort research designs; 2) Studies involving populations with melanoma, BCC, SCC, or corresponding control groups; 3) Documentation of arsenic exposure history; 4) Availability of 95% Confidence Intervals (95% CIs) or sufficient data to calculate Odds Ratios (ORs) or Relative Risks (RRs) for the study outcomes.

The exclusion criteria for this study included: 1) Insufficient data or results; 2) Non-comparative studies, in vitro experiments, animal experiments, case reports, path mechanisms, conference abstracts, letters, reviews, and expert opinions; and 3) Individuals who were not diagnosed with skin cancer.

Data extraction

Two researchers independently reviewed the literature based on inclusion and exclusion criteria and collected data with a standardized form for information extraction. The data retrieved was verified by both researchers, and inconsistencies were addressed by a third-party specialist. Each study provided the following details: 1) Study details, including study design, country, the follow-up duration, study population (number of cases and controls or cohort mem-

bers), and demographic characteristics. 2) Type of arsenic exposure (e.g., water, dust, biological samples, questionnaires). 3) Definitions of outcomes, such as melanoma, BCC, and SCC (including histological diagnosis and ICD codes). 4) Reported effect measures, including odds ratios, relative risks, and corresponding 95% Confidence Intervals for exposed and unexposed groups.

Quality assessment and risk of bias

The quality of these studies was thoroughly evaluated by two reviewers utilizing the Newcastle-Ottawa Scale (NOS).[40] This assessment focused on three primary criteria: study selection, comparability of exposures, and evaluation of outcomes. The revised NOS utilizes a 9-star rating system: research is evaluated with 1–3 stars for poor quality, 4–6 stars for medium quality, and 7–9 stars for excellent quality. Two independent reviewers utilized the Cochrane Non-Randomized Study Intervention (ROBINS-I) tool to evaluate the risk of bias in the selected studies.[41] During the assessment process, the authors classified the risk of bias into five levels: low, moderate, serious, critical, or insufficient information, based on seven domains: 1) Bias due to Cofounding; 2) Bias in deviation from intended outcomes; 3) Bias in classification of interventions; 4) Bias due to deviation from intended intervention; 5) Bias due to missing data; 6) Bias in measurement of outcomes; 7) Bias in selection of the reported results. If at least one domain was rated as high or moderate, the overall risk of bias was classified as high or moderate; otherwise, it was classified as low. Any disagreements between the two investigators were resolved unanimously through consensus.

Statistical analysis

Stata SE 15.0 software was utilized to conduct statistical analysis for the computation of Odds Ratio (OR) and the corresponding 95% Confidence Intervals (95% CI) pertaining to binary variables. The choice between fixed-effects and random-effects models was based on the I^2 index and Cochran *Q* test p-values.[42] Heterogeneity was categorized as low ($I^2 < 25\%$), moderate (25 %–75 %), or high ($I^2 > 75\%$).[43] Significant heterogeneity was determined by a Cochran *Q* test p-value < 0.05. A subgroup analysis was carried out to examine the origins of variability, and a sensitivity analysis was done by removing individual studies to gauge the stability of the outcomes. The assessment of publication bias was done by visually inspecting the asymmetry of the funnel plot and using the Begg test.[44] All statistical tests were conducted as two-sided tests, with a significance level set at $p < 0.05$.

Results

Results of the literature search

Initially, a total of 2937 articles were retrieved through the literature search. Following the exclusion of 718 duplicate entries, an additional 2106 articles were removed according to the predefined criteria. Initially, 68 studies underwent title and abstract review. Upon full-text assessment, 56 studies did not meet the inclusion criteria and were subsequently excluded. After thorough examination, 12 research studies met the established criteria and were included in the meta-analysis. The specifics of the screening process for literature and its results are elucidated in Fig. 1.

Basic characteristics of the included studies

The analysis encompassed 12 studies, consisting of 11 case-control studies and 1 cohort study. Detailed demographic information of the population, such as sex ratio and country of origin, is presented in Table 1. The definitions of arsenic exposure differed across studies, with some emphasizing exposure through drinking water and others highlighting chemical contamination or indirect indicators like toenail and urine arsenic concentrations. These definitions exhibited minor discrepancies among the studies.

Quality assessment and risk of bias

The Newcastle-Ottawa Scale (NOS) was utilized to assess the quality of the cohort studies included, with the results presented in Table 2. In summary, five articles were rated as high quality, each receiving a score of 7-stars. Among these, two studies focused on the analysis of arsenic levels in urine, two others measured arsenic levels in toenails, and only one investigated arsenic levels in drinking water. These analyses accounted for variables such as age, sex, sun exposure history, and skin type to mitigate potential residual confounding effects. Additionally, a total of seven studies examined the association between occupational arsenic exposure and skin cancer, with five rated as moderate quality (6-stars). These studies employed a semi-quantitative three-stage scale (low, medium, and high) to evaluate occupational arsenic exposure based on intensity, frequency, and probability. Furthermore, the findings adjusted for key confounding factors, including age, sex, skin type, history of solar radiation exposure, family history of cancer, smoking history, and education level. The remaining two studies were rated as relatively low quality (5-stars) due to their reliance solely on data gathered from questionnaires administered by specially trained staff.

Most studies present a low to moderate risk of bias, mainly due to confounding bias (age, sex, history of solar radiation, skin type), selection bias (high exposure areas), and intervention bias (misclassification of exposure), even though adjustments are made, this concern is particularly salient in observational studies. Two other studies were at serious risk of bias due to bias in the selection of the reported result (see Table S1 in Supplementary Appendix 3).

Meta-analysis results

Preliminary analyses

Fig. 2 illustrates the association between exposure to arsenic and the various types of skin cancer, including melanoma, BCC, and SCC, through a forest plot. The analysis was based on 12 studies involving 48,003 participants, with

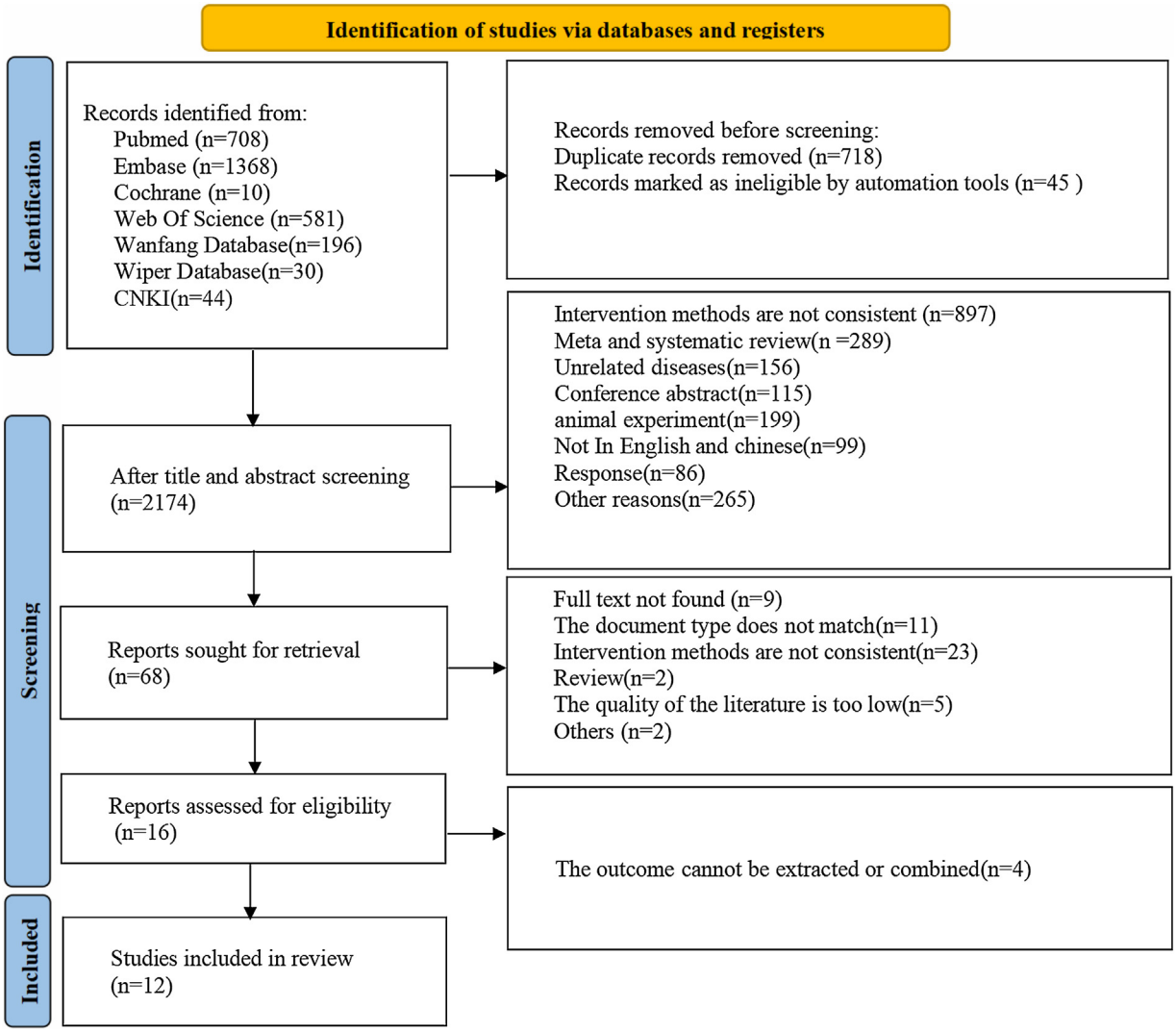

Fig. 1 Flowchart of study retrieval for this meta-analysis.

an overall OR = 1.51, 95% CI (1.26–1.80). A meta-analysis was conducted using a random effect model (I^2 = 42.6%). Specifically, arsenic exposure was associated with melanoma (OR = 1.52, 95% CI 1.06–2.17), SCC (OR = 1.64, 95% CI 1.16–2.32), and BCC (OR = 1.36, 95% CI 1.04–1.77). These results collectively imply that arsenic exposure heightens the risk of these skin cancers. To explore potential sources of variation, additional sensitivity analyses were conducted in light of the observed heterogeneity.

Sensitivity analyses

A sensitivity analysis was conducted on the studies that were included, as illustrated in Fig. 3. Every individual study was methodically removed from the meta-analysis to assess its influence on the overall risk estimation. The results revealed that the remaining studies consistently converged around an overall OR of 1.51. No significant changes in outcomes driven by individual studies were noted throughout this process. The heterogeneity observed could be attributed to variations in arsenic exposure definitions among the included articles, as well as differences in exposure assessment methods such as water, dust, urine levels, and self-reported exposures. Some studies focused primarily on arsenic in drinking water, while others addressed occupational exposure, chemical contamination, or utilized indirect exposure indicators. Despite these discrepancies, the overall heterogeneity remained moderate, and the meta-analysis model utilized was considered robust and reliable.

Subgroup analyses

A comprehensive subgroup analysis was conducted across the included studies, considering factors such as sample size, study centers, US regions, arsenic exposure routes, and measurement methods. The analysis revealed a total of 43,469 participants from the U.S. regions, 44,703 participants involved in the measurement methods, and 48,003 participants considered in the analyses of sample size, research centers, and arsenic exposure pathways. The results are shown in Table 3. No significant sources of heterogeneity were identified in these analyses. Subgroup analysis

Table 1 Clinical and demographic characteristics of the included studies in the meta-analysis.

First author	Year	Research type	Author states	Sample (n)		Age (year)		Sex (Male/ Female)		Definitions of arsenic exposure	Follow-up (years)	Skin cancer type
				Skin cancer	Non-skin cancer	Skin cancer	Non-skin cancer	Skin cancer	Non-skin cancer			
Bedaiwi [33]	2022	Case-control study	USA	Melanoma (87)	Non-skin cancer (12615)	64.6	45.4	M: 51.7% / F: 44.7%	M: 50.0% / F: 50.0%	Urine As concentration (>50ug/L)	NA	Melanoma
Langston [34]	2022	Case-control study	USA	Melanoma (1096)	Non-skin cancer (1033)	20–39: 13% 40–49: 14% 50–59: 21% 60–69: 23% 70–79: 18% 80+: 11%	20–39: 17% 40–49: 15% 50–59: 25% 60–69: 26% 70–79: 13% 80+: 4%	M: 52% / F: 48%	M: 45% / F: 55%	Drinking water As (>10ug/L)	NA	Melanoma
Beane Freeman [35]	2004	Case-control study	USA	Melanoma (326)	Non-skin cancer (329)	40–49: 26% 50–59: 22.8% 60–69: 23.1% 70–79: 19.6% 80–89: 8.4%	40–49: 15.8% 50–59: 29.8% 60–69: 28.4% 70–79: 18.2% 80–89: 7.8%	M: 55.7% / F: 44.3%	M: 64.3% / F: 35.7%	Toenails As concentration (>0.084 ug/g)	NA	Melanoma
Collatuzzo [36]	2023	Case-control study	Italy	Melanoma (295)	Non-skin cancer (293)	<35: 14.8% 35–49: 27.6% 50–64: 3.2% ≥65: 24.3%	<35: 20% 35–49:25.2% 50–64: 31.2% ≥65: 23.6%	M: 47% / F: 53%	M: 47.2% / F: 52.8%	Occupational exposure to As (undefined)	NA	Melanoma
Dennis [37]	2010	Cohort study	USA	Melanoma (150)	Non-skin cancer (24554)	57	48	NA	NA	Arsenical pesticide exposure	10.3 years	Melanoma
Kennedy-1 [22]	2005	Case-control study	Netherlands	Melanoma (47)	Non-skin cancer (164)	NA	NA	NA	NA	Occupational exposure to As(undefined)	NA	Melanoma
Kennedy-2 [22]	2005	Case-control study	Netherlands	Basal cell carcinoma (249)	Non-skin cancer (164)	NA	NA	NA	NA	Occupational exposure to As (undefined)	NA	Basal cell carcinoma
Kennedy-3 [22]	2005	Case-control study	Netherlands	Squamous cell carcinoma (103)	Non-skin cancer (164)	NA	NA	NA	NA	Occupational exposure to As (undefined)	NA	Squamous cell carcinoma
Surdu-1 [23]	2013	Case-control study	USA	Basal cell carcinoma (500)	Non-skin cancer (515)	67	61	M: 44.8% / F: 55.2%	M: 51.6% / F: 48.4%	Occupational exposure to As (dust fumes)	NA	Basal cell carcinoma

Table 1 (*Continued*)

First author	Year	Research type	Author states	Sample (n)		Age (year)		Sex (Male/ Female)		Definitions of arsenic exposure	Follow-up (years)	Skin cancer type
				Skin cancer	Non-skin cancer	Skin cancer	Non-skin cancer	Skin cancer	Non-skin cancer			
Surdu-2 [23]	2013	Case-control study	USA	Squamous cell carcinoma (70)	Non-skin cancer (515)	71.5	61	M: 54.3% / F: 45.7%	M: 51.6% / F: 48.4%	Occupational exposure to As (dust fumes)	NA	Squamous cell carcinoma
Mitropoulos [24]	2004	Case-control study	USA	Squamous cell carcinoma (404)	Non-skin cancer (395)	NA	NA	NA	NA	Occupational exposure to As (undefined)	NA	Squamous cell carcinoma
Sánchez [25]	2013	Case-control study	Colombia	Squamous cell carcinoma (166)	Non-skin cancer (166)	70.8	71.8	M: 31% / F: 69%	M:31% / F: 69%	Occupational exposure to As (carpentry trade wood, gunpowder, metal industries)	NA	Squamous cell carcinoma
Suárez-1 [26]	2007	Case-control study	France	Basal cell carcinoma (1333)	Non-skin cancer (1507)	60.5	58.2	M: 63% / F: 37%	M: 62% / F: 38%	Occupational exposure to As (Agricultural works)	NA	Basal cell carcinoma
Suárez-2 [26]	2007	Case-control study	France	Squamous cell carcinoma (183)	Non-skin cancer (1507)	60.5	58.2	M: 63% / F: 37%	M: 62% / F: 38%	Occupational exposure to As (Agricultural works)	NA	Squamous cell carcinoma
Karagas-1 [27]	2001	Case-control study	USA	Basal cell carcinoma (587)	Non-skin cancer (524)	<40: 7.2% 40–49:17% 50–59:21% 60–69:34.9% ≥70:19.9%	<40: 5.3% 40–49:12.6% 50–59:19.7% 60-69:39.3% ≥70:23.1%	M: 57.6% / F: 42.2%	M: 60.1% / F: 39.9%	Toenails As concentration (0.345–0.81 ug/g)	NA	Basal cell carcinoma
Karagas-2 [27]	2001	Case-control study	USA	Squamous cell carcinoma (284)	Non-skin cancer (524)	<40: 1.1% 40–49:6 % 50–59: 16.6% 60–69: 40.9% ≥70: 35.6%	<40:5.3% 40–49: 12.6% 50–59: 19.7% 60–69: 39.3% ≥70: 23.1%	M: 64.1% / F: 35.9%	M: 60.1% / F: 39.9%	Toenails As concentration (0.345–0.81 ug/g)	NA	Squamous cell carcinoma
Gilbert-Diamond [28]	2013	Case-control study	USA	Squamous cell carcinoma (470)	Non-skin cancer (447)	<50:4% 50–59: 19.4% 60–69: 45.3% ≥70: 31.3%	<50: 7.6% 50–59: 18.6% 60–69: 45.4% ≥70: 28.4%	M: 60.4% / F: 39.6%	M: 57.7% / F: 42.3%	Urine As concentration >5.31 ug/L)	NA	Squamous cell carcinoma

M, Male; F, Female; USA, United States of America; non-skin cancer; healthy controls.

Table 2 NOS Quality Evaluation Form. The assessment system rates the selection of participants, group comparability, and results evaluation using a 9-star scale. Research is considered poor quality if it is rated 1–3 stars, moderate quality if it is rated 4–6 stars, and high quality if it is rated 7–9 stars.

Study	Selection				Comparability	Outcomes			Total
	1	2	3	4		1	2	3	
Ahmed Bedaiwi	⋆	⋆	⋆		⋆	⋆	⋆	⋆	7
Marvin E. Langston	⋆	⋆	⋆		⋆	⋆	⋆	⋆	7
Laura E. Beane Freeman	⋆	⋆	⋆		⋆	⋆	⋆	⋆	7
Giulia Collatuzzo	⋆	⋆	⋆		⋆		⋆	⋆	6
Leslie K. Dennis	⋆	⋆	⋆		⋆		⋆		5
Cornelis Kennedy	⋆	⋆	⋆		⋆		⋆	⋆	6
Simona Surdu	⋆	⋆	⋆		⋆		⋆	⋆	6
Panagiotis Mitropoulos	⋆	⋆	⋆		⋆		⋆	⋆	6
Guillermo Sánchez	⋆	⋆	⋆		⋆		⋆		5
Berta Suárez	⋆	⋆	⋆		⋆		⋆	⋆	6
Margaret R. Karagas	⋆	⋆	⋆		⋆	⋆	⋆	⋆	7
Diane Gilbert-Diamond	⋆	⋆	⋆		⋆	⋆	⋆	⋆	7

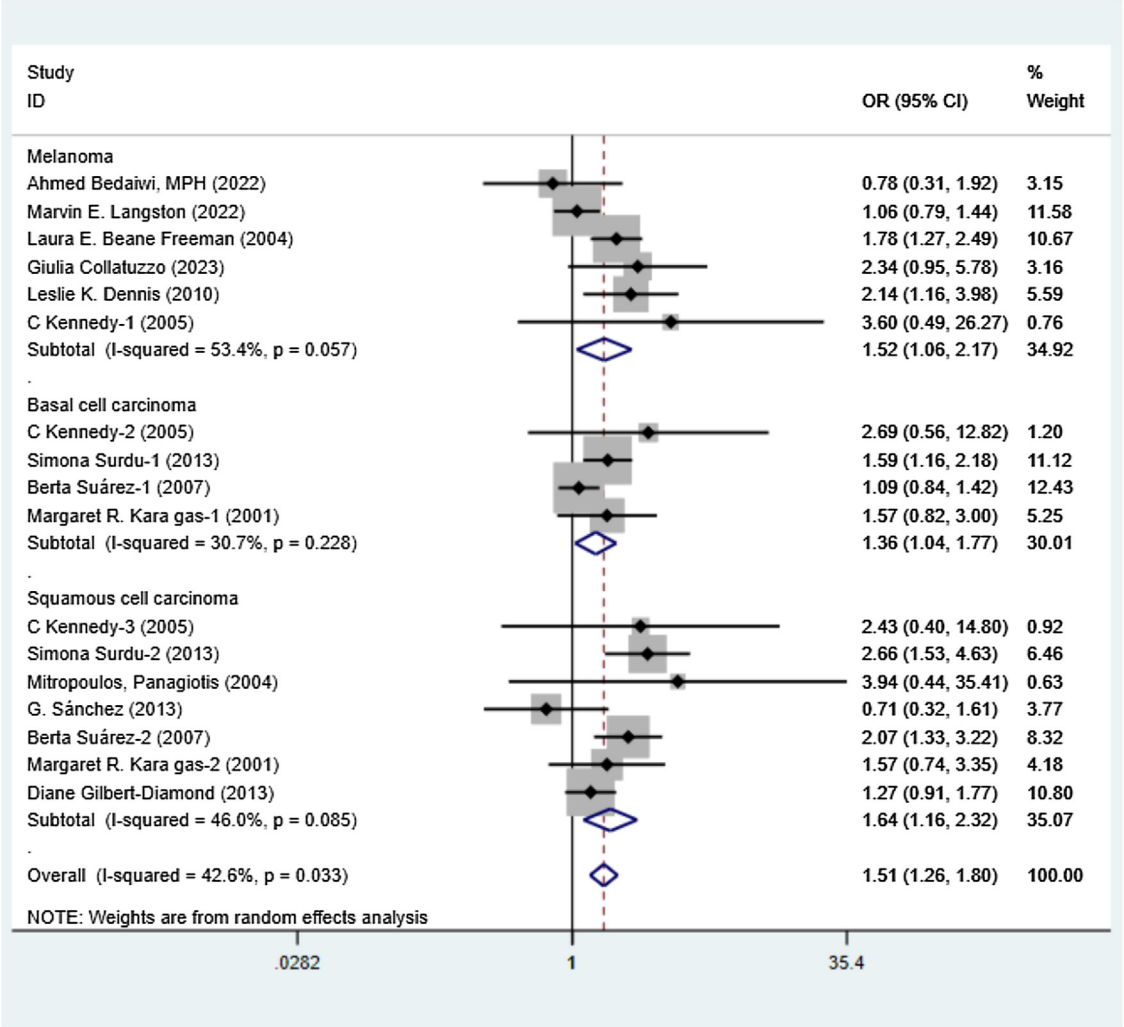

Fig. 2 Meta-analysis summarizing the data from various studies that investigate the association between arsenic exposure and the incidence of skin cancer. The weights come from the random-effects model. OR, Odds Ratio; CI, Confidence Interval.

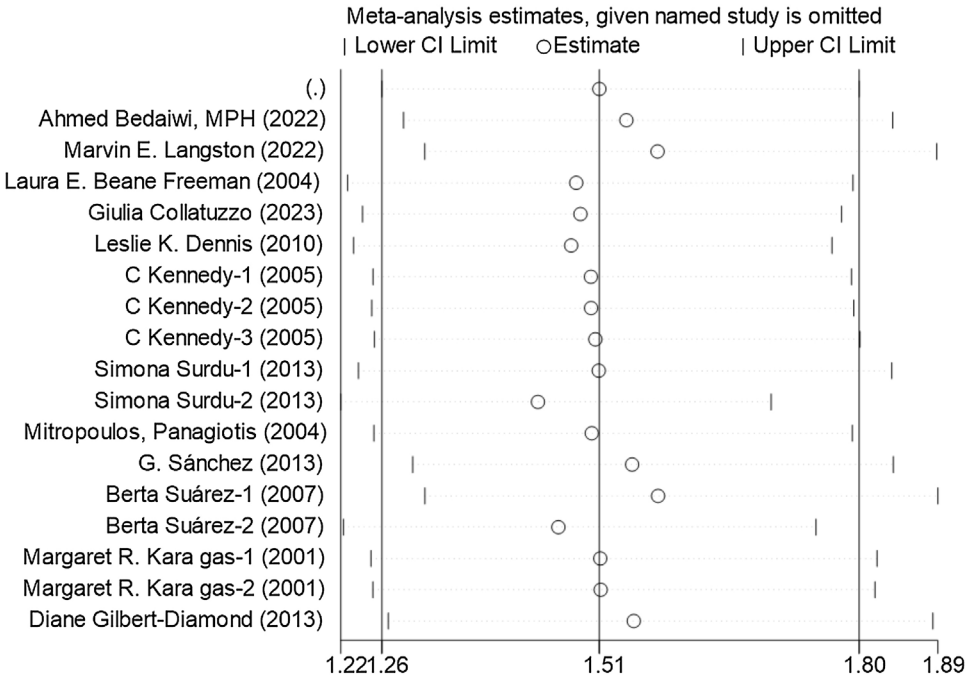

Fig. 3 Plot of single-study sensitivity analyses for all studies. Sources of heterogeneity were analyzed using a random-effects model. CI, Confidence Intervals.

Table 3 Subgroup analysis. Sample size, study center, US region, measurement methods, and subgroup analyses of arsenic exposure pathways; weights are from random-effects models.

Subgroup	Study	OR (95% CI)	p-value	I^2
USA				
Melanoma	3	1.35 (1.10, 1.65)	0.004	65.1
Basal cell carcinoma	2	1.58 (1.19, 2.11)	0.002	0
Squamous cell carcinoma	4	1.54 (1.18, 2.01)	p=0.001	47.8
Sample size				
< 100	3	1.64 (1.15, 2.23)	0.006	64.6
> 100	9	1.46 (1.23, 1.72)	p<0.001	35.8
Exposure route				
Cconsume	5	1.33 (1.07, 1.64)	0.233	26.9
Inhalation	7	1.72 (1.30, 2.27)	0.034	48.7
Research centre				
Single centre	8	1.41 (1.09, 1.82)	0.009	26.3
Multicentre	4	1.61 (1.24, 2.11)	p<0.001	42.6
Measurement method				
biomarker	5	1.33 (1.07, 1.64)	0.233	26.9
Occupational assessment semi-definable scale	5	1.80 (1.34, 2.42)	0.061	46.3

OR, Odds Ratio; CI, Confidence Interval.

further revealed a significant increase in the risk of skin cancer (both melanoma and non-melanoma) in the US due to arsenic exposure, with a pooled OR of 1.48 (95% CI 1.20–1.83). Whether through food intake (OR = 1.33, 95% CI 1.07–1.64) or inhalation (OR = 1.72, 95% CI 1.23–2.27), there was a consistent trend of increased risk of skin cancer associated with arsenic exposure. In the analysis of the arsenic measurement method (biomarker OR = 1.33, 95% CI 1.07–1.64, occupational assessment semi-definable scale OR = 1.80, 95% CI 1.34–2.42), the results are not biased.

Publication bias

Fig. 4 illustrates a funnel plot that shows the distribution of effect sizes from all studies, assessing publication bias. The plot displayed no notable asymmetry, as all studies were within the 95% Confidence Interval (95% CI) (Begg's p =

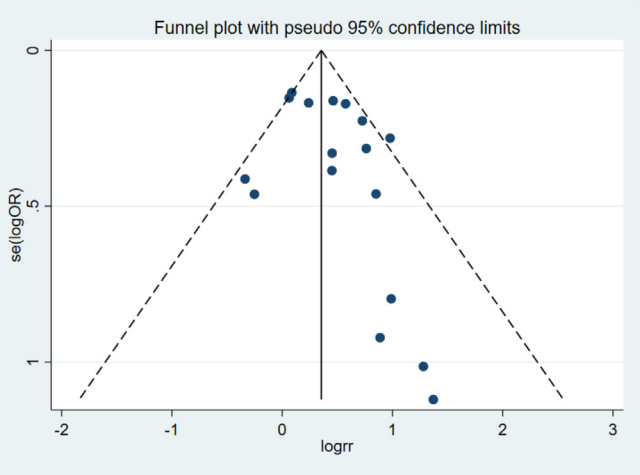

Fig. 4 Funnel plot of the association between arsenic exposure and skin cancer risk.

0.149). The results suggest that the analysis did not reveal any clear, significant bias in the publication.

Discussion

This groundbreaking meta-analysis is the initial study to investigate the association between exposure to arsenic and the likelihood of developing skin cancer, encompassing both melanoma and non-melanoma varieties. Firstly, the research examined 12 papers, comprising prospective and case-control studies involving 48,003 participants, offering some evidence of an association between exposure to arsenic and a heightened likelihood of developing skin cancer. Secondly, the quantification of arsenic exposure in the reviewed literature presents distinct advantages, such as the precise identification of biomarkers, including arsenic concentrations in water, urine, and toenails. Additionally, the use of semi-quantitative three-level scales (low, medium, high) for quantification enhances the research potential of the data. Thirdly, previous studies that did not meet the authors' criteria also supported these findings. For example, one study showed a significant association between inorganic Arsenic (iAs) and BCC, even at average water iAs concentrations below 40 ug/L.[45] A separate investigation conducted in the United States revealed a 1.5 times increased likelihood of developing SCC due to exposure to arsenic in rice, in contrast to individuals who did not consume rice.[46] Moreover, research carried out in Bangladesh through a cohort study established a direct association between the levels of arsenic in water and the occurrence of melanoma, BCC and SCC.[47] In a meta-analysis, Shuai et al.[48] found that arsenic exposure was associated with an increased risk of melanoma, with a pooled OR of 1.47 (95% CI 1.01–2.13). The results from previous studies, along with the meta-analysis, consistently indicate the possibility of a positive association between exposure to arsenic and the heightened risk of melanoma, BCC, and SCC. Additionally, the assessment using funnel plots and Begg's test did not show any significant evidence of small study effects. Subgroup and sensitivity analyses consistently indicated strong correlations.

The present study has several limitations. In the meta-analysis, the authors observed a notable degree of heterogeneity, which remained evident even following subgroup and sensitivity analyses. While such variability is not uncommon in similar studies, it is likely rooted in underlying differences across the literature, including population characteristics, adjustments for confounding variables, methodologies for determining outcomes, and approaches to assessing exposure. Due to the restricted quantity of research papers accessible, the authors were unable to perform stratified examinations according to levels of exposure to arsenic in the urine, arsenic in water, or exposure in the workplace. Additionally, combined estimates of arsenic concentrations across different exposure media may result in misclassification of exposure. Self-reported assessments through questionnaires are susceptible to memory bias, while data from biological samples, water, or air analysis may be subject to inaccuracies, potentially affecting the reliability of the association between arsenic exposure and the risk of developing skin cancer. Ultimately, personal protection measures, skin type, population mobility, and socioeconomic factors also represent significant potential confounding variables. The accuracy of a meta-analysis is contingent upon the quality of the underlying research. In case-control studies, key issues such as recall bias, varying measurement criteria, and residual confounders contribute to the risk of bias. While literature quality assessments and bias risk evaluations indicate that most studies have made adjustments for potential bias-inducing factors, the findings of meta-analyses may still be influenced. Due to the lack of high-quality studies that can effectively control for these bias factors, and because the results of studies with small sample sizes or statistical insignificance are often not easy to publish, the results of meta-analyses may still be affected and tend to report positive results. Therefore, the authors must be cautious in interpreting these results.

The precise molecular mechanisms involved in arsenic carcinogenesis are still being actively researched. It is widely acknowledged that arsenic exerts its toxicity through various pathways, such as inducing oxidative stress,[49] immune dysfunction,[50] genotoxicity,[51] impairing DNA repair,[10,52] and disrupting signal transduction.[53] It is believed that these procedures play a crucial role in the formation of skin cancer following arsenic exposure.

Arsenic triggers oxidative stress through the upregulation of Nicotinamide Adenine Dinucleotide Phosphate Oxidase (NADPHO), which results in the production of Reactive Oxygen Species (ROS). These ROS disturb the equilibrium of nitric oxide and glutathione, essential antioxidants, and affect other proteins responsible for redox homeostasis.[49,54] The formation of ROS triggers the activation of transcription factors like AP-1 and NF-κB, resulting in the excessive production of pro-inflammatory factors, which can enhance cell proliferation and potentially initiate carcinogenesis.[55]

Arsenic exposure activates the unfolded protein response signaling pathway, which impairs both innate and adaptive immunity by reducing immune cell function and number, creating a microenvironment conducive to tumor development.[51] Within cells, arsenic metabolism involves key enzymes like Adenine nucleoside Methionine (SAM). Depletion of SAM due to arsenic-induced ROS leads to the methylation of inorganic arsenic into methylated forms.

These methylated arsenic compounds further deplete SAM and can methylate DNA in an unregulated fashion, altering intracellular gene expression and potentially promoting carcinogenesis.[51,56] Additionally, arsenic disrupts cellular DNA repair mechanisms, such as base excision, mismatch repair and nucleotide excision, mainly by interfering with ATP and interacting with complexes likepoly-ADP ribose polymerase, O6-methyl-guanine-DNA methyltransferase and DNA polymerase β.[10,52] Impairment of these repair pathways may compromise genomic stability and disrupt normal cancer-related gene expression. Recent research indicates that arsenic triggers the Hippo pathway, which is critical for the survival and growth of cells. Arsenic modulates Hippo pathway activity by upregulating key proteins like Large Tumor Suppressor Kinase 1/2 (LATS1), Salvador homologue-1 (Sav1) and ste20-like kinase 1/2 (Mst1), which are known to play roles in various cancers, including skin cancer.[53,57]

Conclusions

This study demonstrates an association between arsenic exposure and the risk of skin cancer (both melanoma and non-melanoma), regardless of the exposure route – whether through inhalation, ingestion, or dermal contact. This finding could have significant implications for patient education initiatives, enhancing public awareness of skin cancer prevention and consequently reducing both its health and economic burdens. Furthermore, it may serve as a valuable reference for professionals involved in mitigating occupational exposure. However, the study's limitations highlight the need for future research. There is a clear necessity for more rigorous prospective studies that can better control potential confounding variables to understand the precise impact of arsenic on skin cancer risk. Additionally, evaluating the response to different doses will provide a more robust scientific basis for creating regulations on arsenic levels in a variety of sources, including drinking water, soil, air, and food. Drawing from the latest studies, the authors' recommendation is to initiate proactive measures aimed at not only validating arsenic as a contributing element to skin cancer but also crafting successful preventative tactics for areas plagued by chronic arsenic exposure.

Editor

Luciana P. Fernandes Abbade.

Research data availability

The entire dataset supporting the results of this study was published in this article.

Financial support

None declared.

Authors' contributions

Lijiao He: Conceptualization; methodology; software; investigation; formal analysis; writing-original draft.

Meiying Wei: Data curation; software; validation.

Qikui Yang: Visualization.

Yun Huang: Software; validation.

Zuyuan Wei: Conceptualization; supervision; writing-review & editing.

Conflicts of interest

None declared.

Appendix A Supplementary material.

Supplementary material related to this article can be found, in the online version, at doi:https://doi.org/10.1016/j.abd.2025.501161.

References

1. Boukamp P. Non-melanoma skin cancer: what drives tumor development and progression? Carcinogenesis. 2005;26:1657–67.
2. Franceschi S, Levi F, Randimbison L, La Vecchia C. Site distribution of different types of skin cancer: new aetiological clues. Int J Cancer. 1996;67:24–8.
3. Samarasinghe V, Madan V. Nonmelanoma skin cancer. J Cutan Aesthet Surg. 2012;5:3–10.
4. Samarasinghe V, Madan V, Lear JT. Management of high-risk squamous cell carcinoma of the skin. Expert Rev Anticancer Ther. 2011;11:763–9.
5. Macbeth AE, Grindlay DJ, Williams HC. What's new in skin cancer? An analysis of guidelines and systematic reviews published in 2008-2009. Clin Exp Dermatol. 2011;36:453–8.
6. Zhang XY, Zhang PY. Genetics and epigenetics of melanoma. Oncol Lett. 2016;12:3041–4.
7. Nikolaou V, Stratigos AJ. Emerging trends in the epidemiology of melanoma. Br J Dermatol. 2014;170:11–9.
8. Ho D, Lowenstein EJ. Fowler's solution and the evolution of the use of arsenic in modern medicine. Skinmed. 2016;14:287–9.
9. Piontek M, Hengels KJ, Borchard F, Strohmeyer G. [Noncirrhotic liver fibrosis afterchronic arsenic poisoning]. Dtsch Med Wochenschr. 1989;114:1653–7.
10. Yu HS, Liao WT, Chai CY. Arsenic carcinogenesis in the skin. J Biomed Sci. 2006;13:657–66.
11. Issanov A, Adewusi B, Saint-Jacques N, Dummer TJB. Arsenic in drinking water and lung cancer: A systematic review of 35 years of evidence. Toxicol Appl Pharmacol. 2024;483:116808.
12. Sassano M, Seyyedsalehi MS, Siea AC, Boffetta P. Occupational arsenic exposure and genitourinary cancer: systematic review and meta-analysis. Occup Med (Lond). 2023;73:275–84.
13. Sassano M, Seyyedsalehi MS, Siea AC, Boffetta P. Occupational arsenic exposure and digestive and head and neck cancers: A systematic review and meta-analysis. Environ Res. 2024;260:119643.
14. Krewski D, Rice JM, Bird M, Milton B, Collins B, Lajoie P, et al. Concordance between sites of tumor development in humans and in experimental animals for 111 agents that are carcinogenic to humans. J Toxicol Environ Health B Crit Rev. 2019;22:203–36.
15. IARC Working Group on the Evaluation of Carcinogenic Risks to Humans. Arsenic, metals, fibres, and dusts. IARC Monogr Eval Carcinog Risks Hum. 2012;100:11–465.
16. European Food Safety A. Dietary exposure to inorganic arsenic in the European population. EFSA Journal. 2014;12:3597.
17. Argos M, Kalra T, Pierce BL, Chen Y, Parvez F, Islam T, et al. A prospective study of arsenic exposure from drinking water

and incidence of skin lesions in Bangladesh. Am J Epidemiol. 2011;174:185–94.
18. Caldwell BK, Smith WT, Lokuge K, Ranmuthugala G, Dear K, Milton AH, et al. Access to drinking-water and arsenicosis in Bangladesh. J Health Popul Nutr. 2006;24:336–45.
19. McCarty KM, Hanh HT, Kim KW. Arsenic geochemistry and human health in South East Asia. Rev Environ Health. 2011;26:71–8.
20. Molin M, Ulven SM, Meltzer HM, Alexander J. Arsenic in the human food chain, biotransformation and toxicology – Review focusing on seafood arsenic. J Trace Elem Med Biol. 2015;31:249–59.
21. Straif K, Benbrahim-Tallaa L, Baan R, Grosse Y, Secretan B, El Ghissassi F, et al. A review of Human Carcinogens – Part C: Metals, Arsenic, Dusts, and Fibres. Lancet Oncol. 2009:453–4.
22. Kennedy C, Bajdik CD, Willemze R, Bouwes Bavinck JN. Chemical exposures other than arsenic are probably not important risk factors for squamous cell carcinoma, basal cell carcinoma and malignant melanoma of the skin. Br J Dermatol. 2005;152:194–7.
23. Surdu S, Fitzgerald EF, Bloom MS, Boscoe FP, Carpenter DO, Haase RF, et al. Occupational exposure to arsenic and risk of nonmelanoma skin cancer in a multinational European study. Int J Cancer. 2013;133:2182–91.
24. Mitropoulos P, Norman R. Occupational nonsolar risk factors of squamous cell carcinoma of the skin: a population-based case-controlled study. Dermatol Online J. 2005;11:5.
25. Sánchez G, Nova J. Risk factors for squamous cell carcinoma, a study by the National Dermatology Centre of Colombia. Actas Dermosifiliogr. 2013;104:672–8.
26. Suárez B, López-Abente G, Martínez C, Navarro C, Tormo MJ, Rosso S, et al. Occupation and skin cancer: the results of the HELIOS-I multicenter case-control study. BMC public health. 2007;7:180.
27. Karagas MR, Stukel TA, Morris JS, Tosteson TD, Weiss JE, Spencer SK, et al. Skin cancer risk in relation to toenail arsenic concentrations in a US population-based case-control study. Am J Epidemiol. 2001;153:559–65.
28. Gilbert-Diamond D, Li Z, Perry AE, Spencer SK, Gandolfi AJ, Karagas MR. A population-based case-control study of urinary arsenic species and squamous cell carcinoma in New Hampshire. USA. Environ Health Perspect. 2013;121:1154–60.
29. Smith AH, Goycolea M, Haque R, Biggs ML. Marked increase in bladder and lung cancer mortality in a region of Northern Chile due to arsenic in drinking water. Am J Epidemiol. 1998;147:660–9.
30. Cebrián ME, Albores A, Aguilar M, Blakely E. Chronic arsenic poisoning in the north of Mexico. Hum Toxicol. 1983;2:121–33.
31. Tseng WP, Chu HM, How SW, Fong JM, Lin CS, Yeh S. Prevalence of skin cancer in an endemic area of chronic arsenicism in Taiwan. J Natl Cancer Inst. 1968;40:453–63.
32. Hsueh YM, Chiou HY, Huang YL, Wu WL, Huang CC, Yang MH, et al. Serum beta-carotene level, arsenic methylation capability, and incidence of skin cancer. Cancer Epidemiol Biomarkers Prev. 1997;6:589–96.
33. Bedaiwi A, Wysong A, Rogan EG, Clarey D, Arcari CM. Arsenic Exposure and Melanoma Among US Adults Aged 20 or Older. 2003-2016. Public Health Rep. 2022;137:548–56.
34. Langston ME, Brown HE, Lynch CF, Roe DJ, Dennis LK. Ambient UVR and Environmental Arsenic Exposure in Relation to Cutaneous Melanoma in Iowa. Int J Environ Res Public Health. 2022;19:3574.
35. Beane Freeman LE, Dennis LK, Lynch CF, Thorne PS, Just CL. Toenail arsenic content and cutaneous melanoma in Iowa. Am J Epidemiol. 2004;160:679–87.
36. Collatuzzo G, Boffetta P, Dika E, Visci G, Zunarelli C, Mastroeni S, et al. Occupational exposure to arsenic, mercury and UV radiation and risk of melanoma: a case-control study from Italy. Int Arch Occup Environ Health. 2023;96:443–9.
37. Dennis LK, Lynch CF, Sandler DP, Alavanja MC. Pesticide use and cutaneous melanoma in pesticide applicators in the agricultural heath study. Environ Health Perspect. 2010;118:812–7.
38. Yager JW, Erdei E, Myers O, Siegel M, Berwick M. Arsenic and ultraviolet radiation exposure: melanoma in a New Mexico non-Hispanic white population. Environ Geochem Health. 2016;38:897–910.
39. Page MJ, McKenzie JE, Bossuyt PM, Boutron I, Hoffmann TC, Mulrow CD, et al. The PRISMA 2020 statement: an updated guideline for reporting systematic reviews. Syst Rev. 2021;10:89.
40. Stang A. Critical evaluation of the Newcastle-Ottawa scale for the assessment of the quality of nonrandomized studies in meta-analyses. Eur J Epidemiol. 2010;25:603–5.
41. Sterne JA, Hernán MA, Reeves BC, Savović J, Berkman ND, Viswanathan M, et al. ROBINS-I: a tool for assessing risk of bias in non-randomised studies of interventions. BMJ. 2016;355:i4919.
42. Borenstein M, Hedges LV, Higgins JP, Rothstein HR. A basic introduction to fixed-effect and random-effects models for meta-analysis. Res Synth Methods. 2010;1:97–111.
43. Higgins JP, Thompson SG. Quantifying heterogeneity in a meta-analysis. Stat Med. 2002;21:1539–58.
44. Begg CB, Mazumdar M. Operating characteristics of a rank correlation test for publication bias. Biometrics. 1994;50:1088–101.
45. Leonardi G, Vahter M, Clemens F, Goessler W, Gurzau E, Hemminki K, et al. Inorganic arsenic and basal cell carcinoma in areas of Hungary, Romania, and Slovakia: a case-control study. Environ Health Perspect. 2012;120:721–6.
46. Gossai A, Zens MS, Punshon T, Jackson BP, Perry AE, Karagas MR. Rice Consumption and Squamous Cell Carcinoma of the Skin in a United States Population. Environ Health Perspect. 2017;125:097005.
47. Choudhury MIM, Shabnam N, Ahsan T, Ahsan SMA, Kabir MS, Khan RM, et al. Cutaneous Malignancy due to Arsenicosis in Bangladesh: 12-Year Study in Tertiary Level Hospital. Biomed Res Int. 2018;2018:4678362.
48. Shuai W, Huang Q, Xu L, Mu Y. Association between arsenic exposure and melanoma: a meta-analysis. Int J Dermatol. 2024;63:1155–63.
49. Kumagai Y, Sumi D. Arsenic: signal transduction, transcription factor, and biotransformation involved in cellular response and toxicity. Annu Rev Pharmacol Toxicol. 2007;47:243–62.
50. Grivennikov SI, Greten FR, Karin M. Immunity, inflammation, and cancer. Cell. 2010;140:883–99.
51. Mahata J, Basu A, Ghoshal S, Sarkar JN, Roy AK, Poddar G, et al. Chromosomal aberrations and sister chromatid exchanges in individuals exposed to arsenic through drinking water in West Bengal. India. Mutat Res. 2003;534:133–43.
52. Vahidnia A, van der Voet GB, de Wolff FA. Arsenic neurotoxicity-a review. Hum Exp Toxicol. 2007;26:823–32.
53. Zhao B, Ye X, Yu J, Li L, Li W, Li S, et al. TEAD mediates YAP-dependent gene induction and growth control. Genes Dev. 2008;22:1962–71.
54. Kumagai Y. [Fusion of field and laboratory studies on the investigation of arsenic]. Yakugaku Zasshi. 2009;129:1177–85.
55. Kitchin KT, Ahmad S. Oxidative stress as a possible mode of action for arsenic carcinogenesis. Toxicol Lett. 2003;137:3–13.
56. Niedzwiecki MM, Hall MN, Liu X, Oka J, Harper KN, Slavkovich V, et al. A dose-response study of arsenic exposure and global methylation of peripheral blood mononuclear cell DNA in Bangladeshi adults. Environ Health Perspect. 2013;121:1306–12.
57. Halder G, Johnson RL. Hippo signaling: growth control and beyond. Development. 2011;138:9–22.

SOCIEDADE BRASILEIRA DE DERMATOLOGIA

Anais Brasileiros de Dermatologia

www.anaisdedermatologia.org.br

ORIGINAL ARTICLE

Artificial intelligence for the diagnosis of erythematous-squamous dermatological diseases: technological contributions to primary care

Raiza Brito Cipriano [a,*], **Wilson Falco Neto** [b], **Fabiano N. Barcellos Filho** [c], **Alexandre Dias Porto Chiavegatto Filho** [c]

[a] *Department of Medicine, Escola Superior de Ciências, Santa Casa de Misericórdia de Vitória, Vitória, ES, Brazil*
[b] *Department of Internal Medicine, Faculdade de Medicina de Catanduva, Catanduva, SP, Brazil*
[c] *Department of Epidemiology, Faculdade de Saúde Pública, Universidade de São Paulo, São Paulo, SP, Brazil*

Received 17 July 2024; accepted 30 October 2024
Available online 13 August 2025

KEYWORDS
Artificial intelligence;
Dermatology;
Diagnosis, differential;
Expert systems;
Machine learning

Abstract

Background: Accurate diagnoses in dermatology can be challenging for general practitioners. In this context, the support of artificial intelligence tools can be beneficial in the Brazilian primary care setting.

Objectives: To develop an interpretable machine-learning algorithm capable of assisting in the diagnosis of erythematous-squamous dermatological diseases through clinical data, without histopathological support.

Methods: The random-forest algorithm was trained with the public Dermatology database of 366 patients diagnosed with: chronic dermatitis, lichen planus, pityriasis rosea, pityriasis rubra pilaris, psoriasis, or seborrheic dermatitis. The model was evaluated by performance metrics and interpretability techniques.

Results: The model showed good predictive performance, with ROC-AUC ranging from 0.89 to 1.00, and overall accuracy of 0.86. The best results were for the diagnosis of pityriasis rubra pilaris (f1-score: 1.00) and the worst for chronic and seborrheic dermatitis (f1-score: 0.77 and 0.76, respectively). The clinical characteristics that most influenced the model's decision were, in decreasing order: involvement of knees and elbows, involvement of scalp, Koebner phenomenon, polygonal papules, and involvement of oral mucosa.

Study limitations: The model was not validated with Brazilian data.

* Corresponding author.
E-mail: ciprianoacademic@gmail.com (R. Brito Cipriano).

https://doi.org/10.1016/j.abd.2025.501169

Conclusion: The developed technology obtained good predictive performance and clinical coherence. There is a need for adaptation for implementation, using national data. The results indicate the potential for similar models to be improved and adapted to clinical practice for the benefit of the Unified Heath System.

Introduction

The different possible diagnoses in dermatology are often complex and require physicians to go through a long learning curve to make assertive diagnoses. A study comparing the performance of general practitioners and dermatologists in general clinical dermatology cases demonstrated agreement of only 45% of diagnoses in cases without support from histopathological data.[1] Another study, a systematic review with meta-analysis on medical efficacy in the diagnosis of melanoma, demonstrated a sensitivity of 81% for dermatologists, while primary care general practitioners had a sensitivity of only 42%.[2] In a similar vein, erythematous-squamous dermatological diseases, such as dermatitis, psoriasis, and lichen planus, can be difficult to differentiate and diagnose because they have very similar characteristics, especially for non-specialist physicians.

Machine learning models can be a useful tool to aid in diagnosis for physicians, especially general practitioners in primary care in the Brazilian Unified Health System (SUS, *Sistema Único de Saúde*), where there would be a greater concentration of dermatological diagnostic errors due to their generalist nature, with quick consultations and, in many cases, without the support of complementary exams. Some models have already been developed around the world for the diagnosis of erythematous-squamous dermatological diseases that have shown excellent performance, using clinical and histopathological data to predict diagnoses.[3] However, in scenarios where histopathological diagnosis is not possible or is time-consuming, tools that improve diagnostic accuracy without the support of complementary exams can optimize clinical practice, enabling more assertive treatments.

This study aimed to develop an interpretable machine-learning algorithm capable of differentiating and diagnosing six erythematous-squamous dermatological diseases, based on clinical data, without histopathological support.

Method

Database and preprocessing

The ''Dermatology'' database of erythematous-squamous dermatological diseases was used, which contains individualized data without patient identification. The data were originally made available through a partnership between the Department of Dermatology, Gazi University School of Medicine, and the Department of Computer Engineering and Computer Science, Bilkent University, and are freely available on the UC Irvine Machine Learning Data Repository.[4] Therefore, the present study does not require approval by a Research Ethics Committee.

The database contains clinical and histopathological data from 366 patients diagnosed with one of the six diseases under study: chronic dermatitis (n = 52), lichen planus (n = 72), pityriasis rosea (n = 49), pityriasis rubra pilaris (n = 20), psoriasis (n = 112), and seborrheic dermatitis (n = 61). The variables with clinical attributes are: erythema, desquamation, defined borders, pruritus, Koebner phenomenon, polygonal papules, follicular papules, involvement of the oral mucosa, involvement of knees and elbows, family history and age. The histopathological variables are: pigment incontinence, eosinophilic infiltrate, neutrophil infiltrate, papillary dermal fibrosis, exocytosis, acanthosis, hyperkeratosis, parakeratosis, widening of the epidermal ridges, elongation of the epidermal ridges, thinning of the suprapapillary epidermis, spongiform pustule, Munro's microabscess, focal hypergranulosis, the disappearance of the granular layer, vacuolization and damage to the basal layer, spongiosis, epidermal ridges in a ''sawtooth pattern'', follicular horny plug, perifollicular parakeratosis, mononuclear inflammatory infiltrate and band infiltrate.

Since the histopathological analysis, combined with clinical history, can be considered the ''gold standard'' in the diagnosis of erythematous-squamous dermatological conditions, it was decided to train the model without the support of these variables for prediction. The choice was made with the aim of developing a model that could assist clinical practice, which sometimes does not have access to histopathology.

Data preprocessing consisted of eliminating columns of histopathological data and patients with incomplete clinical data. The final set consisted of 359 patients, 98% of the original 366 evaluated patients.

Model and performance metrics

A machine learning model for Multiclass Classification was developed using the Random Forest algorithm and the ''One-vs.-Rest'' strategy, in Python via the Google Colab™ platform. The Holdout Method was used, in which the model was trained by dividing the data between training and testing subsets, in which 70% of these were used for learning the algorithm and 30% for testing and evaluating the predictive performance of the model on new data.

In the Random Forest model used, 100 trees were generated, with an average depth of 13.21; ranging from a maximum depth of 17 to a minimum of 11. For each node, a maximum number of features was selected based on the square root of the total number of available features (''sqrt''). The impurity criterion used was the Gini index, and the minimum number of samples per leaf was defined as

Table 1 Individual and overall measures of diagnostic model performance.

Disease	ROC-AUC	Sensitivity	Specificity	PPV	NVP	F1-score	Overall Model Accuracy
Chronic dermatitis	0.89	0.67	0.99	0.91	0.94	0.77	0.86
Lichen planus	1.00	0.90	1.00	1.00	0.98	0.95	
Pityriasis rosea	0.96	0.93	0.94	0.68	0.99	0.79	
Pityriasis rubra pilaris	1.00	1.00	1.00	1.00	1.00	1.00	
Psoriasis	0.98	0.91	0.96	0.91	0.96	0.91	
Seborrheic dermatitis	0.94	0.78	0.94	0.78	0.96	0.76	

ROC-AUC, Receiver Operating Characteristic - Area Under Curve; PPV, Positive Predictive Value; NVP, Negative Predictive Value.

1, while the minimum number of samples required to divide a node was 2.

To assess the predictive performance, a Confusion Matrix was generated and the area under the Receiver Operating Characteristic Curve (ROC-AUC), sensitivity, specificity, Positive Predictive Value (PPV), Negative Predictive Value (NPV), F1-score and model accuracy were calculated.

Interpretability

The model interpretation technique chosen was the SHAP (SHapley Additive exPlanations) method, which is based on the Shapley Values technique.[5] In this case, the objective is to explain the predictions of the machine learning model based on the contribution of each variable to the prediction of the final result.[6] In this study, the variables are the clinical characteristics of each patient and the final result, or prediction, is the diagnosis of one of the erythematous-squamous diseases in the study.

Thus, each clinical characteristic receives a SHAP value, indicating the impact of this variable on the diagnosis prediction. If the SHAP value of a variable is zero, it means that the presence or absence of that clinical characteristic does not influence the diagnostic decision made by the model. If the SHAP value is positive, the presence of the characteristic has an influence in favor of the diagnosis. On the other hand, if the SHAP value is negative, it is interpreted that the presence of the characteristic has an influence contrary to the diagnosis. Finally, high SHAP values (in modulus) indicate that the influence of the variable on the prediction is high, while low SHAP values (in modulus) indicate that the variable has little influence on the disease prediction.[6]

Results

Algorithm performance

The developed model showed good predictive performance, even without the support of histopathological variables (overall accuracy of the model: 86%), as shown in Table 1. The most assertive diagnoses were made in the predictions of the diseases pityriasis rubra pilaris and pityriasis rosea (sensitivity: 100% and 93%, respectively), while chronic dermatitis and seborrheic dermatitis attained the lowest metrics (sensitivity: 67% and 78%, respectively). Nevertheless, the model was successful in predicting negative results for these diseases, achieving high specificity and NPV values (chronic dermatitis: 99% and 94%; seborrheic dermatitis: 94% and 96%). Fig. 1 shows the ROC curves resulting from the predictive analysis of the test data.

The algorithmic performance results become clear when analyzed together with the Confusion Matrix of predicted versus actual results, shown in Fig. 2 below.

Model interpretability: the importance of clinical variables

For a general analysis, the characteristics were classified in decreasing order of influence on the model's decisions, using the average absolute impact values (average SHAP).

The clinical characteristics that most influenced the differentiation between the analyzed skin diseases – that is, those with the highest average SHAP – were: involvement of knees and elbows, involvement of the scalp, Koebner phenomenon, polygonal papules, involvement of the oral mucosa and defined borders, as observed in Fig. 3 below. The characteristics ''family history'', ''erythema'' and ''age'' had little influence on the general diagnosis.

It is also possible to observe how much each characteristic contributes, in absolute terms, to each diagnosis; for example: the variables ''involvement of knees and elbows'' and ''involvement of scalp'' have a very significant influence on the diagnosis of psoriasis (blue bars), while the variables ''polygonal papules'' and ''involvement of oral mucosa'' had a greater influence on the diagnosis of lichen planus (green bars). Thus, the diseases associated with the best predictive performances of the model are those that have unique distributions of mean SHAP values. Likewise, diseases with similar distributions of mean SHAP values among the variables, such as when comparing chronic and seborrheic dermatitis (red and purple bars, respectively), have the worst predictive performances, since the model may have difficulty differentiating them.

The influences of clinical characteristics in the definition of each differential diagnosis can also be observed in more detail and individually in the Beeswarm-type graphs, in Figs. 4, 5 and 6 below. In this case, it is possible to identify how the variables influenced the model decision-making process, in which the values of the variables (pink tones are higher values, indicating a greater presence of the characteristic, and blue tones are lower values, indicating a lesser presence of the characteristic) correlate with the impact on the diagnostic result (positive SHAP-values are favorable to the diagnosis in question, while negative SHAP-values are unfavorable to the diagnosis).

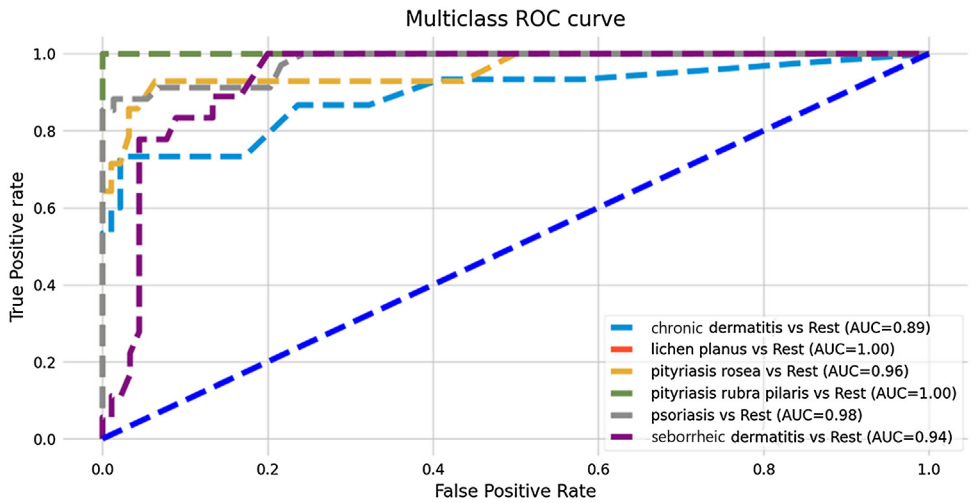

Figure 1 ROC curves of the Random Forest model for multi-class classification and values of their respective Areas Under the Curve (AUC).

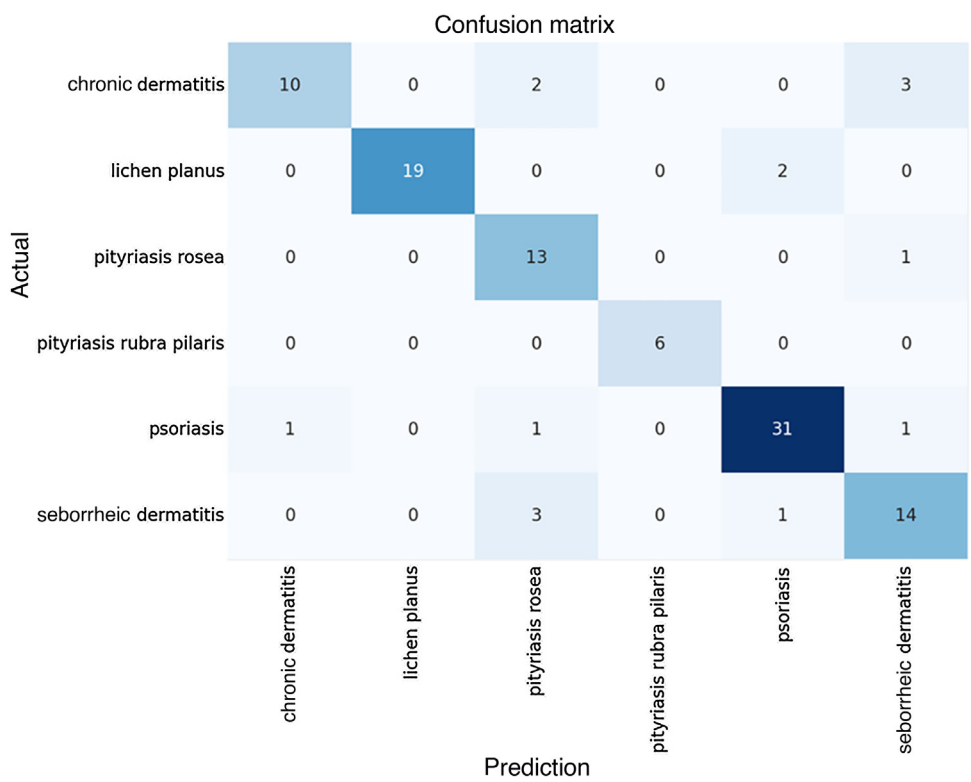

Figure 2 Confusion matrix.

Based on the interpretation of the proposed model and the clinical characteristics made available for this analysis, it can be verified that chronic dermatitis (ROC-AUC = 89%) was positively correlated mainly with pruritus and lower desquamation values, while the presence of the Koebner phenomenon had an unfavorable effect on the diagnosis. Lichen planus (ROC-AUC = 100%) was positively and significantly correlated with the presence of polygonal papules and involvement of the oral mucosa. Pityriasis rosea (ROC-AUC = 96%) correlated positively and significantly with the Koebner phenomenon, while the presence of higher values of pruritus, and involvement of knees, elbows, scalp or polygonal papules had an unfavorable effect on the diagnosis. Pityriasis rubra pilaris (ROC-AUC = 100%) correlated positively and significantly with the presence of follicular papules, mean values of involvement of knees and elbows, and during young age (first two decades of life). The prediction of psoriasis (ROC-AUC = 98%) was positively and significantly influenced mainly by the involvement of knees, elbows and/or scalp. Finally, seborrheic dermatitis

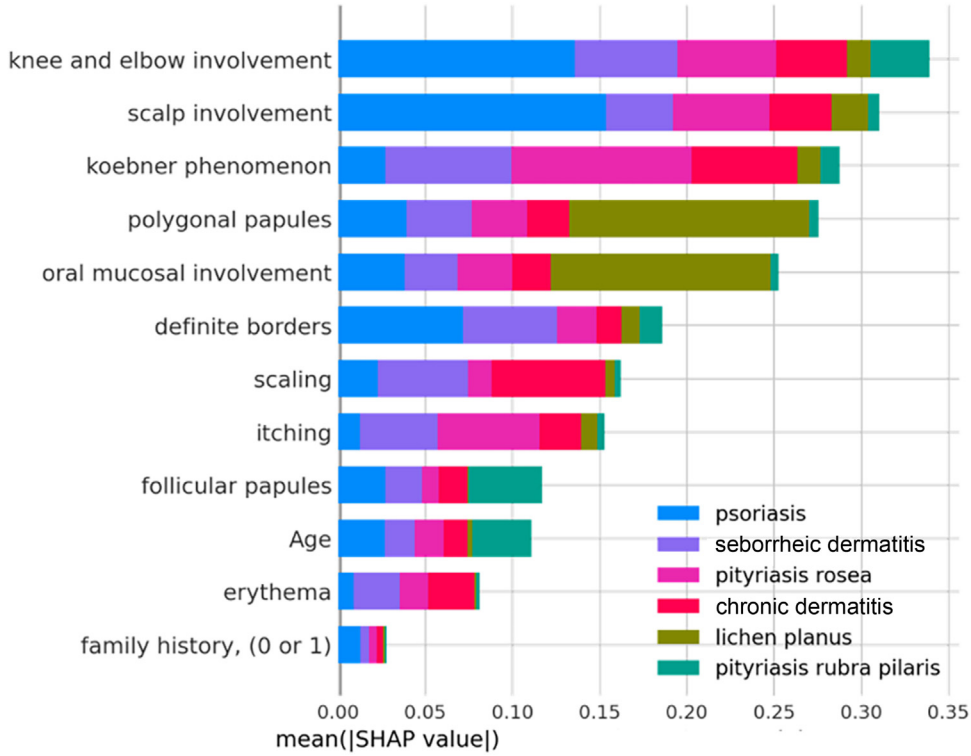

Figure 3 SHAP Summary Plot: overall importance of variables for predicting outcomes and contribution to specific predictions.

Figure 4 Beeswarm Plots: psoriasis (left) and seborrheic dermatitis (right).

(ROC-AUC = 94%) had its prediction positively influenced by desquamation, pruritus and erythema. On the other hand, the presence of the Koebner phenomenon, involvement of knees and elbows, and defined borders had an unfavorable effect on its diagnosis.

Discussion

Overall, the model showed good predictive performance, showing an overall accuracy of 86%. Studies published around the world were found, predominantly in electronic engineering and technology journals, which used the same database to develop different predictive algorithms for erythematous-squamous diseases, all of which used clinical and histopathological variables to predict the diagnosis. One of these studies used Classification and Regression Tree (CART), obtained an overall accuracy of 93.69% and similar results to the present study, showing a specificity of 100% for ''lichen planus'' and ''pityriasis rubra pilaris'', and showed better sensitivity for ''seborrheic dermatitis'' (100%) when compared to this study (78%).[7] Another study

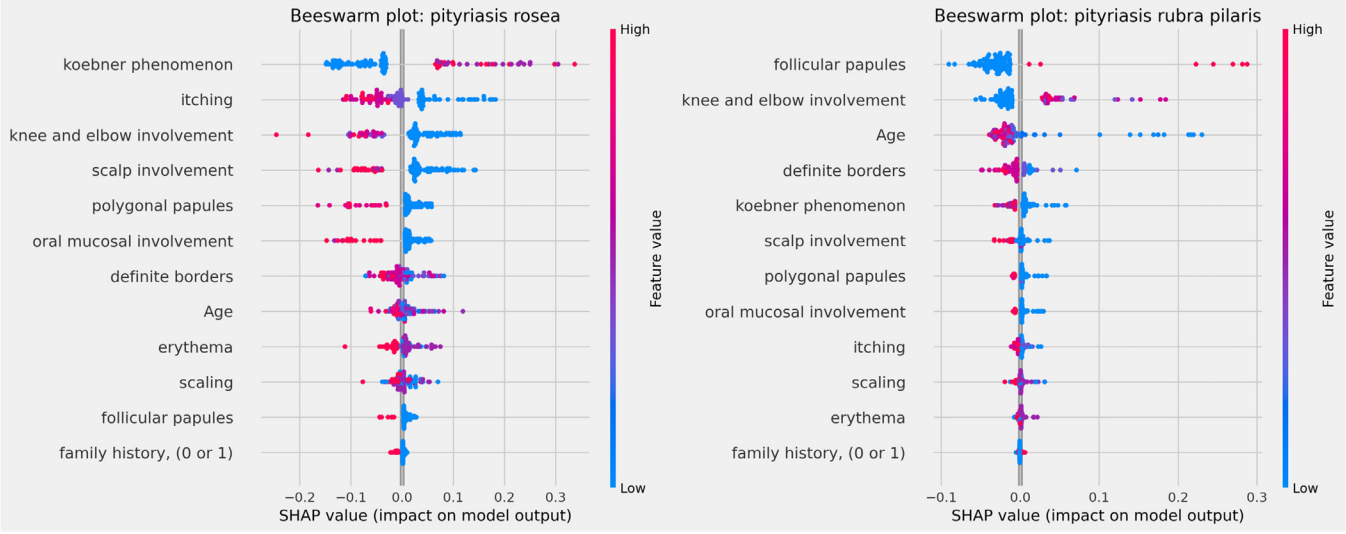

Figure 5 Beeswarm Plots: pityriasis rosea (left) and pityriasis rubra pilaris (right).

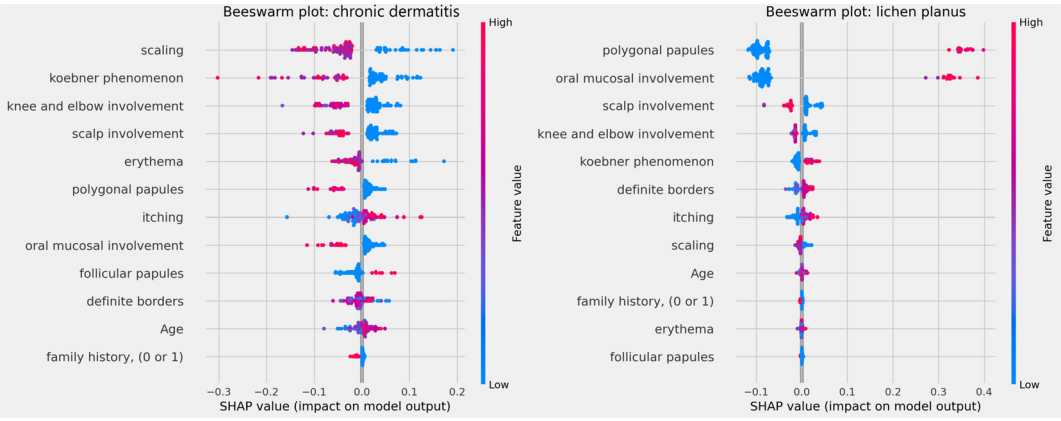

Figure 6 Beeswarm Plots: Chronic dermatitis (left) and lichen planus (right).

also used Random Forest and showed cross-validation values of 51.13%. Higher values were obtained by other algorithms, such as 96.65% with Deep Neural Networks and 95.80% with XGBoost.[8]

The results found by the study demonstrate the potential for applying machine learning algorithms in dermatological diagnosis. When compared to the results of this study, without histopathological data, it is clear that the algorithm did not suffer a significant loss of performance, making it viable for clinical practice. The importance of tools like this lies in the possibility of optimizing clinical practice aiming to provide assertive treatments without the support of complementary exams.

When the interpretability of the results is verified, that is, how the variables contributed to the prediction of each diagnosis (Fig. 2), an important convergence with clinical practice can be observed. When observing the characteristics of pityriasis rubra pilaris in the medical literature, one of the main characteristics common to the disease subtypes is the presence of hyperkeratotic follicular papules. Furthermore, pityriasis rubra pilaris is diagnosed according to its subtypes, which are based on age of onset, lesion distribution and prognosis[9] – these characteristics are in line with the main findings of this study. In psoriasis, the involvement of knees and elbows is also a characteristic of the clinical diagnosis and the Koebner phenomenon demonstrated relevance, as expected.[10] Thus, the exercise of comparing the results of this study with the medical literature can be performed for each disease analyzed.

A limitation of the model lies in its dependence on the quality of the database. In this study, the data collected from a non-Brazilian population may not be representative of the characteristics of the local population. These limitations were also verified and mitigated in the study by Wichmann et al., who developed models for predicting death from COVID-19 with data from 18 Brazilian hospitals and compared optimization strategies, finding that the best performance occurred when the model was trained locally, that is when a model was trained with data from a hospital to predict the data from the same hospital.[11] Moreover, the quality of the data for training depends on the data collection operator, while the quality of the results depends on the end user during the clinical use of the proposed model, since an incorrectly identified clinical sign could lead to an incor-

rect diagnosis. Some of the characteristics of lesions used to train the model under study may require greater knowledge from the operator and user, such as the definition of the Koebner phenomenon and differentiation between papules.

Therefore, the developed technology requires adaptations for its local implementation, since the predictive capacity with data from other hospitals, especially from other continents, may present variations that impact its effectiveness. In addition to training on a local database, the model would need to be incorporated into software with an intuitive and instructive interface, to support general practitioners in characterizing the lesions according to the recommended scales. Also, the inclusion of a functionality for reading and interpreting photos of skin lesions would make the technology even more useful in non-specialized clinical practice.

Final considerations

This study identified technological possibilities applicable to the Unified Heath System, proposing the construction of a machine learning algorithm for multiclass classification of erythematous-squamous dermatological diseases with the potential to assist in the reality of clinical practice in Brazilian public primary care. For future studies, it will be important to develop this technology to include the construction of an updated and multicenter Brazilian database, and the improvement of the prediction technique using models capable of interpreting photos of skin lesions, incorporated into software with an interface suitable for use by non-specialist physicians.

Research data availability

The entire dataset supporting the results of this study was published in this article.

Editor

Luciana P. Fernandes Abbade.

Financial support

None declared.

Authors' contributions

Raiza Brito Cipriano: Design and planning of the study; analysis and interpretation of data; implementation of computer code and supporting algorithms; drafting and editing of the manuscript or critical review of important intellectual content.

Wilson Falco Neto: Drafting and editing of the manuscript or critical review of important intellectual content.

Fabiano N. Barcellos Filho: Implementation of computer code and supporting algorithms; drafting and editing of the manuscript or critical review of important intellectual content; effective participation in research orientation.

Alexandre Dias Porto Chiavegatto Filho: Drafting and editing of the manuscript or critical review of important intellectual content; effective participation in research orientation; critical review of the literature; approval of the final version of the manuscript.

Appendix A. Supplementary material

Supplementary material related to this article can be found, in the online version, at doi:https://doi.org/10.1016/j.abd.2025.501169.

Conflicts of interest

None declared.

References

1. Tran H, Chen K, Lim AC, Jabbour J, Shumack S. Assessing diagnostic skill in dermatology: a comparison between general practitioners and dermatologists. Australas J Dermatol. 2005;46:230–4.
2. Chen SC, Bravata DM, Weil E, Olkin I. A comparison of dermatologists' and primary care physicians' accuracy in diagnosing melanoma: a systematic review. Arch Dermatol. 2001;137:1627–34.
3. Chan S, Reddy V, Myers B, Thibodeaux Q, Brownstone N, Liao W. Machine learning in dermatology: current applications, opportunities, and limitations. Dermatol Ther (Heidelb). 2020;10:365–86.
4. Ilter N, Güvenir H [cited 2024 Fev 6]. UCI Machine Learning Repository. Available from: https://archive.ics.uci.edu/dataset/33/dermatology, 1998, http://dx.doi.org/10.24432/C5FK5P.
5. Lundberg SM, Erion G, Chen H, DeGrave A, Prutkin JM, Nair B, et al. From local explanations to global understanding with explainable AI for trees. Nat Mach Intell. 2020;2:56–67.
6. Molnar C [cited 2024 Fev 6]. Available from: Interpretable machine learning: A guide for making black box models explainable. 2nd ed Munique (DE): Leanpub; 2022 https://christophm.github.io/interpretable-ml-book/
7. Maghooli K, Langarizadeh M, Shahmoradi L, Habibi-Koolaee M, Jebraeily M, Bouraghi H. Differential diagnosis of erythmato-squamous diseases using classification and regression tree. Acta Inform Med. 2016;24:338–42.
8. Putatunda S. A hybrid deep learning approach for diagnosis of the Erythemato-Squamous disease. In: Proceedings of the 2020 IEEE International Conference on Electronics, Computing and Communication Technologies (CONECCT). 2020. p. 1–6.
9. Greiling TM, Brown F, Syed HA. Pityriasis Rubra Pilaris. In: StatPearls [Internet]. Treasure Island (FL): StatPearls Publishing LLC; 2024 [cited 2024 Fev 6]. Available from: https://www.ncbi.nlm.nih.gov/books/NBK482436/
10. Raychaudhuri SK, Maverakis E, Raychaudhuri SP. Diagnosis and classification of psoriasis. Autoimmun Rev. 2014;13:490–5.
11. Fernandes FT, de Oliveira TA, Teixeira CE, Batista AFM, Costa GD, Chiavegatto Filho ADP. A multipurpose machine learning approach to predict COVID-19 negative prognosis in São Paulo, Brazil. Sci Rep. 2021;11:3343.

SOCIEDADE BRASILEIRA DE DERMATOLOGIA

Anais Brasileiros de Dermatologia

www.anaisdedermatologia.org.br

ORIGINAL ARTICLE

B-cell subsets in leprosy lesions: unraveling the complex interplay☆

Luis Alberto Ribeiro Fróes Junior [a,*], **Carla Pagliari** [a], **Maria Angela Bianconcini Trindade** [b], **Mirian Nacagami Sotto** [a,c]

[a] *Department of Pathology, Faculty of Medicine, Universidade de São Paulo, São Paulo, SP, Brazil*
[b] *LIM56, Hospital das Clínicas, Faculty of Medicine, Universidade de São Paulo, São Paulo, SP, Brazil*
[c] *Instituto de Medicina Tropical da Faculty of Medicine, Universidade de São Paulo, São Paulo, SP, Brazil*

Received 11 December 2024; accepted 18 January 2025
Available online 9 August 2025

KEYWORDS
B-lymphocyte subsets;
Immune response;
Immunohistochemistry;
Leprosy

Abstract
Background: Leprosy is a chronic infectious disease marked by complex immune interactions, yet the roles of specific B-lymphocyte subsets in its pathology are poorly understood.
Objectives: To investigate the presence and distribution of B-cell subsets, including B1 cells, Marginal Zone (MZ) B-cells, Regulatory B-cells (Bregs), and Effector-1 B-cells (Be1), across different clinical forms of leprosy and reactional states.
Methods: Immunohistochemical and morphometric analyses were performed on skin lesions from patients with various clinical presentations of leprosy.
Results: CD20+ B-cells were abundant in tuberculoid lesions, whereas MZB-1 expression varied significantly among leprosy subtypes. Type 1 Reaction (T1R) lesions exhibited significantly higher counts of B1 and MZ B-cells compared to Type 2 Reaction (T2R), lepromatous leprosy (LL), and indeterminate leprosy (I). Expression patterns of PAX5/MZB-1 and PAX5/CD5 suggested a dominant presence of these cells in the Th1 pole. Be1 cells, strongly linked to Th1 immune response, were also more abundant in Th1 clinical presentations (tuberculoid and T1R leprosy). Although Bregs were generally scarce, they were most frequently observed in T1R.
Study limitations: This study was limited by the relatively small number of cases analyzed per clinical subtype and reactional state.
Conclusions: This is the first study to document the presence and distribution of these specific B-cell subsets in leprosy lesions. The findings suggest distinct roles for B-lymphocyte subtypes, particularly at the tuberculoid pole and during Type 1 reactions.

☆ Study conducted at the Department of Pathology, Hospital das Clínicas, Faculty of Medicine, Universidade de São Paulo, SP, Brazil.
* Corresponding author.
E-mail: lulafroes@usp.br (L.A. Fróes Junior).

https://doi.org/10.1016/j.abd.2025.501184

Introduction

The spectral manifestations of leprosy reflect the host's immune response against *Mycobacterium leprae*.[1] As an obligate intracellular bacterium, the effectiveness of the immune response against leprosy primarily relies on cellular immunity, with the balance between Th1 and Th2 playing a pivotal role in determining the clinical presentation of the disease. The progression from tuberculoid (localized) to lepromatous (disseminated) leprosy is marked by a shift from Th1 (cellular) to Th2 (humoral) response. Consequently, the cytokine profile varies between presentations, with Th1 cytokines (such as IFN-γ, IL-2, and IL-12) in tuberculoid leprosy and Th2 cytokines (such as IL-4, IL-5, IL-10, and TGF-β) in lepromatous leprosy.[2]

''Indeterminate'' leprosy presents with a hypochromic macule with diminished local sensitivity, potentially evolving with spontaneous healing or progressing to a classic presentation. This type of leprosy has no clear predominance of Th1 or Th2 response.[1]

Leprosy reactions are episodes of acute hypersensitivity characterized by the worsening of previous lesions or the appearance of new ones. Type 1 reaction is a type IV hypersensitivity reaction characterized by an exacerbation of the cellular immune response against *M. leprae*, with significant secretion of TNF-α, IFN-γ, IL-2, IL-1β, and IL-6.[3] Type 2 reaction involves a systemic inflammatory process related to extravascular deposition of immune complexes and neutrophilic exudate, with high levels of TNF-α, IL-2, IL-4, IL-5, IL-6, and IL-10.[3]

In 1993, Modlin et al.[4] published studies linking the clinical spectrum of leprosy to Th1-Th2 responses. Since then, most of the research in leprosy immunology has concentrated on T-cells. Although Ridley et al. first described the presence of B-cells in 1974, the focus on T-cells over the decades led to limited investigation into the role of B-cells.[5] It was only recently, in 2017, that Fachin et al.[6] revealed an increased presence of B-cells in the Th1 pole, challenging the previous assumption that B-cells would be predominantly associated with the Th2 pole, which is typically linked to humoral responses.

Mammalian B-cells encompass distinct subsets, including Follicular B2 cells, B1-cells, Marginal Zone B-cells (MZB), B-Regulatory cells, and B-Effector-1 (Be1) cells.[7,8] B1-cells, originating during fetal development, inhabit the peritoneal cavity, exhibiting self-renewal and spontaneous IgM secretion. Despite controversies in the literature regarding the characterization of B1 B-cells in humans,[9–11] reports indicate that they constitutively express CD5 (B1a cells) and spontaneously secrete multi-reactive IgM, facilitating early bacterial clearance.[12]

MZ B-cells, another category of B-lymphocytes, inhabit the marginal zone of lymphoid follicles within the spleen and several other tissues.[13] These cells orchestrate swift antibody responses against blood-borne microbes rich in polysaccharides. Along with B1-cells, a subset of MZ B-cells, specifically the transitional type 2 marginal zone precursor (T2-MZP) B-cells, are termed Innate-Like B-Lymphocytes (ILBs) or innate B regulatory cells (Bregs) due to their ability to secrete IL-10, a regulatory cytokine.[14] Bregs contribute to cutaneous immune responses and exhibit both pro-inflammatory and regulatory actions.[15]

A recently recognized B-cell subset, the B-effector-1 (Be1) cell, shares resemblances with T-helper-1 (Th1) cells and seems to bridge innate and adaptive immune responses.[16,17] Be1 cells release inflammatory Th1-like cytokines such as IFN-γ, TNF-α, and IL-12.[18,19]

By dissecting the intricate interplay between these B-cell subsets and the mycobacterial environment within leprosy lesions, the present investigation aims to provide a comprehensive understanding of the in situ immune response in leprosy. The present findings hold the potential to inform therapeutic strategies and refine disease management approaches, opening new avenues for effective intervention.

Materials and methods

This study involves a case series examination. Initially gathered for diagnosing and classifying classical forms of leprosy and reactive states, skin samples have been selected from the archives of the Dermatopathology Laboratory at the Dermatological Clinic, Department/Division of the University of São Paulo Medical School. These samples were processed using histological techniques and embedded in paraffin. The authors examined skin samples from 95 patients with various clinicopathological manifestations of leprosy. These included lepromatous leprosy (18 samples), tuberculoid leprosy (23 samples), indeterminate leprosy (14 samples), Type 1 Reaction (19 samples), and Type 2 Reaction (21 samples). Specifically, for comparisons within the CD20 group, the authors utilized a control group comprising samples of normal skin from 10 patients. In contrast to Dendritic and T-cells, B-cells are known to be very scarce in normal skin under homeostatic conditions.[20] Nonetheless, the authors established a dedicated control group for CD20 to reaffirm this observation and eliminate the need for controls in B-cell subsets. All histological samples of leprosy lesions were stained with hematoxylin-eosin and the acid-fast bacilli staining technique (Faraco technique) for diagnostic confirmation. Additionally, patient records were consulted to aid in the classification and composition of study groups.

Immunohistochemical techniques

Four micrometer paraffin-embedded sections were obtained from all specimens and subjected to single-labeling techniques using CD20 (B-cells) and MZB-1 (B1-cells, MZB-cells, and plasmablasts/plasma cells) antibodies.[20] For better discrimination between the MZB-cell population and plasmablasts/plasma cells at the lesion sites, the authors performed double labeling PAX5/MZB-1 to distinguish the MZB/B1-cells in the tissue from plasmablasts and plasma cells, which have silenced PAX5 expression.[21] The authors also performed double-staining for PAX5/CD5 (B1-cells),

Table 1 Antibodies, detection systems, and chromogens specifications.

Primary antibody	ID Code	Manufacturer	Dilution/Detection system
Anti-CD5 rabbit antibody	SP-19	Cell-marque	1:50/Polink
Anti-PAX5 mouse antibody	312M-15	Cell-marque	1:200/Envision flex
Anti-CD20 mouse antibody	AC-0012	Epitomics	1:100/Envision flex
Anti-MZB-1 rabbit antibody	11454-1	Proteintech	1:200/Polink
Anti-Tbet rabbit antibody	aB-150440	ABcam	1:200/Polink
Anti-c-MAF rabbit antibody	SC7866	Vector	1:100/Impress
Chromogens used for double labeling technique	ID Code	Manufacturer	Dilution/Detection system
Membrane/cytoplasm			
PermaGreen / HRP substrate	K074-RUO	Diagnostic BioSystems	Not applicable
Nucleus			
3.3′-Diaminobenzidine tetrahydrochloridrate	D5637-50G	Sigma Life Science	Not applicable

CD20/T-bet (Be1-cells), and CD20/c-MAF (Bregs) with a protocol modified by Tudor et al.[22] For Bregs, the authors initially attempted to perform dual labeling with PAX5/IL-10; however, due to unsatisfactory results, the authors opted for labeling surface CD20 with the IL-10 nuclear transcription factor, c-MAF, also expressed by regulatory B-lymphocytes.[23–25] The choice for CD20/c-MAF yielded more easily discernible and reliable results. Table 1 displays the antibody specifications, detection systems, and chromogens used for the immunohistochemical procedures. Detailed technique descriptions are given as Supplementary data.

Fluorescence confocal microscopy

The immunofluorescence technique protocol for confocal microscopy was performed as follows: both primary antibodies, anti-IgM, and anti-PAX5, were diluted and mixed in 1% bovine albumin solution and incubated for 48 hours at 4°C. Following, it was applied the isotype-specific secondary conjugated antibodies Alexa Fluor® 488 (green) goat anti-rabbit Ig and AlexaFluor® 555 (red) donkey anti-mouse Ig, Invitrogen, Carlsbad, CA, USA, and nuclear staining with 6-Diamidino-2-Phenylindole, Dihydrochloride DAPI - Sigma-Aldrich, Steinhein, Germany (blue) for 60-minutes. The slides were mounted in a mounting medium (Hydromount, National Diagnostics, Atlanta, GA, USA) and glass coverslips and maintained protected from light at 4°C until analysis. Fluorescent images were acquired using UV/Laser excitation on confocal microscopy Olympus FluoView 1000 (FV1000). Given the limited number of cases analyzed, a total of 5, quantitative morphometric analyses were not conducted.

Morphometric and statistical analyses

All slides immunostained with CD20 and MZB-1 antibodies were scanned with the 3DHISTECH ''whole slide imaging'' system (Budapest, Hungary). For morphometric analysis, images with a digital zoom of 10× were obtained from successive, non-superimposable fields of the entire dermis for each sample, using Case Viewer software (2.3 version 64-bit, 3DHISTECH Ltd.).

The images were processed using the freely available Fiji/ImageJ software from the National Institutes of Health (http://imagej.nih.gov). Following the methodological approach outlined by Biswas et al.,[25] the authors comprehensively analyzed all images associated with each sample. The arithmetic means of the immunostained area fraction, specifically for CD20 and MZB-1, was then calculated for each sample (case). In analyses involving colocalization of antigens, double positive cells were manually counted in each *hotspot* of whole-slide images, divided by the total number of B-cells in the same field, and then by the field dermal area (estimated by the free Fiji/ImageJ software). After analyzing all images for each sample, an arithmetic mean was calculated for the proportion of double immunostained cells to the total B-cells (CD20 or PAX5 positive cells) per unit of area. Thus, the use of the term 'expression' later in the text refers specifically to the number of positive cells or the fraction of immunolabeled tissue, rather than to staining intensity.

Non-parametric one-way ANOVA followed by Kruskall Wallis' multiple comparisons test was performed using GraphPad Prism version 10.1.0 for macOS, GraphPad Software, Boston, Massachusetts USA, www.graphpad.com. A p-value < 0.05 was considered statistically significant.

Results

Samples from 95 cases and 10 controls were analyzed. Among the cases, the male-to-female ratio was 11:9, indicating a slightly higher representation of males. This group had an average age of 44.64, from 8 to 84 years. In the control group, the average age was (44.7-years.) with a corresponding male-to-female ratio of (5:5).

Presence and distribution of single-labeled cells

The presence and distribution of B-lymphocytes differed in the tissue response among the studied leprosy groups. B-cells were observed in the papillary dermis and around epithelioid granulomas in tuberculoid leprosy samples (Fig. 1A). In indeterminate leprosy, B-cells were scarce and, when present, were located near blood vessels and cutaneous adnexa (Fig. 1B). Rare lymphocytes were observed

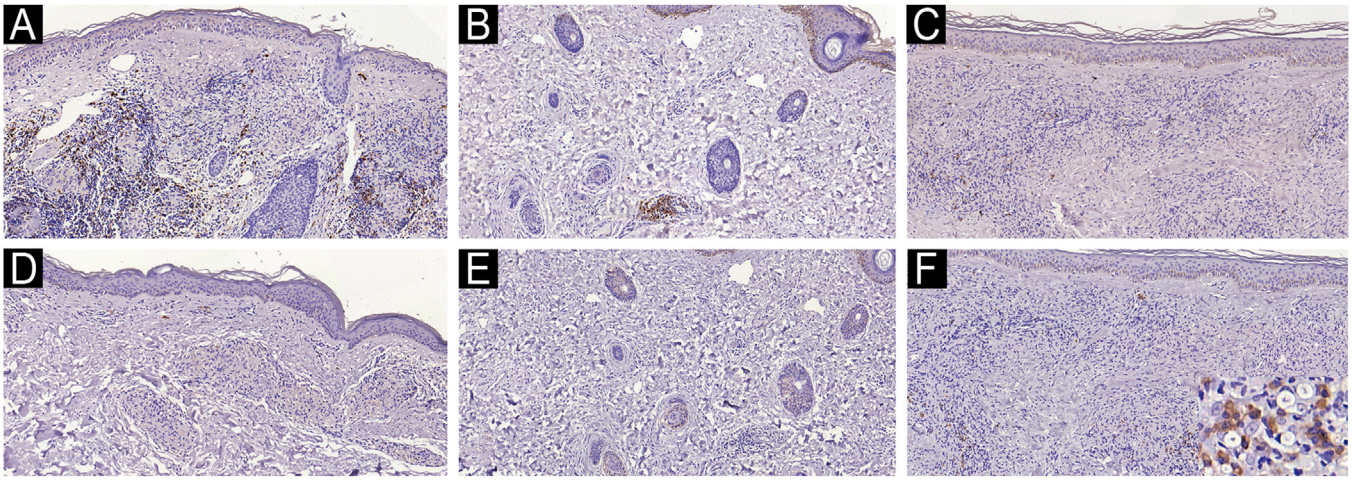

Fig. 1 B (CD20+) cells in tuberculoid leprosy arranged around granulomas (A) and cells immunolabeled with the MZB1 antibody (D). Presence of rare perivascular B-cells (B) and absence of MZB1 expression (E) in indeterminate leprosy. In lepromatous leprosy, note rare clusters of B-cells within the diffuse macrophage infiltrate (C) and rare cells immunolabeled with the MZB1 antibody, some of them with plasma cell morphology (inset) (F). Immunohistochemical technique, diaminobenzidine chromogen, and counterstaining with hematoxylin. Scale bars (left top) indicate the magnification.

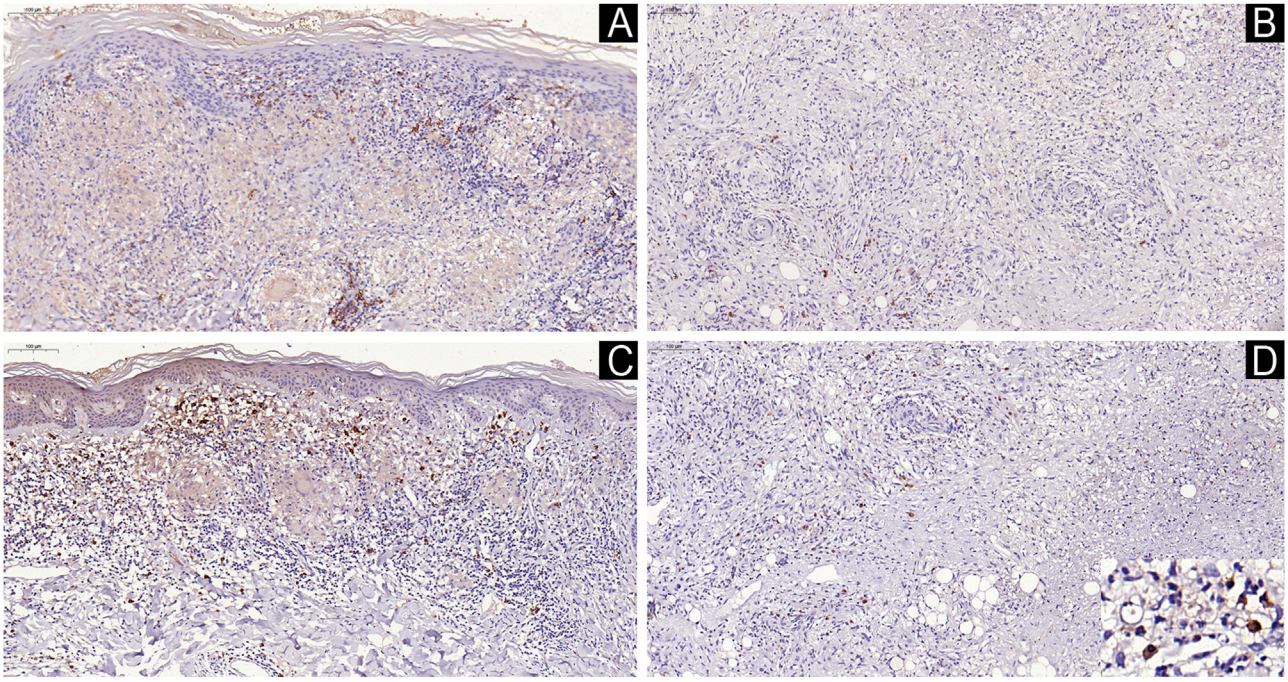

Fig. 2 In type 1 reaction, B (CD20+) cells are present in the papillary dermis and around epithelioid granuloma in the reticular dermis (A). Cells immunolabeled with the MZB1 antibody are observed in the papillary dermis; however, they are absent around the granuloma (C). In type 2 reaction, rare B-cells amidst the regressive macrophage infiltrate (B) and a few clusters of cells immunolabeled with the MZB1 antibody, some of them with plasma cell morphology (inset) (D). Immunohistochemical technique, diaminobenzidine chromogen, and counterstaining with hematoxylin. Scale bars (left top) indicate the magnification.

alongside vacuolated macrophages in the tissue response of lepromatous leprosy samples (Fig. 1C). B-cells were slightly more abundant, arranged around granulomas, in type 1 reaction leprosy (Fig. 2A) and scarce in type 2 reaction leprosy skin samples (Fig. 2B).

Cells immunostained with the MZB-1 antibody exhibited morphology, sometimes like lymphocytes, sometimes slightly larger and resembling plasma cells. They appeared scarcer than CD20 in tuberculoid leprosy samples (Fig. 1D) and extremely scarce or absent in indeterminate leprosy samples (Fig. 1E). On the other hand, in lepromatous leprosy samples, MZB-1 positive cells were more frequently observed than B-cells and exhibited plasma cell and plasmablast morphology (Fig. 1F). In type 1 reaction samples

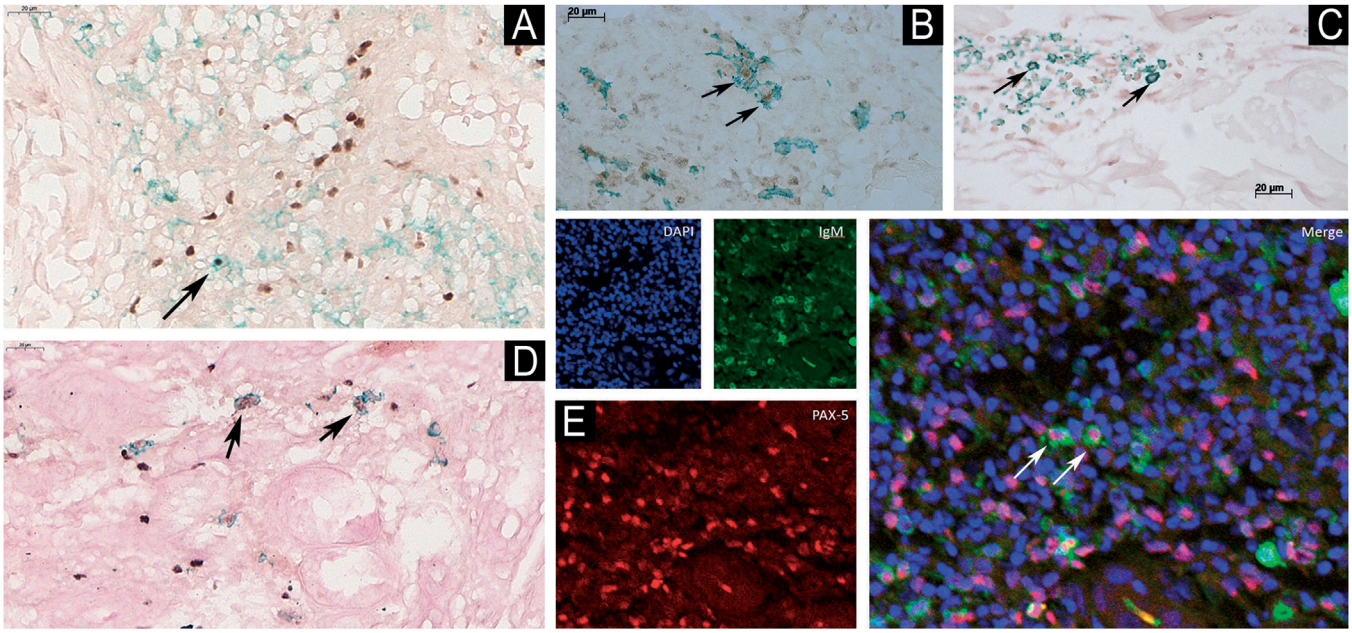

Fig. 3 B1-cells (PAX5+/CD5+) in tuberculoid leprosy (A); Be1-cell (CD20+/Tbet+) in type 1 reaction (B); Breg cell (CD20+/c-MAF+) in type 1 reaction (C); B1 and MZB cells (PAX5+/MZB1+) in tuberculoid leprosy (D), double immunolabeling technique using diaminobenzidine chromogen (brown) for PAX5 and T-bet and PermaGreen (green) for CD20 antibody; B1-cell (PAX5+/IgM+) in laser confocal microscopy in type 1 reaction (E). Arrows indicate the respective cells. Scale bars – indicate the magnification.

MZB-1-positive cells were distributed in the papillary dermis and, in some cases, they were scarce or even absent around granulomas (Fig. 2C) contrary to what was observed in tuberculoid leprosy samples. Type 2 reaction samples displayed MZB-1-positive cells forming small clusters, and like lepromatous leprosy samples, they showed a morphological appearance of plasma cells (Fig. 2D).

Given that the MZB-1 antibody reveals the MZB-1 protein, associated with the processing and secretion of immunoglobulins and present in the endoplasmic reticulum of B-cells in the marginal zone of lymphoid follicles, plasmablasts, and plasma cells,[20] the authors decided to compare the mean expression area fraction of CD20 (B-cell marker) with the mean expression area fraction of MZB-1 in each leprosy group. That was an attempt to ascertain whether MZB-1 expression was solely attributable to the presence of plasmablasts and plasma cells in the tissue response of the studied samples. Table 1S in Supplementary materials demonstrates the statistical analysis results of these comparisons.

Presence and distribution of double-labeled cells

The authors observed a sparse presence of double-labeled cells in all evaluated B-cell subpopulations. Fig. 3 (A, B, C, and D) illustrates some of these cases, contrasting with the infiltrates shown previously for CD20 mainly in tuberculoid and type 1 leprosy reaction samples. In addition, slide reading using the Confocal Immunofluorescence Microscopy technique revealed the presence of PAX5/IgM (B1-cells) in cases of T1R (Fig. 3E).

Morphometric and statistical analyses

The mean rank differences observed in Dunn's multiple comparisons test delineate distinctions in the ratio of double-labeled positive cells in comparison to single-positive PAX5 or CD20 cells per unit area among distinct leprosy groups. The differences in medians between groups with statistically significant comparisons are summarized in Table 2, along with their respective p-values. Fig. 4 displays the medians for all groups in graphical form, along with their corresponding measures of central dispersion.

Discussion

The present study observed a higher area fraction of CD20+ cells (B-cells) in the tuberculoid pole of leprosy compared to the lepromatous pole, which is consistent with recent literature findings.[25,26] The lepromatous leprosy group, however, exhibited a lower B-cell component compared to the reactional groups, both Type 1 (T1R) and Type 2 (T2R).

The involvement of B-cells in mycobacterial infections has been discussed in the literature, particularly in the context of granuloma formation, cytokine production, T-cell responses, and antigen presentation.[27] This could explain the higher expression of CD20 and the presence of B-cells in the granulomatous response group, aligning with literature data. Interestingly, this study demonstrated that reactional states (T1R and T2R) exhibited a higher population of B-cells compared to the lepromatous group. In T1R, this could be related to the better organization of the granulomatous response. In T2R, however, these findings differ from those reported by Biswas et al.,[25] who found fewer B-lymphocytes

Table 2 Differences in medians between the groups with statistically significant comparisons and their respective p-values.

CD20		
Dunn's multiple comparisons test	Mean rank difference	Adjusted p-value
LT vs. LL	51.82	<0.0001
LT vs. I	58.67	<0.0001
LT vs. Controls	48.57	0.0002
LL vs. T1R	-41.31	0.0004
LL vs. T2R	-37.8	0.0016
I vs. T1R	-48.17	<0.0001
I vs. T2R	-44.66	0.0002
T1R vs. Controls	38.07	0.0145
T2R vs. Controls	34.56	0.0374
MZB-1		
Dunn's multiple comparisons test	Mean rank difference	Adjusted p-value
TT vs. I	35.07	0.0006
LL vs. I	36.58	0.0007
I vs. T1R	-32.17	0.0066
PAX5/CD5		
Dunn's multiple comparisons test	Mean rank difference	Adjusted p-value
LL vs. T1R	-22.93	0.0245
I vs. T1R	-30.86	0.0024
T1R vs. T2R	30.17	0.0005
CD20/Tbet		
Dunn's multiple comparisons test	Mean rank difference	Adjusted p-value
TT vs. I	27.33	0.0055
TT vs. T2R	22.86	0.0123
I vs. T1R	-27.29	0.0096
T1R vs. T2R	22.82	0.0227
CD20/c-Maf		
Dunn's multiple comparisons test	Mean rank difference	Adjusted p-value
I vs. T1R	-15.74	0.0373
PAX5/MZB-1		
Dunn's multiple comparisons test	Mean rank difference	Adjusted p-value
TT vs. T1R	-31.18	<0.0001
LL vs. T1R	-37.5	<0.0001
I vs. T1R	-37.5	<0.0001
T1R vs. T2R	35.53	<0.0001

LT, tuberculoid form; I, indeterminate form; LL, lepromatous form; T2R, Type 2 leprosy Reaction; T1R, Type 1 leprosy Reaction.

in T2R compared to multibacillary leprosy. These authors correlated the presence of B-lymphocytes in T2R with poorly formed granulomas, which might not fully align with the present observations.

Lesions from indeterminate leprosy demonstrated lower B-cell expression compared to the tuberculoid group and the reactional groups (T1R and T2R). This might be due to the less intense inflammatory response or the undefined polarization of this group.

The MZB-1 molecule, encoded by the MZB-1 gene, is present in the endoplasmic reticulum and functions as a chaperone involved in the folding and secretion of Immunoglobulin M (IgM). MZB-1 is a marker for B-lymphocytes, particularly B1-cells, Marginal Zone-B (MZB) cells, plasmablasts, and plasma cells.[28] B1-cells are known for secreting IgM, characterizing them as part of the early humoral immune response. The authors chose this marker to demonstrate the presence or absence of this B-lymphocyte

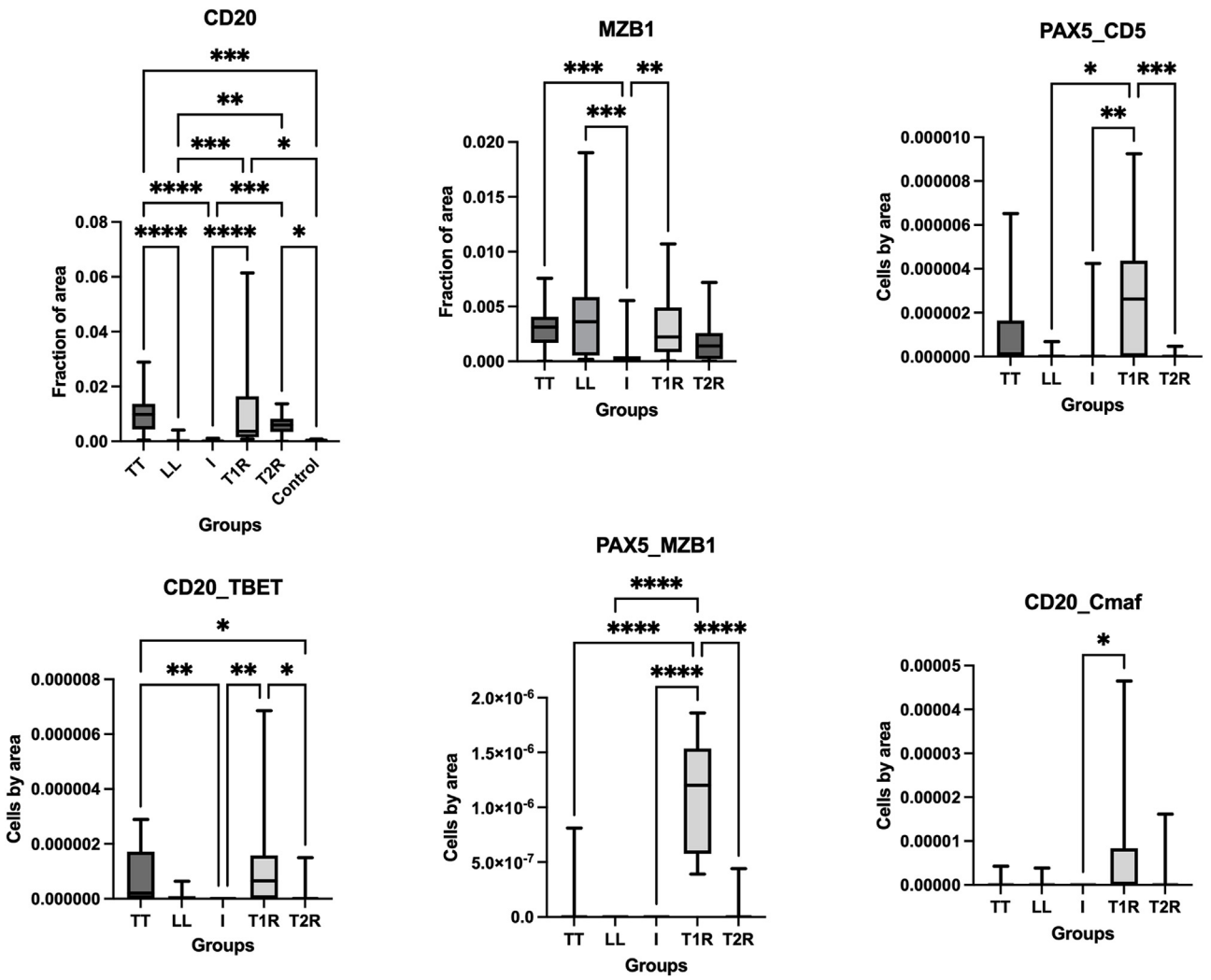

Fig. 4 Medians for all groups in graphical form, along with their corresponding measures of central dispersion. The asterisks indicate statistically significant post hoc comparisons. LT, tuberculoid leprosy; I, indeterminate leprosy; LL, lepromatous leprosy; T1R, Type 1 leprosy Reaction; T2R, Type 2 leprosy Reaction.

subtype in leprosy lesions. However, the authors could demonstrate the expression of IgM in PAX5-positive cells (B-cells) only through immunofluorescence and confocal microscopy, as the results obtained by immunoenzymatic techniques were unsatisfactory.

MZB-cells, like B1-cells, are part of the innate immune response and play essential roles in the early stages of humoral immune responses.[28] MZB-cells reside in lymphoid follicles, particularly in the spleen, and efficiently transport antigens from the blood to the follicles, where they activate CD4+ T-cells and induce the differentiation of B-cells into plasma cells.[29] In the present sample, MZB-1 expression was higher in tuberculoid leprosy than in the indeterminate form. Interestingly, MZB-cells expressing MZB-1 correlate with a higher number of infiltrating CD8+ T-lymphocytes in the tumor environment of pancreatic carcinoma and are associated with a better prognosis for this neoplasm.[20]

Analyzing the expression of CD20 and MZB-1 in the studied groups, the authors found that in the Tuberculoid (TT) leprosy group, CD20 expression was higher than that of MZB-1. This is probably because MZB-1 stains B1/MZB/plasma cells, and plasma cells are strongly associated with the Th2 (humoral) response in leprosy, which is scarce in the Th1 pole.[25,26] In addition, the authors observed that, in double-labeling techniques, MZB and B1-cells were much scarcer than CD20-positive cells in all groups of patients, including TT.

On the other hand, in the lepromatous group (LL), CD20 expression was lower than that of MZB-1. In LL, the plasma cell component is significant, and in this context, the MZB-1 antibody would reveal plasma cells. The scarcity of double-stained B1 and MZB cells in LL and T2R samples supports the hypothesis that the MZB-1 antibody displayed mainly plasma cells rather than B-1/MZ B-cells.

In the type 2 reaction, the authors observed a higher expression of CD20 compared to MZB-1 expression. Given this finding, the authors can propose a similar hypothesis as in the case of the TT group: B1/MZB-cells were also limited in T2R, and existing literature does not indicate an abundance of plasma cells in T2R.[25,26]

There was no significant difference in the indeterminate (I) leprosy group regarding the expression of the two markers, possibly due to the scarcity or absence of inflammatory cells.

There was also no difference in the expression of CD20 and MZB-1 in T1R. Considering that plasmablasts and plasma cells are recognized to be infrequent in T1R,[25,26] the few cells that exhibited MZB-1 immunostaining are likely MZB-cells or B1-cells. The most robust double-labeling for B1 and MZB-cells was observed in T1R lesions. In employing the PAX5/MZB-1 co-localization, the authors excluded plasmablasts and plasma cells, thereby restricting the labeling to B1/MZB-cells.

Interestingly, the disparity between the T1R, T2R, LL, I, and TT groups in PAX5/MZB-1 (B1 and MZB-cells) closely paralleled that observed in PAX5/CD5 (specifically marking B1-cells), suggesting that PAX5/MZB-1 did not display a substantial number of MZB-cells. For both markers (PAX5/MZB-1 and PAX5/CD5), T1R exhibited significantly more cells than T2R, LL, and I. However, uniquely in PAX5/MZB-1, the authors observed a significantly higher cell count in T1R than in TT. Since this discrepancy was not observed in the PAX5/CD5 labeling (B1-cells), the authors attribute it to a difference in the number of MZB-cells, which may be lower in the TT group.

While the authors did not observe a significant number of B1-cells in the lepromatous group, Kotb et al.,[30] using peripheral blood flow cytometry, reported a higher percentage of these cells in lepromatous leprosy patients compared to healthy controls. They also associated the presence of B1-cells with autoimmune phenomena in the patient group.

The number of B-effector-1 cells (Be1) was higher in T1R and TT than in the I and T2R groups. The association of Be1-cells with a Th1 response makes this outcome expected. While not achieving statistical significance, LL showed a lower count of Be1-cells compared to TT and T1R, further reinforcing the connection of Be1-cells with the Th1 response in leprosy. Lund and colleagues demonstrated that Th1-cells, specifically those producing IFN-γ or stimulated by IL-12, induce the polarization of B-cells into Be1, leading to the expression of pro-inflammatory cytokines such as IFN-γ and IL-12.[15] Conversely, interaction with Th2 cells or exposure to IL-4 directs B-cells, termed Be2, to produce IL-2 and IL-4. Be1 and Be2 cells, in turn, play roles in promoting the in vitro differentiation of Th1 and Th2 cells, respectively.[16,31] Subsequently, it was revealed that B-cell-derived IFN-γ plays a crucial role in Th1 responses, contributing to allograft and tumor rejection, autoimmune arthritis, and antibacterial response.[32–34]

Regulatory B-cells (Bregs) were notably scarce across all leprosy groups studied, with significant differences observed only between the T1R and I groups. It is important to note that, as mentioned earlier, MZB and B1-cells are subtypes of innate B-regulatory cells. However, the number of MZB and B1-cells was higher than that of Bregs. This apparent paradox may be attributed to the fact that the authors identified B regulatory cells based only on the expression of the IL-10 transcription factor c-MAF.

The predominance of Bregs in the Th1 pole aligns with prior studies that have highlighted the protective role of Bregs in various autoimmune diseases such as multiple sclerosis, systemic lupus erythematosus, rheumatoid arthritis, type 1 diabetes mellitus, and inflammatory bowel disease, all of which are associated with Th1 or Th17 cells.[35] Additionally, Bregs have been implicated in tumor immunology exerting their immunosuppressive properties within the tumor microenvironment.[36]

Considering that this study, although it involved a large number of samples, is retrospective and relies on immunohistochemical techniques for identifying B lymphocyte subtypes, the authors have been able to demonstrate and compare the presence of these B-cell subsets across various leprosy lesion sites and reactional states. While there are limitations to this approach, these findings suggest distinct roles for these B lymphocytes, particularly within the tuberculoid pole and Type 1 leprosy reactions.

Editor

Sílvio Alencar Marques.

Research data availability

The entire dataset supporting the results of this study was published in this article.

Financial support

None declared.

Authors' contributions

Luis Alberto Ribeiro Fróes:

Conceptualization, Data curation, Formal analysis, Investigation, Methodology, Visualization, Writing - original draft.

Carla Pagliari:

Data curation, Investigation.

Maria Angela Bianconcini Trindade:

Data curation, Investigation, Methodology, Supervision, Writing - review & editing.

Mirian Nacagami Sotto:

Conceptualization, Data curation, Investigation, Funding acquisition, Methodology, Project administration, Supervision, Validation, Writing - review & editing.

Conflicts of interest

None declared.

Acknowledgments

The authors are grateful for the financial support from Fundo de Apoio à Dermatologia de São Paulo – Sebastião Sampaio (FUNADERSP) and the National Research Council (CNPq, Conselho Nacional de Pesquisas) process nº 306371/2018-9.

Appendix A. Supplementary material

Supplementary material related to this article can be found, in the online version, at doi:https://doi.org/10.1016/j.abd.2025.501184.

References

1. Froes LAR, Sotto MN, Trindade MAB. Leprosy: clinical and immunopathological characteristics. An Bras Dermatol. 2022;97:338–47.
2. Froes LAR, Trindade MAB, Sotto MN. Immunology of leprosy. Int Rev Immunol. 2022;41:72–83.
3. Moura DF, de Mattos KA, Amadeu TP, Andrade PR, Sales JS, Schmitz V, et al. CD163 favors *Mycobacterium leprae* survival and persistence by promoting anti-inflammatory pathways in lepromatous macrophages. Eur J Immunol. 2012;42:2925–36.
4. Modlin RL. Th1-Th2 paradigm: insights from leprosy. J Invest Dermatol. 1994;102:828–32.
5. Ridley DS. Histological classification and the immunological spectrum of leprosy. Bull World Health Organ. 1974;51:451–65.
6. Fachin LR, Soares CT, Belone AF, Trombone APF, Rosa PS, Guidella CC, et al. Immunohistochemical assessment of cell populations in leprosy-spectrum lesions and reactional forms. Histol Histopathol. 2017;32:385–96.
7. Debes GF, McGettigan SE. Skin-associated B cells in health and inflammation. J Immunol. 2019;202:1659–66.
8. Prieto JMB, Felippe MJB. Development, phenotype, and function of non-conventional B cells. Comp Immunol Microbiol Infect Dis. 2017;54:38–44.
9. Somekh E, Serour F, Gorenstein A, Vohl M, Lehman D. Phenotypic pattern of B-cells in the appendix: reduced intensity of CD19 expression. Immunobiology. 2000;201:461–9.
10. Baumgarth N. The double life of a B1-cell: self-reactivity selects for protective effector functions. Nat Rev Immunol. 2011;11:34–46.
11. Kageyama Y, Katayama N. Ontogeny of human B1-cells. Int J Hematol. 2020;111:628–33.
12. Youinou P, Jamin C, Lydyard PM. CD5 expression in human B-cell populations. Immunol Today. 1999;20:312–6.
13. Cerutti A, Cols M, Puga I. Marginal zone B-cells: virtues of innate-like antibody-producing lymphocytes. Nat Rev Immunol. 2013;13:118–32.
14. Blair PA, Chavez-Rueda KA, Evans JG, Shlomchik MJ, Eddaoudi A, Isenberg DA, et al. Selective targeting of B cells with agonistic anti-CD40 is an efficacious strategy for the generation of induced regulatory T2-like B-cells and for the suppression of lupus in MRL/lpr mice. J Immunol. 2009;182:3492–502.
15. Lund FE, Randall TD. Effector and regulatory B-cells: modulators of CD4+ T-cell immunity. Nat Rev Immunol. 2010;10:236–47.
16. Harris DP, Haynes L, Sayles PC, Duso DK, Eaton SM, Lepak NM, et al. Reciprocal regulation of polarized cytokine production by effector B and T cells. Nat Immunol. 2000;1:475–82.
17. Bao Y, Liu X, Han C, Xu S, Xie B, Zhang Q, et al. Identification of IFN-γ-producing innate B cells. Cell Res. 2014;24:161–76.
18. Harris DP, Goodrich S, Gerth AJ, Peng SL, Lund FE. Regulation of IFN-gamma production by B effector 1 cells: essential roles for T-bet and the IFN-gamma receptor. J Immunol. 2005;174:6781–90.
19. Durali D, de Goër de Herve MG, Giron-Michel J, Azzarone B, Delfraissy JF, Taoufik Y. In human B-cells, IL-12 triggers a cascade of molecular events similar to Th1 commitment. Blood. 2003;102:4084–9.
20. Miyake K, Mori R, Homma Y, Matsuyama R, Okayama A, Murakami T, et al. MZB1 in borderline resectable pancreatic cancer resected after neoadjuvant chemoradiotherapy. J Surg Res. 2017;220:391–401.
21. Johanson TM, Lun ATL, Coughlan HD, Tan T, Smyth GK, Nutt SL, et al. Transcription-factor-mediated supervision of global genome architecture maintains B cell identity. Nat Immunol. 2018;19:1257–64.
22. Tudor CS, Distel LV, Eckhardt J, Hartmann A, Niedobitek G, Buettner M. B cells in classical Hodgkin lymphoma are important actors rather than bystanders in the local immune reaction. Hum Pathol. 2013;44:2475–86.
23. Liu M, Zhao X, Ma Y, Zhou Y, Deng M, Ma Y. Transcription factor c-Maf is essential for IL-10 gene expression in B cells. Scand J Immunol. 2018;88:e12701.
24. Michée-Cospolite M, Boudigou M, Grasseau A, Simon Q, Mignen O, Pers JO, et al. Molecular mechanisms driving IL-10- producing B cells functions: STAT3 and c-MAF as underestimated central key regulators? Front Immunol. 2022;13:818814.
25. Biswas D, Sethy M, Behera B, Palit A, Mitra S. Image morphometric analysis of B cells and plasma cells in Erythema nodosum leprosum with clinicopathological correlation. Am J Dermatopathol. 2021;43:700–6.
26. Fabel A, Brunasso AMG, Schettini AP, Cota C, Puntoni M, Nunzi E, et al. Pathogenesis of leprosy: an insight into B lymphocytes and plasma cells. Am J Dermatopathol. 2019;41:422–7.
27. Maglione PJ, Chan J. How B cells shape the immune response against *Mycobacterium tuberculosis*. Eur J Immunol. 2009;39:676–86.
28. Miyagawa-Hayashino A, Yoshifuji H, Kitagori K, Ito S, Oku T, Hirayama Y, et al. Increase of MZB1 in B cells in systemic lupus erythematosus: proteomic analysis of biopsied lymph nodes. Arthritis Res Ther. 2018;20:13.
29. Zouali M, Richard Y. Marginal zone B-cells, a gatekeeper of innate immunity. Front Immunol. 2011;2:63.
30. Kotb A, Ismail S, Kimito I, Mohamed W, Salman A, Mohammed AA. Increased CD5+ B-cells are associated with autoimmune phenomena in lepromatous leprosy patients. J Infect Public Health. 2019;12:656–9.
31. Harris DP, Goodrich S, Mohrs K, Mohrs M, Lund FE. Cutting edge: the development of IL-4-producing B cells (B effector 2 cells) is controlled by IL-4, IL-4 receptor alpha, and Th2 cells. J Immunol. 2005;175:7103–7.
32. Barr TA, Shen P, Brown S, Lampropoulou V, Roch T, Lawrie S, et al. B cell depletion therapy ameliorates autoimmune disease through ablation of IL-6-producing B-cells. J Exp Med. 2012;209:1001–10.
33. Olalekan SA, Cao Y, Hamel KM, Finnegan A. B cells expressing IFN-γ suppress Treg-cell differentiation and promote autoimmune experimental arthritis. Eur J Immunol. 2015;45:988–98.
34. Ding Q, Mohib K, Kuchroo VK, Rothstein DM. TIM-4 identifies IFN-γ-expressing proinflammatory B effector 1 cells that promote tumor and allograft rejection. J Immunol. 2017;199:2585–95.
35. Catalán D, Mansilla MA, Ferrier A, Soto L, Oleinika K, Aguillón JC, et al. Immunosuppressive mechanisms of regulatory B cells. Front Immunol. 2021;12:611795.
36. Schioppa T, Moore R, Thompson RG, Rosser EC, Kulbe H, Nedospasov S, et al. B regulatory cells and the tumor-promoting actions of TNF-α during squamous carcinogenesis. Proc Natl Acad Sci U S A. 2011;108:10662–7.

SOCIEDADE BRASILEIRA DE DERMATOLOGIA

Anais Brasileiros de Dermatologia

www.anaisdedermatologia.org.br

ORIGINAL ARTICLE

Bullous pemphigoid: epidemiological, clinical, and therapeutic analysis of 189 patients in a tertiary center in Brazil☆

Cecília Mirelle Almeida Honorato *, Claudia Giuli Santi, Celina Wakisaka Maruta, Valeria Aoki, Denise Miyamoto

Department of Dermatology, Faculty of Medicine, Clinical Hospital, Universidade de São Paulo, São Paulo, SP, Brazil

Received 12 August 2024; accepted 21 November 2024
Available online 18 July 2025

KEYWORDS
Autoimmune diseases;
Brazil;
Bullous pemphigoid

Abstract

Background: Bullous pemphigoid (BP) is the most prevalent autoimmune bullous dermatosis with increasing incidence globally. There is a lack of literature on BP in the multiethnic Brazilian population.

Objectives: To assess the epidemiological, clinical, and therapeutic characteristics of BP patients in a tertiary center in Brazil.

Methods: Retrospective longitudinal review of clinical records of 189 BP patients from January 1986 to September 2023.

Results: BP primarily affected elderly individuals, predominantly females, with an average onset of symptoms at 65.7-years. Non-bullous presentations had a longer time to diagnose compared to the bullous form. Mucosal involvement was observed in 24.9% of patients. Subepidermal blistering was the predominant histopathological feature. Most cases presented fluorescence of IgG and C3 at the basement membrane zone (BMZ) on direct immunofluorescence. Indirect immunofluorescence mainly revealed fluorescence of IgG along the BMZ, and with salt-split skin technique demonstrated predominantly IgG fluorescence on the epidermal side of the cleavage. Eosinophilia, elevated IgE levels, and D-dimer were common. Systemic corticosteroids remained the mainstay of treatment. BP was associated with significant complications, including thromboembolism, hospitalization, and infections, along with numerous comorbidities and a notable percentage (10.6%) of patients using potentially BP-inducing medications.

Study limitations: The study's limitations include its retrospective design, reliance on potentially incomplete clinical records, and findings of a single tertiary center.

☆ Study conducted at the Department of Dermatology, Faculty of Medicine, Clinical Hospital, Universidade de São Paulo, São Paulo, SP, Brazil.

* Corresponding author.
E-mail: draceciliahonorato@gmail.com (C.M. Honorato).

https://doi.org/10.1016/j.abd.2025.501163

Conclusions: This study provides crucial insights into the multifaceted nature of BP in the Brazilian population, emphasizing the need for comprehensive management strategies to address its diverse complications and associated conditions.

Introduction

Bullous pemphigoid (BP) is the most common autoimmune bullous dermatosis, mainly affecting elderly individuals over 70-years of age. There has been a significant increase in incidence over the last two decades due to population aging, earlier recognition of non-bullous forms of the disease, and increased availability of diagnostic methods. BP results from the production of autoantibodies against the hemidesmosomal antigens BP-180 and BP-230, which are components of the basement membrane zone (BMZ). The subsequent loss of adhesion between the epidermis and dermis leads to a subepidermal detachment resulting in tense blisters. This clinical presentation is classified as bullous or classic BP. However, other forms of the disease have been described, such as lichen planus pemphigoid and even non-bullous forms of BP, including prurigo-like, eczematous, dyshidrosiform, urticariform, and erythroderma.[1,2] Fig. 1 shows the clinical manifestations of classic BP and non-bullous forms, including eczematous, prurigo-like, and urticariform presentations.

There is a paucity of literature on BP in Brazil, a multiethnic country with an aging population. To our knowledge, this is the first study on the profile of BP patients in Brazil with a 37-year follow-up. The aim of the present study is to retrospectively evaluate the epidemiological, clinical, and therapeutic profiles of patients with BP followed at the Department of Dermatology, Hospital das Clinicas HCFMUSP, Faculdade de Medicina, Universidade de São Paulo, Brazil.

Methods

This retrospective, longitudinal, and descriptive study included patients evaluated from January 1986 to September 2023 at the Department of Dermatology, Hospital das Clinicas HCFMUSP, Faculty of Medicine, Universidade de Sao Paulo, Brazil. After ethics committee approval (CAAE #63382922.2.0000.0068), patients with BP confirmed

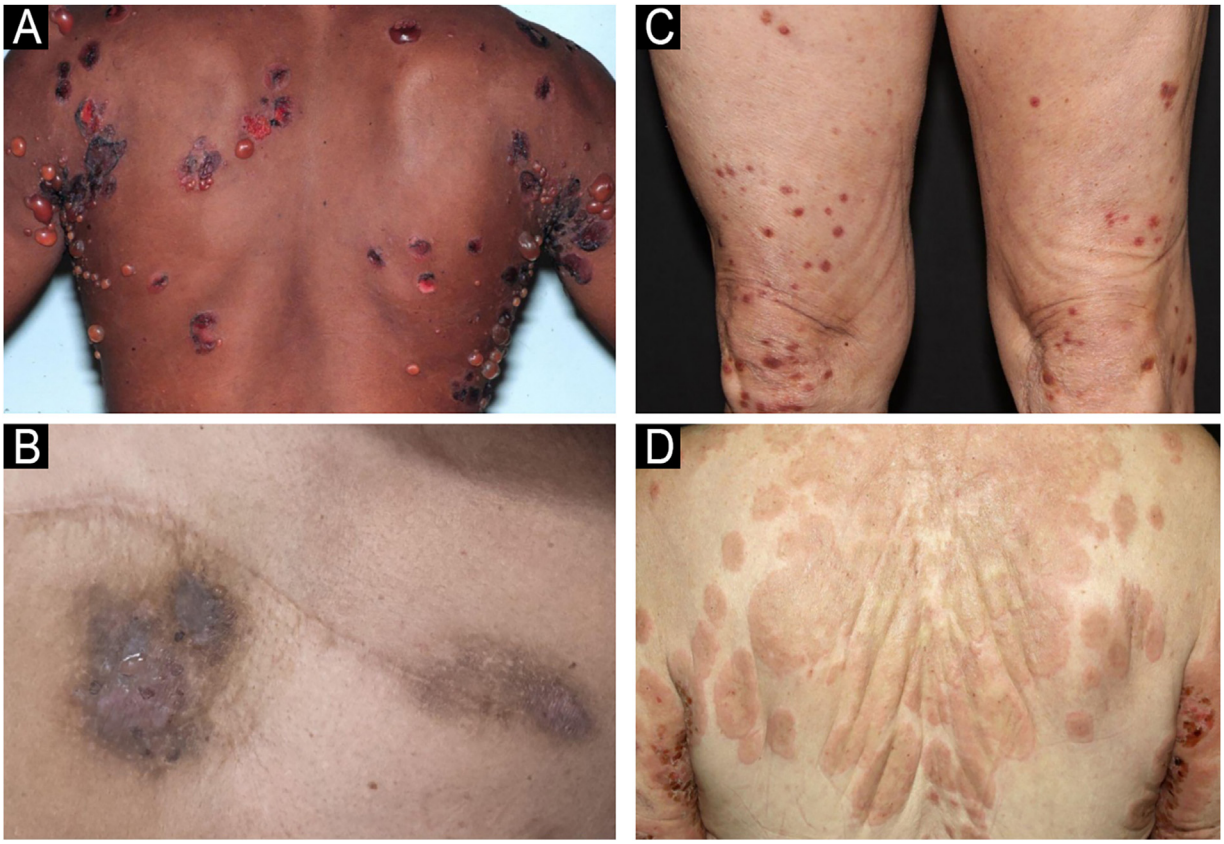

Figure 1 Clinical manifestations of classic BP with tense blisters (A) and non-bullous BP forms, including eczematous (B), prurigo-like (C), and urticariform (D).

Table 1 Main epidemiological and clinical aspects of the studied cases of BP.

Subjects (n)		189
Mean follow-up time (months), ± standard deviation		55.0 (0.3 to 448)
Sex	Female	62.4% (118/189)
	Male	37.6% (71/189)
Race/Ethnics	White	85.2% (161/189)
	Multiracial	7.9% (15/189)
	Asian	3.7% (7/189)
	Black	2.1% (4/189)
	Not specified	1.0% (2/189)
Mean age of onset (years), ± standard deviation		65.7 (0.2 to 93)
Mean time to diagnosis (months), ± standard deviation	Overall	9.3 (0.2 to 221)
	Classic BP	6.5 (0.2 to 120)
	Non-bullous BP	43.4 (1 to 221)
Clinical presentation at initial assessment	Bullous	88.3% (167/189)
	Non-bullous	7.9% (15/189)
	Eczematous	40.0% (6/15)
	Prurigo-like	26.7% (4/15)
	Urticariform	13.3% (2/15)
	Erythroderma	13.3% (2/15)
	Dyshidrosiform	6.7% (1/15)
	Lichen planus pemphigoid	0.5% (1/189)
	No active lesions	2.1% (4/189)
	Not specified	1.0% (2/189)
Mucosal involvement	Total of patients with mucosal involvement	24.9% (47/189)
	Oral	95.7% (45/47)
	Nasal	10.6% (5/47)
	Larynx	8.5% (4/47)
	Esophageal	2.1% (1/47)
	Pharynx	2.1% (1/47)
	Conjunctival	2.1% (1/47)
Pruritus	Present	70.4% (133/189)
	Absent	0.0% (0/189)
	Not specified	29.6% (56/189)
Main diagnostic hypotheses at initial assessment	Bullous pemphigoid	85.2% (161/189)
	Acquired epidermolysis bullosa	29.1% (55/189)
	Linear IgA bullous dermatosis	14.8% (28/189)
	Dermatitis herpetiformis	10.6% (20/189)
Potential BP-inducing medications	Percentage of patients in use of one of them	10.6% (20/189)
	Aldosterone antagonists	3.2% (6/189)
	Dipeptidyl peptidase 4 inhibitors	3.2% (6/189)
	Anticholinergics	2.6% (5/189)
	Dopaminergic medications	1.6% (3/189)
Complications	Hospitalization rate	55.0% (104/189)
	Venous thromboembolism	7.9% (15/189)
	Secondary bacterial infection (at least 1 episode)	62.4% (118/189)
Death	Infections	66.7% (10/15)
	Complications associated with neoplasms	13.3% (2/15)
	Others (complications from an epigastric hernia, acute pulmonary edema, and myocardial infarction)	20.0% (3/15)

according to the following diagnostic criteria were included: compatible (1) clinical and (2) histopathological features, and the (3) presence of IgG and/or C3 at the BMZ demonstrated by Direct Immunofluorescence (DIF) and/or Indirect Immunofluorescence (IIF) with IgG deposits at the BMZ, and IIF with Salt-Split Skin (SSS) technique with IgG on the epidermal or epidermal and dermal side of the cleavage.

Medical records were reviewed to gather data on epidemiology, clinical presentation, comorbidities, histopathological and immunofluorescence findings, treatments admin-

istered, and complications. Patients with incomplete medical records that hindered the collection of important research data were excluded.

Results

A total of 189 patients were included in the study, with a mean follow-up of 55-months. There was a female predominance (62.4%) and the majority of patients were White (85.2%). The mean age at onset of symptoms was 65.7-years, and the overall mean time to diagnosis was 9.3-months (6.5-months for bullous BP vs. 43.4-months for non-bullous BP). Two cases began during pregnancy.

BP with blisters was the most common initial presentation (88.3%), followed by the non-bullous forms (7.9%), among which 46.7% developed blisters after an average of 31.6-months. Mucosal involvement occurred in 24.9% of the patients, predominantly affecting the oral mucosa (95.7%). BP was one of the initial diagnostic hypotheses in 85.2% of cases, and the main differential diagnoses – acquired epidermolysis bullosa (29.1%); linear IgA bullous dermatosis (14.8%); dermatitis herpetiformis (10.6%) – were ruled out according to the immunofluorescence studies.

Cardiovascular and metabolic comorbidities were present in 77.8% of the patients, followed by neuropsychiatric conditions (25.4%), other autoimmune and inflammatory diseases (24.9%) and malignancies (23.3%). Potentially BP-inducing medications were observed in 10.6% cases: aldosterone antagonists (3.2%), Dipeptidyl Peptidase 4 (DDP4) inhibitors (3.2%), anticholinergics (2.6%), and dopaminergic medications (1.6%).

The main histopathological characteristics observed were subepidermal blistering (88.0%), eosinophilic spongiosis (6.0%), presence of eosinophils (52.2%), both eosinophils and neutrophils (35.3%), and exclusively neutrophils (4.9%). Major DIF findings included immune complex deposition at the BMZ with both IgG and C3 (73.8%), only C3 (20.8%) or IgG (5.5%). IIF with the SSS technique demonstrated IgG fluorescence on the epidermal side of the cleavage (81.9%) or both on the epidermal and dermal sides (4.0%). Additional assessment of the patients revealed elevated serum IgE levels (47/63; 74.6%), eosinophilia (91/87; 48.7%), and increased D-dimer levels (26/28; 92.8%).

Systemic treatment was the mainstay of therapy, with the use of corticosteroids (82.5%), doxycycline/tetracycline (44.9%), immunosuppressants (22.7%); dapsone (17.5%), rituximab (2.1%) and plasmapheresis (0.5%). Exclusive topical corticosteroid was used in 6.9% of patients and one patient experienced spontaneous remission. Data from the last consultation revealed that 40.7% of patients were in complete remission with therapy, and 30.7% were in complete remission off therapy. Partial remission with medication was observed in 22.2% of patients, and 5.8% experienced recurrence (>3-lesions lasting $\geq$7-days).

Venous thromboembolic events occurred in 7.9% of patients including deep vein thrombosis (72.2%), pulmonary embolism (22.2%) and portal vein thrombosis (5.5%). Secondary bacterial infection was experienced by 62.4% of patients. Hospitalization was required by 55.0% of patients either due to disease severity or infectious complications.

Data from 15 deaths was available, with infection as the leading cause (40.0%) followed by complications related to neoplasms (13.3%). The average disease duration at the time of the patient's death was 37.5-months. The main characteristics of the studied cases are described in Tables 1–4 .

Table 2 Comorbidities presented by the patients.

Cardiovascular and metabolic diseases	77.8% (147/189)
Systemic arterial hypertension	63.5% (120/189)
Diabetes mellitus	38.6% (73/189)
Dyslipidemia	26.4% (50/189)
Osteoporosis	20.6% (39/189)
Chronic kidney disease	10.0% (19/189)
Congestive heart failure	9.5% (18/189)
Coronary artery disease	9.0% (17/189)
Arrhythmia	7.9% (15/189)
Gout	1.6% (3/189)
Neurologic and psychiatric diseases	25.4% (48/189)
Cerebrovascular disease	12.2% (23/189)
Dementia	9.5% (18/189)
Alzheimer's disease	4.8% (9/189)
Vascular dementia:	0.5% (1/189)
Mixed dementia	0.5% (1/189)
Unknown cause	3.7% (7/189)
Depression	6.9% (13/189)
Anxiety	3.2% (6/189)
Epilepsy	2.6% (5/189)
Parkinson's disease	2.6% (5/189)
Schizophrenia	1.6% (3/189)
Intellectual disorder	1.0% (2/189)
Bipolar affective disorder	0.5% (1/189)
Personality disorder	0.5% (1/189)
Malignancies	23.3% (44/189)
Skin	7.4% (14/189)
Basal cell carcinoma	5.3% (10/189)
Squamous cell carcinoma	3.2% (6/189)
Mycosis fungoides	0.5% (1/189)
Not specified	1.0% (2/189)
Prostate	3.2% (6/189)
Breast	2.6% (5/189)
Hematological	2.6% (5/189)[a]
Oral	1.0% (2/189)
Ovary	1.0% (2/189)
Stomach	1.0% (2/189)
Rectum	1.0% (2/189)
Others	5.3% (10/189)[b]
Autoimmune and inflammatory diseases	24.9% (47/189)
Hypothyroidism	11.1% (21/189)
Rheumatoid arthritis	5.8% (11/189)
Asthma	4.2% (8/189)
Psoriasis	1.6% (3/189)
Lupus erythematosus	1.0% (2/189)[c]
Allergic rhinitis	1.0% (2/189)
Psoriatic arthritis	0.5% (1/189)
Atopic dermatitis	0.5% (1/189)
Inflammatory bowel disease	0.5% (1/189)
Vitiligo	0.5% (1/189)
Lichen sclerosus	0.5% (1/189)

Table 2 (*Continued*)

Others	
Immunosuppressive conditions	1.6% (3/189)
Renal transplant	0.5% (1/189)
Liver transplant	0.5% (1/189)
Common variable immunodeficiency	0.5% (1/189)
Ophthalmological	7.9% (15/189)
Cataract	4.8% (9/189)
Glaucoma	4.2% (8/189)
Infectious diseases	3.2% (6/189)
Hepatitis B	1.0% (2/189)
Hepatitis C	1.0% (2/189)
HIV	0.5% (1/189)
Tuberculosis	0.5% (1/189)

[a] Including myelodysplastic syndrome, multiple myeloma, myelofibrosis, lymphoma, and not specified (1-patient each).
[b] Including vulva, kidney, larynx, liver, lung, bladder, endometrium, intestine, brain, and not specified (1-patient each).
[c] Including one case of systemic lupus erythematosus and one case of discoid lupus.

Discussion

BP is the most common autoimmune blistering dermatosis, primarily affecting individuals of white race over 70-years of age, with no gender predilection.[2] In this case series, the disease primarily affected elderly individuals with a mean age of symptom onset of 65.7-years, mostly white (85.2%), and with a slight female predominance (62.4%). As a referral center, this case series included five rare cases of children with BP, which may have slightly lowered the average age. Notably, the ethnic composition of the sample contrasts with the 2022 Census data,[3] where only 43.5% of the population self-identified as white. As this is a single-center study, this limitation may have contributed to the observed differences, reflecting regional characteristics and healthcare access disparities.

The overall average time for diagnosing BP was 9.3-months, longer in non-bullous than in bullous forms, which may occur because the absence of blisters can pose a challenge for clinicians in recognizing this condition.[1] It is important to mention that patients referred to the tertiary center often have a history of multiple consultations in different healthcare facilities, leading to a delayed diagnosis. Notably, 46.7% of patients with non-bullous BP developed blisters after a mean of 31.6-months, a higher proportion than previously reported,[1] likely due to the extended follow-up (mean of 55.0-months).

In the present study, mucosal involvement was observed in 24.9% of patients (within the reported range of 10%–30%),[1,2,4] primarily in the oral mucosa, and was associated with classic BP and increased severity of cutaneous disease. Pruritus was a common symptom, highlighting the importance of considering BP as a potential differential diagnosis for chronic pruritus in elderly patients.[1,2] BP was one of the initial diagnostic hypotheses in 85.2% of cases, with the main differential diagnoses being other subepidermal blistering dermatoses.

Table 3 Main laboratory findings of the studied cases of BP.

Histopathological findings	
Subepidermal blistering	88.0% (162/184)
Eosinophilic spongiosis	6.0% (11/184)
Intraepidermal blistering	14.1% (26/184)
Eosinophils (without neutrophils)	52.2% (96/184)
Neutrophils (without eosinophils)	4.9% (9/184)
Eosinophils and neutrophils	35.3% (65/184)
Direct immunofluorescence	
Combined deposition IgG and C3 at the BMZ	73.8% (135/183)
C3 deposition at the BMZ (without IgG)	20.8% (38/183)
IgG deposition at the BMZ (without C3)	5.5% (10/183)
IgA deposition at the BMZ	9.3% (17/183)
IgM deposition at the BMZ	6.5% (12/183)
Negativity for IgG and C3	0.0% (0/183)
Inadequate sampling	1.6% (3/189)
Exam not performed	1.6% (3/189)
Indirect immunofluorescence	
IgG deposition at the BMZ	72.7% (120/165)
IgM deposition at the BMZ	2.7% (4/145)
IgA deposition at the BMZ	2.7% (4/146)
Indirect immunofluorescence with salt-split skin technique	
IgG on the epidermal side of the split	81.9% (122/149)
IgG on the epidermal and dermal side of the split	4.0% (6/149)
IgA on the epidermal side of the split	12.0% (18/150)
IgM on the epidermal side of the split	3.7% (2/54)
IgE levels	
Above the laboratory reference range	74.6% (47/63)
Eosinophilia	
Eosinophil count $\geq$ 500	48.7% (91/187)
D-dimer levels	
Above the laboratory reference range	92.8% (26/28)

Fig. 2 presents the prevalence of the main disease groups among patients. Neurological and psychiatric conditions were present in 25.4% of patients, and studies indicate that 26.4%–55.8% of BP patients have at least one neurological condition.[5] Cardiovascular and metabolic conditions were prevalent in 77.8% of patients, consistent with a higher prevalence of metabolic syndrome associated with BP,[5] contributing to increased morbidity. The association between BP and malignancies remains controversial, but the high rate of this association (found in 23.3% of these cases) could be due to the prevalence of BP in older age groups.[5] Autoimmune and inflammatory comorbidities were present in 24.9% of patients, reflecting the autoimmune nature of BP.[5]

A recent meta-analysis suggested a connection between certain medications, such as aldosterone antagonists, DPP4 inhibitors, anticholinergics, and dopaminergic drugs, and the development of BP.[6] In the present study, 10.6% of patients were using at least one of these potentially BP-

Table 4 Therapies utilized by the patients during the follow-up period and their status at the final evaluation.

Treatment (percentage of patients who underwent each therapy during follow-up)	
Corticosteroid intralesional injection	2.6% (5/189)
Tetracycline	9.5% (18/189)
Doxycycline	35.4% (67/189)
Dapsone	17.5% (33/189)
Systemic corticosteroids	82.5% (156/189)
Methotrexate	7.4% (14/189)
Mycophenolate mofetil	11.1% (21/189)
Azathioprine	4.2% (8/189)
Rituximab	2.1% (4/189)
Plasmapheresis	0.5% (1/189)
Outcome at the last consultation	
Complete remission with medication	40.7% (77/189)
Complete remission without medication	30.7% (58/189)
Partial remission with medication	22.2% (42/189)
Partial remission without medication	0.5% (1/189)
Recurrence (>3-lesions lasting ≥7-days)	5.8% (11/189)

inducing medications at their initial assessment. Further analysis is needed to guide informed prescribing practices for BP management, as some of these medications are essential for treating comorbidities.

Histopathological findings primarily showed subepidermal blistering, often accompanied by eosinophils and/or neutrophils, which is consistent with the typical findings of bullous lesions, while non-bullous lesions usually demonstrate the presence of eosinophilic spongiosis (Fig. 3). Intraepidermal blistering may be attributed to the phenomenon of re-epithelialization and also to significant spongiosis, leading to intraepidermal vesication.[7]

DIF revealed combined IgG and C3 fluorescence at the BMZ in 73.8% of cases, with no negativity for both markers, indicating the high sensitivity of this method. IIF detected IgG deposits along the BMZ in 72.7% of cases, while SSS showed higher positivity, with 81.9% of cases presenting IgG fluorescence on the epidermal side – an expected result given the higher sensitivity of the SSS technique.[8] All three techniques demonstrated low positivity values for IgA and IgM. The positivity of these immunoglobulins is reported in the literature, with suggested associations between IgA positivity and mucosal involvement.[9–11] Fig. 4 shows the main findings of DIF and SSS techniques.

A significant portion of the evaluated cases presented eosinophilia and elevated IgE and D-dimer levels. These markers correlate with BP severity and activity, serving as important prognostic indicators.[2] However, the retrospective nature of the study limited further analysis, as these parameters were not available for all patients.

Immunosuppression is the primary treatment for BP, with only 6.9% of patients using topical corticosteroids alone, despite literature indicating their efficacy for mild cases.[2] Systemic corticosteroids were administered to 82.5% of patients, likely due to the higher severity of cases at the tertiary center, and only one patient experienced spontaneous improvement without any treatment. However, despite the challenges in treating BP patients, the present study showed promising treatment outcomes, as most patients were in complete remission at their last evaluation, regardless of still required specific medication.

The hospitalization rate in these cases was 55.0%, aligning with previous reports of 53.0%.[12] Venous thromboembolism occurred in 7.9% of patients, mostly after disease onset, likely due to BP-induced immune dysregulation, which promotes a pro-inflammatory state and increases thromboembolic risk.[2] Additionally, 62.4% of patients experienced at least one episode of secondary bacterial infection, a common complication and major cause of hospitalization in BP patients.[13] Infections, particularly pneumonia, were the leading cause of mortality, though mortality data were available for only 15 patients, representing a limitation.

Conclusion

In conclusion, the complexities of BP are apparent, with diverse clinical presentations, associated diseases, chal-

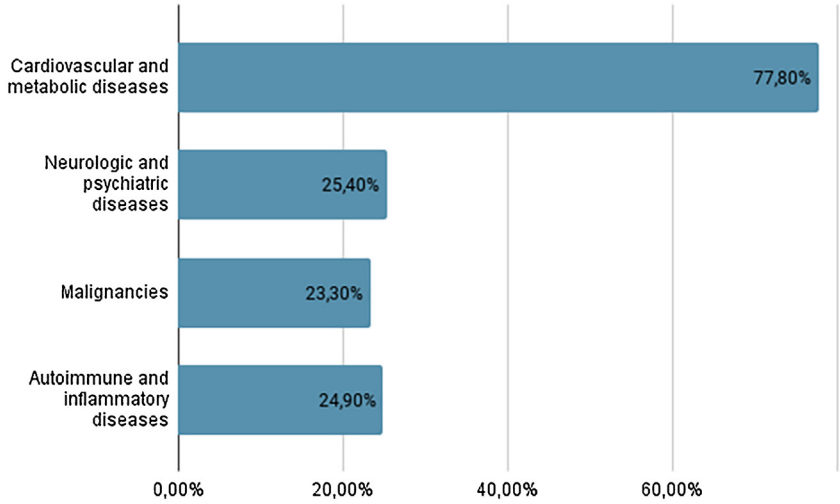

Figure 2 Graph showing the prevalence of the main disease groups presented by the patients.

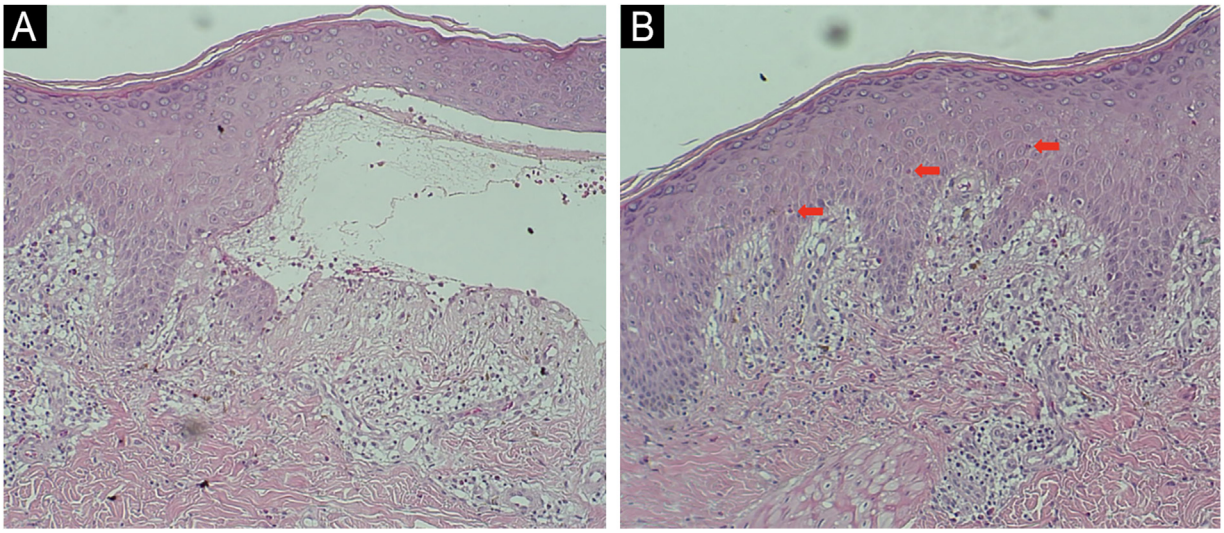

Figure 3 Skin biopsy: Histopathological findings of (A) subepidermal blistering with eosinophils in the classic BP form (Hematoxylin & eosin, ×4), and (B) presence of eosinophilic spongiosis (intraepidermal eosinophils within areas of spongiosis) in a case of non-bullous form (Hematoxylin & eosin, ×4).

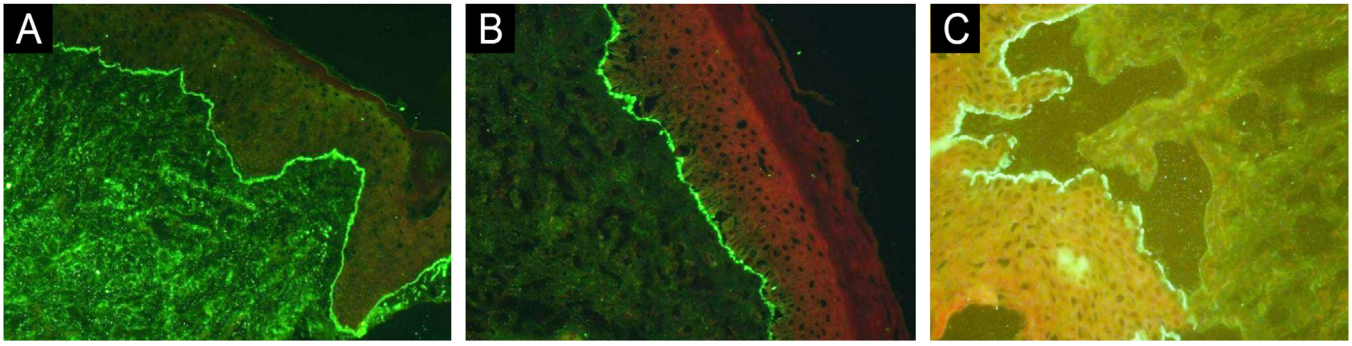

Figure 4 Immunofluorescence findings with DIF demonstrating IgG (A) and C3 (B) deposition at the BMZ, and IIF with salt-split technique demonstrating IgG deposition at epidermal side of the detachment (C).

lenging treatment regimens, and multiple complications. Despite its limitations, including a retrospective design and findings from a single tertiary center, this study provides crucial insights into the multifaceted nature of BP in the Brazilian context, emphasizing the need for a comprehensive approach to diagnosis, management, patient care, and prevention of complications.

Financial support

None declared.

Editor

Sílvio Alencar Marques.

Research data availability

The entire dataset supporting the results of this study was published in this article.

Author's contribution

Cecília Mirelle Almeida Honorato: Critical literature review; data collection, analysis and interpretation; preparation and writing of the manuscript; statistical analysis; study conception and planning.

Claudia Giuli Santi: Approval of the final version of the manuscript; effective participation in research orientation; intellectual participation in propaedeutic and/or therapeutic management of studied cases; manuscript critical review; study conception and planning.

Celina Wakisaka Maruta: Approval of the final version of the manuscript; effective participation in research orientation; intellectual participation in propaedeutic and/or therapeutic management of studied cases; manuscript critical review.

Valeria Aoki: Approval of the final version of the manuscript; effective participation in research orientation; intellectual participation in propaedeutic and/or therapeutic management of studied cases; manuscript critical review.

Denise Miyamoto: Critical literature review; preparation and writing of the manuscript; study conception and

planning; approval of the final version of the manuscript; effective participation in research orientation; intellectual participation in propaedeutic and/or therapeutic management of studied cases; manuscript critical review.

Conflicts of interest

None declared.

References

1. Lamberts A, Meijer JM, Jonkman MF. Nonbullous pemphigoid: a systematic review. J Am Acad Dermatol. 2018;78 :989–95.e2.
2. Miyamoto D, Santi CG, Aoki V, Maruta CW. Bullous pemphigoid. An Bras Dermatol. 2019;94:133–46.
3. Instituto Brasileiro de Geografia e Estatística (IBGE). Censo 2022: Panorama; c2024 [cited 2024 Oct 23]. Available from: https://censo2022.ibge.gov.br/panorama/.
4. Kridin K, Bergman R. Assessment of the prevalence of mucosal involvement in bullous pemphigoid. JAMA Dermatol. 2019;155: 166–71, http://dx.doi.org/10.1001/jamadermatol.2018.5049.
5. Huttelmaier J, Benoit S, Goebeler M. Comorbidity in bullous pemphigoid: update and clinical implications. Front Immunol. 2023;14:1196999.
6. Liu SDe, Chen WT, Chi CC. Association between medication use and bullous pemphigoid: a systematic review and meta-analysis. JAMA Dermatol. 2020;156:891–900.
7. Hodge BD, Roach J, Reserva JL, Patel T, Googe A, Schulmeier J, et al. The spectrum of histopathologic findings in pemphigoid: avoiding diagnostic pitfalls. J Cutan Pathol. 2018;45:831–8.
8. Mutasim DF, Adams BB. Immunofluorescence in dermatology. J Am Acad Dermatol. 2001;45:803–22, quis 822-824.
9. Horváth B, Niedermeier A, Podstawa E, Müller R, Hunzelmann N, Kárpáti S, et al. IgA autoantibodies in the pemphigoids and linear IgA bullous dermatosis. Exp Dermatol. 2010;19:648–53.
10. Cozzani E, Drosera M, Parodi A, Carrozzo M, Gandolfo S, Rebora A. Frequency of IgA antibodies in pemphigus, bullous pemphigoid and mucous membrane pemphigoid. Acta Derm Venereol. 2004;84:381–4.
11. Boch K, Hammers CM, Goletz S, Kamaguchi M, Ludwig RJ, Schneider SW, et al. Immunoglobulin M pemphigoid. J Am Acad Dermatol. 2021;85:1486–92.
12. Lee S, Rastogi S, Hsu DY, Nardone B, Silverberg JI. Association of bullous pemphigoid and comorbid health conditions: a case-control study. Arch Dermatol Res. 2021;313:327–32.
13. Ren Z, Hsu DY, Brieva J, Silverberg NB, Langan SM, Silverberg JI. Hospitalization, inpatient burden, and comorbidities associated with bullous pemphigoid in the U.S.A. Br J Dermatol. 2017;176:87–99.

Anais Brasileiros de Dermatologia 2025;**100(5)**:501160

SOCIEDADE BRASILEIRA DE DERMATOLOGIA

Anais Brasileiros de Dermatologia

www.anaisdedermatologia.org.br

ORIGINAL ARTICLE

Clinical-demographic profile, aggravating factors, comorbidities, and quality of life in patients with Rosacea: a Brazilian multicenter study (GBPER: Brazilian Research and Studies Group on Rosacea)☆

Renan Rangel Bonamigo [a,b,*], Paula Barea [c], Juliano Peruzzo [a,c], Juliana Boza [a,c], Hélio Amante Miot [d], Edileia Bagatin [e], Luiz Maurício Costa Almeida [f], Giovanni Indelicato Milano [f], Carla Wanderley Gayoso de Lima [g], Linácia Freitas Vidal [g], Fabíola Rosa Picosse [e], Bruna Manuella de Figueiredo Afonso [e], Clivia Maria Moraes de Oliveira [h]

[a] *Service of Dermatology, Hospital de Clínicas de Porto Alegre, Faculty of Medicine, Universidade Federal do Rio Grande do Sul, Porto Alegre, RS, Brazil*
[b] *Service of Dermatology, Santa Casa de Porto Alegre, Porto Alegre, RS, Brazil*
[c] *Universidade Federal do Rio Grande do Sul, Porto Alegre, RS, Brazil*
[d] *Department of Dermatology, Faculdade de Medicina, Universidade Estadual Paulista, Botucatu, SP, Brazil*
[e] *Department of Dermatology, Escola Paulista de Medicina, Universidade Federal de São Paulo, São Paulo, SP, Brazil*
[f] *Dermatology Clinic, Santa Casa de Misericórdia Belo Horizonte, Belo Horizonte, MG, Brazil*
[g] *Department of Infectious, Parasitic and Inflammatory Diseases, Universidade Federal da Paraíba, João Pessoa, PB, Brazil*
[h] *Department of Dermatology, Universidade Federal do Pará, Belém, PA Brazil*

Received 12 May 2024; accepted 10 September 2024
Available online 11 July 2025

KEYWORDS
Acneiform eruptions;
Classification;
Epidemiology;
Facial dermatoses;
Rosacea

Abstract
Background: Rosacea is the most prevalent chronic vascular-inflammatory dermatosis of the face. Its pathogenesis includes genetic and environmental factors, neurovascular alterations, and innate immunity. Many triggering and aggravating factors, as well as systemic comorbidities, have been associated with the disease, but there are few studies on its epidemiology in Brazil.
Objectives: To describe the profile of patients with rosacea treated at referral centers, as well as to investigate the presence of comorbidities, dietary aspects, worsening factors, and quality of life.

☆ Study conducted at the Hospital de Clínicas de Porto Alegre, Universidade Federal do Rio Grande do Sul, Porto Alegre, RS, Brazil; Universidade Federal de São Paulo, São Paulo, SP, Brazil; Faculdade de Medicina, Universidade Estadual Paulista, Botucatu, SP, Brazil; Santa Casa de Belo Horizonte, Belo Horizonte, MG, Brazil; Universidade Federal da Paraíba, João Pessoa, PB, Brazil; Universidade Federal do Pará, Belém, PA Brazil.

* Corresponding author.
E-mail: rrbonamigo@hcpa.edu.br (R.R. Bonamigo).

https://doi.org/10.1016/j.abd.2025.501160

Methods: Cross-sectional and multicenter Brazilian study. Clinical and demographic data, disease severity, triggering and/or aggravating factors, diet, comorbidities, and impact on quality of life were evaluated.
Results: 258 patients were included, predominantly women, between 35 and 65 years old and phototypes III, IV and II. The clinical picture ranged from mild to moderate in 89% of cases and quality of life was reasonable to slightly affected in 58% of cases. Aggravating factors for rosacea were reported by 96% of patients, with climate exposure, alcoholic beverages, and emotional changes being the most frequent. Among the foods mentioned as aggravating factors (28%), pepper, other condiments and hot beverages were the most frequently reported. Comorbidities were reported by 89% of the participants, with emphasis on endocrine (48%), psychiatric (35%), cardiovascular (31%) and gastrointestinal (28%) diseases.
Study limitations: Uncontrolled study, including patients undergoing dermatological treatment.
Conclusions: This study establishes that the profile of Brazilian patients with rosacea corroborates that described in the literature, with the presence of the disease in higher phototypes being relevant. Pepper and other condiments and hot beverages were important aggravating factors, and the presence of various comorbidities was reported by most of the patients.

Introduction

Rosacea is a chronic inflammatory skin disease that mainly affects the central regions of the face (malar region, nose, eyes, chin and forehead). It mainly affects women with fair skin and aged between 20 and 50 years, although children can be affected.[1] The prevalence of the disease varies between the studied countries and according to ethnic composition, ranging from 1% to over 20% of adults.[2–4] In Brazil, there are no population-based studies; a recent study carried out in 13 dermatology outpatient clinics estimated a prevalence of 13% among adult dermatological patients.[5] Although being more common in women, men more frequently develop more severe forms of the disease, especially phymas.[6]

Clinically, it is characterized by persistent facial erythema with or without edema, papules, pustules, recurrent episodes of transient erythema (flushing), telangiectasias and phymas.[1,7] It is believed that half of the patients have ocular involvement; however, ophthalmological complaints are often underestimated.[8]

The diagnosis of rosacea is clinical and does not require laboratory tests. Anatomopathological examination may occasionally be useful to rule out other diseases. Several diagnostic systems have been proposed; however, the most widely used is the one proposed by the Global Rosacea Consensus (ROSCO) panel, with criteria based on the disease phenotype.[9–12]

Rosacea negatively affects quality of life due to its chronicity, irritative symptoms, evolution in flare-ups, and because it affects the face. It can cause embarrassment, anxiety, low self-esteem, harm to professional relationships, and even difficulty finding a job.[13–15]

Its pathogenesis is complex and not yet fully understood, including genetic predisposition and other intrinsic and extrinsic factors related to the disease phenotype.[16] The participation of the cutaneous (e.g., increased colonization by the *Demodex* sp. mite) and gastrointestinal microbiomes has gained recent importance.[17] The association of diet with rosacea is controversial; some foods may cause exacerbation or exert possible protection through regulation of the intestinal microbiome.[18,19]

Neurovascular dysregulation may be related to the occurrence of flushing. The mediators suggested as markers of this mechanism include vascular endothelial growth factor (VEGF) and CD 31.[20] Ultraviolet radiation (UVR) can induce an increase in cutaneous VEGF, exacerbating rosacea.[21]

The participation of innate immunity is evidenced by the greater expression of the Antimicrobial Peptide (AMP), of the cathelicidin family, of 37-amino-acid peptide (LL-37), the enzyme that activates it - a serine protease of the kallikrein family - produced by keratinocytes, and of the Toll-Like-2 receptor (TRL-2) in skin lesions.[10,20–26]

Moreover, the skin of the face in patients with rosacea is very sensitive, with alterations in the skin barrier that favor inflammation.[27,28]

Several factors are reported as triggers or exacerbators of rosacea, such as stress, hot or cold climates, wind, solar radiation, ingestion of hot beverages, alcoholic beverages, tea, coffee, spicy foods and smoking.[29]

Rosacea has been associated with several systemic comorbidities: neurological, psychiatric, gastrointestinal and cardiovascular ones.[29,30] Its association with metabolic syndrome may result from increased cathelicidins, pro-inflammatory cytokines and systemic oxidative stress.[31]

Despite its relevance, there is no comprehensive Brazilian data on different aspects of the profile of patients with rosacea. The scarce studies include few variables; there are also no publications investigating associated comorbidities, dietary habits, and the disease impact on quality of life.[5,32]

This study aimed to describe the clinical and demographic profile of patients with rosacea, as well as to investigate comorbidities, dietary habits, perception of worsening factors, and the disease impact on quality of life, in samples from different regions of Brazil.

Methods

A cross-sectional, descriptive, multicenter study was conducted in the Dermatology Services (all accredited by the Brazilian Society of Dermatology), by the Brazilian Research and Studies Group on Rosacea, of the following institutions in Brazil: Universidade Federal do Rio Grande do Sul/Hospital de Clínicas de Porto Alegre; Universidade Federal de São Paulo; Universidade Estadual Paulista Faculty of Medicine; Santa Casa de Belo Horizonte, Universidade Federal da Paraíba and Universidade Federal do Pará, between March 2022 and September 2023. The research was approved by the Ethics and Research Committees of each center.

The inclusion criteria were: adult patients diagnosed with rosacea by certified dermatologists. The exclusion criterion used was the presence of other facial dermatoses (other than rosacea) that prevented a correct clinical evaluation at the time of the consultation.

The calculations to define the sample size were performed using the WINPEPI 11.65® program. To estimate the frequency of comorbidities of 80% in patients with rosacea, with a margin of error of 5 percentage points (acceptable difference = 0.05) and a confidence level of 95%, 246 study participants were required.

After signing the Informed Consent Form (ICF), the participants answered data collection instruments: a clinical data questionnaire, including Body Mass Index (BMI), demographic data and comorbidities, a questionnaire on factors that aggravate rosacea, a dietary questionnaire focusing on factors that trigger rosacea, and a quality of life questionnaire translated and validated into Brazilian Portuguese (RosaQol-BR).[33]

The RosaQol-BR consists of 21 questions related to three domains, which explain how rosacea affects patients' quality of life and are related to the severity reported by patients: symptoms, emotions, and function. The result is based on an average of the responses (''never – 1'', ''rarely – 2'', ''sometimes – 3'', ''frequently – 4'' or ''always – 5'') related to each domain, in addition to the global assessment. The final score for each domain can therefore vary from 1 to 5, and the final value is the sum of the averages for each question.[33] The RosaQol-BR questionnaire is self-administered.

All participants were classified according to the characteristics and severity of rosacea using the Investigator Global Assessment of Rosacea Severity Score (IGA-RSS), with the following parameters: IGA-0: Absent (rosacea almost absent – absence of papules and/or pustules, absent or residual erythema, mild degree of telangiectasias may be present), IGA-1: Minimal (rare papules or pustules, residual erythema and telangiectasias may be present), IGA-2: Mild (some papules and/or pustules, mild erythema and mild or moderate degree of telangiectasias), IGA-3: Mild to moderate (distinct number of papules and/or pustules, erythema and telangiectasias of mild to moderate degrees), IGA-4: Moderate (marked number of papules and pustules, erythema and moderate degree of telangiectasias), IGA-5: Moderate to severe (many papules and/or pustules, occasionally with large inflammatory lesions, moderate erythema and moderate degree of telangiectasias), IGA-6: Severe (numerous papules and pustules, occasionally with confluent areas of inflammation, erythema and severe degree of telangiectasias).[34]

The clinical assessment of rosacea, based on the Rosacea Clinical Scorecard (RCS), includes its classification as absent, mild, moderate, or severe based on primary characteristics (flushing, persistent erythema, papules and pustules, telangiectasias), secondary characteristics (burning or stinging, plaques, dry appearance, edema, ocular manifestation, peripheral manifestation, phymatous or granulomatous changes) and the classification ''absent'', ''mild'', ''moderate'' or ''severe'' for the subtypes: erythematotelangiectatic, papulopustular, phymatous, ocular and global assessment.[35]

The description of the numerical variables was used for the statistical analysis, with mean and standard deviation, and, for categorical data, the absolute value and the calculation of the percentage in relation to the total sample. The internal consistency of the RosaQoL questionnaire was assessed by Cronbach's alpha coefficient, considering adequate if > 0.8.

Results

A total of 258 patients diagnosed with rosacea were evaluated, and the main demographic data are shown in Table 1. There was a predominance of female participants (2.3 times), aged between 35 and 65 years, with phototypes II to IV (95%), with overweight and obesity (67.3%), of European descent (83%) and with a family history of rosacea (32%).

The high prevalence of use of antihypertensives (31%), antidepressants (19%), antidiabetics (17%) and lipid-lowering drugs (15%) stands out. The time of disease evolution was highly variable (from three months to 45 years, with an average of 11 years). In addition to topical interventions, 30% had already used oral treatments such as tetracyclines and isotretinoin.

According to the IGA-RSS scale, 83% of the cases had mild to moderate rosacea. The clinical score (RCS) identified flushing in 84% of cases, burning sensation in 69%, papules and pustules in 73%, phymas in 22%, and ocular forms in 41%. According to the patient's assessment, 89% classified disease activity as mild to moderate. The other clinical elements of the sample, such as rosacea severity assessment and rosacea characteristics assessed by the investigator and patients, are shown in Table 2.

The results of the mean scores of the domains measured by RosaQoL (internal consistency defined by Cronbach's alpha coefficient was > 0.8), self-perception of rosacea severity, and self-perception of the impact on quality of life caused by the disease are shown in Table 3. The most affected quality of life domain was symptoms. Overall, 75% of the participants considered their rosacea as good and regular over the past four weeks, and 58% considered that rosacea interfered little or reasonably with their quality of life.

Aggravating factors for rosacea were reported in 96% of cases, with environmental exposure, emotional conditions, and physical exercise predominating. Food items were reported as aggravating factors by 72 (27.9%) of the participants, with pepper and other condiments and hot beverages being the most frequently mentioned (Table 4).

Table 1 Main demographic characteristics of participants with rosacea (n = 258).

Variable	Values
Age (years)[a]	51.3 ± 14.4
Body Mass Index (kg/m^2)[a]	26.9 ± 5.7
Overweight (BMI > 25 < 30 kg/m^2)[b]	100 (39.21%)
Obesity (BMI ≥ 30 kg/m^2)[b]	72 (27.9%)
Time to diagnosis (year)[a]	8.0 ± 8.6
Total duration of disease (years)[a]	11.1 ± 9.2
Sex[b]	
Female	179 (69.4%)
Male	79 (30.6%)
Phototype[b]	
I	7 (2.7%)
II	61 (23.7%)
III	119 (46.3%)
IV	66 (25.7%)
V	4 (1.6%)
Self-reported ancestry[b]	
European	215 (83.3%)
African-American	18 (7.0%)
Eastern-Asian	2 (0.8%)
Indigenous	23 (8.9%)
Level of schooling[b]	
Did not attend	4 (1.6%)
Kindergarten	25 (9.7%)
Elementary School	50 (19.4%)
High School	61 (23.6%)
Higher Education	118 (45.7%)
Family history of rosacea[b]	83 (32.3%)
Medications in use[b]	185 (71.7%)
Anti-hypertensives	80 (31.0%)
Antidepressants	50 (19.4%)
Antidiabetics	45 (17.4%)
Lipid-lowering agents	38 (14.8%)
Levothyroxine	29 (11.3%)
Oral contraceptives	25 (9.7%)
Proton-pump inhibitor	22 (8.6%)
Antiplatelet agents	10 (3.9%)
Vasodilators	7 (2.7%)
Others[c]	87 (47%)
Treatments used for rosacea[b]	
Topical	167 (64.7%)
Azelaic acid	82 (31.8%)
Ivermectin	91 (35.3%)
Metronidazole	87 (33.7%)
Oral	78 (30.2%)
Cyclins	71 (27.5%)
Isotretinoin	19 (7.4%)
Laser / pulsed light	55 (21.3%)

[a] Mean and standard deviation.
[b] Absolute and percentage values.
[c] Medications with less than 2% frequency.

Certain foods traditionally recognized as aggravating factors were investigated regarding the frequency of consumption, and the following were consumed daily by the patients in the present study: hot coffee (79.1%), milk and dairy products (72.9%), tomatoes (54.3%), citrus fruits

Table 2 Clinical evaluation of rosacea using the Investigator Global Assessment of Rosacea Severity Score (IGA-RSS) and Rosacea Clinical Scorecard (RCS; n = 258).

Clinical assessment scores (investigator)	Categories	n (%)
IGA-RSS	1	73 (29.4%)
	2	97 (39.1%)
	3	45 (18.1%)
	4	25 (10.1%)
	5	7 (2.8%)
	6	1 (0.4%)
RCS		
Flushing	Absent	42 (16.3%)
	Mild	100 (38.8%)
	Moderate	93 (36.0%)
	Intense	23 (8.9%)
Erythema	Absent	67 (26%)
	Mild	122 (47.3%)
	Moderate	65 (25.2%)
	Intense	4 (1.6%)
Papules and Pustules	Absent	91 (35.3%)
	Mild	121 (46.9%)
	Moderate	43 (16.7%)
	Intense	3 (1.2%)
Telangiectasias	Absent	34 (13.2%)
	Mild	146 (56.6%)
	Moderate	71 (27.5%)
	Intense	7 (2.7%)
Burning or stinging	Absent	81 (31.4%)
	Mild	83 (32.2%)
	Moderate	73 (28.3%)
	Intense	21 (8.1%)
Plaques	Absent	219 (84.9%)
	Mild	22 (8.5%)
	Moderate	14 (5.4%)
	Intense	3 (1.2%)
Dry appearance	Absent	148 (57.4%)
	Mild	68 (26.4%)
	Moderate	40 (15.5%)
	Intense	2 (0.8%)
Edema	Absent	224 (87.2%)
	Mild	26 (10.1%)
	Moderate	5 (1.9%)
	Intense	2 (0.8%)
Ocular	Absent	151 (58.5%)
	Mild	76 (29.5%)
	Moderate	24 (9.3%)
	Intense	7 (2.7%)
Peripheral (extra-facial)	No	233 (90.7%)
	Cervical	12 (4.7%)
	Pre-auricular	1 (0.4%)
	Back	1 (0.4%)
	Scalp	3 (1.2%)
	Anterior thorax/neck	7 (2.7%)
Phymatous changes	Absent	200 (77.5%)
	Mild	23 (8.9%)
	Moderate	27 (10.5%)
	Intense	8 (3.1%)

Table 2 (*Continued*)

Clinical assessment scores (investigator)	Categories	n (%)
Changes compatible with granulomatous rosacea	Absent	238 (92.2%)
	Mild	8 (3.1%)
	Moderate	11 (4.3%)
	Intense	1 (0.4%)
Erythematous telangiectatic	Absent	14 (5.4%)
	Mild	146 (56.6%)
	Moderate	89 (34.5%)
	Intense	9 (3.5%)
Papulopustular	Absent	96 (37.2%)
	Mild	119 (46.1%)
	Moderate	40 (15.5%)
	Intense	3 (1.2%)
Phymatous	Absent	197 (76.4%)
	Mild	26 (10.1%)
	Moderate	27 (10.5%)
	Intense	8 (3.1%)
Ocular	Absent	157 (60.9%)
	Mild	70 (27.1%)
	Moderate	23 (8.9%)
	Intense	8 (3.1%)
Overall patient assessment	Absent	8 (3.1%)
	Mild	129 (50.0%)
	Moderate	100 (38.8%)
	Intense	21 (8.1%)

*Results presented in absolute values and percentages.

Table 3 Quality of life in participants with rosacea, according to the RosaQoL instrument, self-perception of rosacea severity, and self-perception of quality of life inflicted by the disease (n = 258).

Variables	Values
Domains[a]	
Symptom	2.9 ± 0.8
Emotion	2.7 ± 1.1
Function	2.1 ± 1.0
General	2.6 ± 0.8
How has your rosacea been over the past four weeks?[b]	
Bad	37 (14.5%)
Regular	110 (43.3%)
Good	80 (31.3%)
Very good	18 (7.0%)
Excellent	11 (4.3%)
How much does your rosacea influence your quality of life?[b]	
Not at all	48 (18.7%)
A little	82 (31.9%)
Reasonably	68 (26.5%)
A lot	46 (17.9%)
Very much	13 (5.1%)

Results presented in mean and standard deviation[a] and absolute and percentage frequencies[b].

Table 4 Aggravating factors reported by participants with rosacea (n = 258).

Factors[a]	Values – n (%)
Sun exposure	196 (76.0%)
Emotional changes	169 (65.5%)
Heat	160 (62.0%)
Physical exercise	115 (44.6%)
Alcohol	110 (42.6%)
Wind	66 (25.6%)
Foods	72 (27.9%)
Pepper	39 (54.16%)[b]
Other condiments	9 (12.5%)[b]
Hot foods/beverages	6 (8.3%)[b]
Dairy products	6 (8.3%)[b]
Chocolate	6 (8.3%)[b]
Coffee	5 (6.9%)[b]
Wine	4 (5.6%)[b]
Fats/fried foods	4 (5.6%)[b]
Milk	4 (5.6%)[b]
Sugar	4 (5.6%)[b]
Sweets	3 (4.2%)[b]
Processed meats-preservatives	3 (4.2%)[b]
Crustaceans	3 (4.2%)[b]
Tomato paste/tomato	2 (2.8%)[b]
Mayonnaise	2 (2.8%)[b]
Ketchup	2 (2.8%)[b]
Ginger	2 (2.8%)[b]
Cinnamon	2 (2.8%)[b]
Others	14 (19.4%)[b]
No aggravating factors mentioned	10 (3.9%)

[a] There may be more than one factor for each patient.
[b] Percentage related to the 72 cases that reported aggravation due to food.

(50.4%), vegetable fat (44.5%), chocolate (19%), vinegar (11.6%), ginger (7.4%) and pepper (6.2%).

Active smoking was reported by 8% of the patients and alcoholism by 5%. Comorbidities were identified in 89.1% of the participants (Table 5), with emphasis on gastrointestinal, endocrine, cardiovascular, and psychiatric diseases.

Discussion

The multiethnic characteristics and cultural and climatic variability of Brazil require studies with representative samples from different regions for a more adequate understanding of the characteristics of its dermatoses, aiming to improve disease perception and its therapeutic approach. There are national data on the prevalence of rosacea with different results, which may reflect this variation between regions: in a study conducted in the south of the country, a higher prevalence of rosacea was found in women aged between 40 and 50 years,[32] while in another the most affected age group was between 60 and 79 years and the least affected was under 30 years.[5] In other non-Brazilian studies, a predominance was observed in women aged between 30 and 60 years, and it can also affect children and the elderly.[2,9,35] There were also reports that men develop more severe forms, possibly due to androgenic

Table 5 Reports of comorbidities reported by research participants (n = 258).

Comorbidities	n (%)
Gastrointestinal condition	71 (27.5%)
Crohn's disease / URC	6 (2.3%)
Gastroesophageal reflux disease	32 (12.4%)
Gastritis/gastric ulcer	40 (15.5%)
Pancreatitis	1 (0.4%)
Bariatric surgery	1 (0.4%)
Lactose intolerance	5 (1.9%)
Irritable bowel syndrome	5 (1.9%)
Colitis	1 (0.4%)
Diverticulitis	1 (0.4%)
Gastric hernia	1 (0.4%)
Neurological disease	46 (17.8%)
Cerebrovascular accident	6 (2.3%)
Migraine	39 (15.1%)
Other neurological disease	3 (1.2%)
Psychiatric disease	89 (34.5%)
Depression	46 (17.9%)
Anxiety	67 (26.1%)
Social phobia	1 (0.4%)
OCD	1 (0.4%)
Panic syndrome	1 (0.4%)
Insomnia	2 (0.8%)
Autoimmune disease	38 (14.8%)
Psoriasis	14 (5.4%)
Lupus erythematosus	6 (2.3%)
Frontal fibrosing alopecia	4 (1.6%)
Rheumatoid Arthritis	3 (1.2%)
Vitiligo	2 (0.8%)
Scleroderma or systemic sclerosis	2 (0.8%)
Hashimoto's disease	4 (1.5%)
Purpura and hidradenitis	1 (0.4%)
Purpura	1 (0.4%)
Pemphigus foliaceus	1 (0.4%)
Transverse myelitis	1 (0.4%)
Lupus, scleroderma and dermatomyositis	1 (0.4%)
Infectious disease	12 (4.7%)
HIV/AIDS	4 (1.5%)
Hepatitis B	3 (1.2%)
Chagas' disease	1 (0.4%)
Leprosy	1 (0.4%)
Recurrent UTI	1 (0.4%)
Latent tuberculosis	1 (0.4%)
Chromomycosis	1 (0.4%)
Neoplastic disease	40 (15.6%)
Cutaneous BCC/SCC	23 (8.91%)
CIN 3	1 (0.4%)
Melanoma	7 (2.7%)
Larynx	1 (0.4%)
Thyroid	3 (1.16%)
Breast	5 (1.9%)
Ovarian teratoma	1 (0.4%)
Intestine / Rectum	1 (0.4%)
Prostate	2 (0.8%)
Endometrium	1 (0.4%)
Leukemia	1 (0.4%)
Cardiovascular diseases	81 (31.4%)
Arterial Hypertension	77 (29.8%)
Acute myocardial infarction	3 (1.2%)
Dyslipidemia	40 (15.5%)
Arrythmia / atrial fibrillation	7 (2.7%)
Cardiomegaly	1 (0.4%)
Heart failure	1 (0.4%)
Venous thrombosis	2 (0.8%)
Endocrine disease	123 (47.7%)
Diabetes mellitus	42 (16.3%)
Thyroid nodule	3 (1.2%)
Hypothyroidism	18 (7%)
Insulin resistance	3 (1.2%)
Osteoporosis	1 (0.4%)
Obesity	61 (23.6%)
Metabolic syndrome	42 (16.3%)
Liver disease	26 (10.07%)
Steatosis	22 (8.5%)
Liver thrombosis	1 (0.4%)
Post-hepatitis cirrhosis	1 (0.4%)
Drug-induced hepatitis	1 (0.4%)
Liver transplant	1 (0.4%)
Urological disease	21 (8.1%)
Renal lithiasis	15 (5.8%)
Glomerulonephritis – transplant	1 (0.4%)
Prostatic hyperplasia	2 (0.8%)
Nephritis in childhood	1 (0.4%)
Renal cyst	1 (0.4%)
Pyelonephritis	1 (0.4%)

URC, Ulcerative rectocolitis; OCD, Obsessive-Compulsive Disorder; HIV/AIDS, Human Immunodeficiency Virus/Acquired Immunodeficiency Syndrome; UTI, Urinary Tract Infection; BCC/SCC, Basal Cell Carcinoma/Squamous Cell Carcinoma; CIN, Cervical Intraepithelial Neoplasia.

activity.[6,36] Furthermore, a study showed a higher prevalence in female patients up to 49 years of age, but the prevalence was higher in men between 50 and 70 years of age.[37]

In this investigation, as mentioned in Table 1, a high predominance of rosacea was found among women (69.4%). An additional difference between the sexes in this study compared to others may have occurred due to the tendency for women to seek medical care more frequently.[9,35,38] A wide age range affected by the disease was also identified, including cases of rosacea in individuals over 60 years of age.

There is a consensus that rosacea predominates in people with lower phototypes (I and II) according to the Fitzpatrick classification, 1988,[36,39] although there are reports of the disease in populations with higher phototypes.[35,36,40] The results of the present study showed that almost half of the population studied was phototype III, followed by phototypes IV and II. The disease in phototypes I and V was rarely observed. These data demonstrate a particularity of the disease in Brazil, which may be related to the ethnic composition of the Brazilian population. It is noteworthy that the suspicion of rosacea is more difficult in darker skin, leading to a late diagnosis.

Rosacea is more frequently described in European countries, particularly in the north.[36] The majority (83.3%) of

the patients in the present study were of European descent, corroborating findings from previous Brazilian studies.[5,32,41]

Regarding the patients' occupations, there was a wide diversity of professions and there was no association regarding the prevalence of rosacea in the reported professions.

As for the level of schooling, it was observed that 45.7% of the study participants had completed higher education and 23.6% had completed high school. It was not possible to compare this finding because, to date, it has not been reported in the literature on rosacea. It is important to emphasize that in Brazil there is a high presence of adult white women in higher education, which has a likely interface with this high level of schooling found in the sample.[42]

Only 8.1% of the study population were smokers. The inverse association between rosacea and smoking is controversial and some authors claim that active smoking may be a protective factor for rosacea.[5,43] There have been reports that nicotine may play an anti-inflammatory role[43,44] and promote vasoconstriction in the skin.[45,46]

In the present study, 95% of the individuals were non-alcoholics; however, among them, 42.6% associated alcohol intake with rosacea exacerbation. Although it is mainly related to flushing, the association between alcoholic beverages and the onset of rosacea remains controversial in the literature.[29,32,47,48] A study carried out with 82,737 North American women followed for 14 years, with 4,948 cases of rosacea, showed that higher alcohol intake was associated with an increased risk of the disease compared to patients who never consumed alcoholic beverages.[47] A recent meta-analysis concluded that alcohol consumption is not a risk factor for rosacea; however, in the subgroup analysis, a higher risk for the phymatous form was observed.[48] Another study showed that the use of alcoholic beverages increased the risk of rosacea, but only with high consumption per week.[2]

Regarding information on height, weight, and BMI, there is little data on patients with rosacea in the literature.[44] In the present investigation, it was found that the average weight was 73.5 kg $\pm$ 15.21; the mean height was 1.65 m $\pm$ 0.1 and the mean body mass index was 26.87 kg/m^2 $\pm$ 5.67. Additionally, 39.21% of the participants were classified as overweight and 28.23% showed some degree of obesity. The increased risk of rosacea in patients with obesity had already been described, with a risk ratio of 1.48 in patients with BMI $\geq$ 35.0 when compared to those with a BMI between 21.0 and 22.9 kg/m^2.[49]

A family history of rosacea occurred in one-third of the cases, corroborating the role of previously reported. genetic (yet to be better understood) and environmental factors[16,20,25] A study with identical and fraternal twins showed a genetic participation of 46% in rosacea manifestations.[50]

Disease evolution showed an average period of 11 years, and the average time until diagnosis was eight years. Several factors can delay the diagnosis of rosacea, such as difficulty in accessing tertiary health services, overlapping symptoms with other dermatoses, and diagnosis complexity in darker skin due to difficulty in visualizing vascular manifestations, such as erythema and telangiectasia. It is noteworthy that 27% of the individuals were phototypes IV and V in the population of this study, which could be considered a factor for later diagnosis.

The use of systemic medications to treat other diseases was highly prevalent, particularly antihypertensive drugs. There are contradictory reports of worsening or triggering of rosacea by the use of calcium channel blockers, which should be avoided, and there is debate about the reduced risk in patients using beta-blockers.[51–53]

The use of antidepressants was observed in approximately 20% of individuals, and the relationship between rosacea and psychiatric disorders, especially anxiety and depression, is frequently reported.[14,15] A discrepancy was observed between rosacea severity and the impact on quality of life since the disease was moderate or severe in 46.8% of the participants and only 23% reported a negative influence on quality of life. An important consideration is the cross-sectional approach of the present study. Many patients were undergoing treatment, which positively impacted the perception of quality of life. It is known that dermatological treatment interferes with this assessment, improving the results,[54] making it difficult to draw conclusions about the true extent of the disease impact. This dissociation between severity and quality of life has already been reported,[14] since patients with mild forms can have a relevant impact when left untreated.

Regarding treatments, topical medications were mentioned by 64.7% of patients, and systemic medications by 30.2%. The active ingredients were in accordance with the recommendations of therapeutic guidelines for rosacea.[41,55,56]

Data related to the demographic characteristics of the participants in the present study can be found in Table 1.

The frequency of the observed clinical manifestations of rosacea was similar to those described in a meta-analysis,[57] with the exception of phytates and ocular changes, which were more prevalent in the present study (Table 2).

Subjective symptoms such as burning or stinging can have a negative impact on quality of life, in addition to representing an auxiliary tool for diagnosis.[58] The frequency of this symptom is usually under-assessed in clinical practice, due to the difficulty in measuring it. A high frequency was observed, particularly with mild or moderate intensity, as in a previous study.[58]

Chronic inflammation in rosacea has been associated with multiple comorbidities, including cardiovascular, psychiatric, neurodegenerative, gastrointestinal, neurological, oncological, endocrine, and autoimmune diseases. The extent, clinical significance, and consequences of these associations are not fully understood.[59,60] In the present sample, 27.5% of the patients reported some gastrointestinal disease; this association should be considered by physicians for early diagnosis and therapeutic implications.[61–63]

Neurovascular dysregulation and chronic inflammation may explain the association between rosacea and headache, particularly migraine.[64] Most patients with rosacea and headache have the erythematotelangiectatic subtype and, in addition to flushing or transient erythema, persistent erythema and telangiectasias characteristic of the skin condition, photophobia and phonophobia are common. A study showed that 15% of patients with rosacea had migraines, and the risk seemed higher in men.[65] In contrast, the present study showed a higher prevalence of migraines in women, accounting for 17.9%, while the prevalence in men was 8.9%.

Although there have been reports of an increased risk of neurodegenerative diseases in patients with rosacea, particularly Parkinson's disease and dementia, such as Alzheimer's disease,[66] the present data did not demonstrate these conditions. The risk of developing psychiatric symptoms is 1.6 to 2-fold higher in patients with rosacea when compared to controls, possibly due to shared mechanisms involving the neuro-immuno-cutaneous system.[14,15,66,67] The findings of the present study are in agreement with this observation, since psychiatric diseases were detected in 34.5% of the individuals, particularly anxiety and depression.

Regarding oncological diseases, the literature shows that rosacea is associated with an increased risk of Non-Melanoma Skin Cancer (NMSC), glioma, and breast cancer.[66,68] In the present population, 23 (8.9%) patients with NMSC were detected; however, fair skin and European ancestry are common factors for rosacea and this type of skin cancer.

Patients with rosacea are predisposed to the risk of subclinical cardiovascular (CV) disease, atherosclerosis, and thromboembolism,[69–73] with screening and guidance on lifestyle modifications being advised. In this study, 31.4% of patients reported CV disease, 29.8% had hypertension, and 15.5% had dyslipidemia.

Endocrinological abnormalities are frequently observed in patients with rosacea, having been found in half of the participants in this study. The main endocrine disorders were diabetes mellitus, obesity, and metabolic syndrome.

Clinicians should be aware of the potential risk of systemic comorbidities in rosacea, which becomes more likely as the duration and severity of the disease increase. The potential to control these conditions aiming to improve rosacea symptoms and vice versa should be the focus of further research.[13,66]

Quality of life is impacted in most patients with rosacea, since the disease is chronic, recurrent, and manifests itself in exposed areas, such as the face. Low self-esteem, social phobia, depression, and anxiety may occur, which compromise the affected individuals' mental health and socialization.[74,75] The RosaQoL-BR scores revealed an impact on the quality of life in almost 50% of patients, although almost 90% considered their disease to be mild to moderate in the overall assessment, as it was considered by the researchers.

Several environmental factors are described as triggering or aggravating rosacea, which were reported by 96% of the participants in this study. As shown in Table 4, which lists the triggering or aggravating factors reported by the study participants, sun exposure was the main one, corroborating the data in the literature.[76,77] The higher disease prevalence in lighter skin and the presence of lesions in the central area of the face, which are the most exposed to sunlight, corroborate this hypothesis.[3] UVR can trigger rosacea, actively participating in its etiopathogenesis.[77]

Acute emotional changes were reported by more than half of the participants, reinforcing stress as a relevant trigger, as it increases levels of cortisol and adrenocorticotropic hormone, activating the hypothalamic-pituitary-adrenal axis.[77]

Exposure to heat was mentioned as a trigger by 62% of the participants, as well as, to a lesser extent, cold and wind. It is important to highlight the great climatic variation in the different regions of Brazil, such as extreme heat in the Amazon region, cold in the subtropical regions, and heat and wind on the coast of the Northeast. This study included patients from states in all of these regions, making the sample quite heterogeneous, but representative of the country's climate variability. Disease worsening due to physical exercise, which has a thermogenic and vasodilatory effect, was reported by almost half of the participants.[3,76]

The intake of certain foods is referred to as a trigger or worsening factor for rosacea, although there are few studies confirming this property.[18,19] In this study, 28% of the participants reported worsening of rosacea with the diet, with pepper being reported by more than half of them, followed by other spicy foods and seasonings. The foods considered as triggers can be divided into four categories: hot foods/beverages, such as coffee (33%) and tea (30%), spicy foods, foods with cinnamaldehyde, and alcoholic beverages.[18,76] Capsaicin is present in peppers and cinnamaldehyde is found in tomatoes, citrus fruits, cinnamon, and chocolate. The relationship between diet and the gut-skin axis has been reported, interfering in the clinical manifestations of the disease.[18]

The present results demonstrated that some foods that are consumed daily were rarely mentioned as triggers of the disease, such as hot coffee, milk and dairy products, tomatoes, and citrus fruits. Contrary to what was believed in the past, a cohort study with 82,737 women suggests that caffeine may have a protective effect on rosacea, reducing symptoms by inducing a vasoconstrictor and immunosuppressive response.[79] The influence of milk and dairy products is controversial, with a possible negative correlation, suggesting that they are protective in the erythematotelangiectatic and papulopustular phenotypes.[19] Daily consumption of tomatoes and citrus fruits was reported by more than half of the studied population, although they were not mentioned as aggravating factors. To date, there is no evidence that eliminating certain foods results in an improvement in rosacea symptoms.[78] However, for Brazilians, this study suggests that the consumption of alcoholic beverages and diets containing pepper may be important in worsening the disease, based on the frequency of ingestion and the patient's perception.

This study has limitations, especially related to the lack of a control group, the inclusion of patients from referral centers, and the fact that many were undergoing treatment. Other observational studies and, mainly, population-based studies are necessary to confirm the findings presented herein.

Conclusion

The higher prevalence of rosacea in phototypes III and IV in the Brazilian sample studied demonstrates the need for dermatologists to be alert to signs of the disease, since diagnosis may be delayed in higher phototypes.

The assessment of comorbidities plays a fundamental role, particularly regarding overweight and obesity. Cardiovascular, psychiatric, neurodegenerative, gastrointestinal, neurological, oncological, endocrinological, and autoimmune diseases were detected, demonstrating that the

identification of these comorbidities can allow screening and adequate monitoring of patients.

Gastrointestinal manifestations were highly prevalent, corroborating the possible relationship between rosacea, microbiome and gastrointestinal tract diseases (gut-skin axis).

The quality of life impairment and high prevalence of psychiatric diseases demonstrate the importance of addressing these aspects.

In the present sample, certain foods and the use of alcoholic beverages were mentioned as aggravating factors of the disease, and specific research is required to determine the impact of diet on rosacea.

This study presents real data from different regions of Brazil, which may contribute to the development of algorithms for the holistic management of patients with rosacea.

Editor

Sílvio Alencar Marques.

Research data availability

The entire dataset supporting the results of this study was published in this article.

Financial support

FIPE (Fundo de Incentivo à Pesquisa e Eventos – Hospital de Clínicas de Porto Alegre, Brazil).

Authors' contributions

Renan Rangel Bonamigo: Design and planning of the study; collection and analysis of data; drafting and editing of the manuscript; review of the literature; approval of the final version of the manuscript.

Paula Barea: Collection and analysis of data; assembly of the database; drafting and editing of the manuscript; review of the literature; approval of the final version of the manuscript.

Juliano Peruzzo: Design and planning of the study; collection and analysis of data; drafting and editing of the manuscript; review of the literature; approval of the final version of the manuscript.

Juliana Boza: Design and planning of the study; collection and analysis of data; drafting and editing of the manuscript; review of the literature; approval of the final version of the manuscript.

Hélio Amante Miot: Design and planning of the study; collection of data; drafting and editing of the manuscript; review of the literature; approval of the final version of the manuscript.

Edileia Bagatin: Design and planning of the study; collection of data; drafting and editing of the manuscript; review of the literature; approval of the final version of the manuscript.

Luiz Maurício Costa Almeida: Design and planning of the study; collection of data; drafting and editing of the manuscript; review of the literature; approval of the final version of the manuscript.

Giovanni Indelicato Milano: Collection of data; drafting and editing of the manuscript.

Carla Wanderley Gayoso de Lima: Design and planning of the study; collection of data; drafting and editing of the manuscript; review of the literature; approval of the final version of the manuscript.

Linácia Freitas Vidal: Collection of data; drafting and editing of the manuscript.

Fabiola Rosa Picosse: Design and planning of the study; collection of data; drafting and editing of the manuscript; review of the literature; approval of the final version of the manuscript.

Bruna Manuella de Figueiredo Afonso: Collection of data; drafting and editing of the manuscript.

Clivia Maria Moraes de Oliveira: Design and planning of the study; collection of data; drafting and editing of the manuscript; review of the literature; approval of the final version of the manuscript.

Conflicts of interest

Renan Rangel Bonamigo: None declared.

Paula Baréa: None declared.

Juliano Peruzzo: None declared.

Juliana Boza: None declared.

Hélio Miot: Advisory Board – Johnson & Johnson, L'Oréal, Theraskin, Sanofi and Pfizer; Clinical Research – Abbvie, Pierre Fabre; Galderma and Merz.

Edileia Bagatin: Farmoquímica/Melora, Beiersdorf/Eucerin, L'Oreal (Vichy/La Roche Posay, Pierre-Fabre (Avene, Ducray), Theraskin, Allergan/Abbvie, USK, LeoPharma, Ache, Pechoin.

Luiz Mauricio Costa Almeida: Advisory Board – Galderma, Beiersdorf, L'Oreal, Leo Pharma, FQM Melora, Pierre Fabre and Bayer.

Giovanni Indelicato Milano: None declared.

Carla Wanderley Gayoso de Lima: None declared.

Linácia Freitas: None declared.

Fabíola Rosa Picosse: None declared.

Bruna Manuella de Figueiredo Afonso: None declared.

Clivia Maria Moraes de Oliveira: Janssen, Novartis, Sanofi, Abbvie, Galderma, L'Oreal, Boehringer.

References

1. Two AM, Wu W, Gallo RL, Hata TR. Rosacea: part I. Introduction, categorization, histology, pathogenesis, and risk factors. J Am Acad Dermatol. 2015;72:749–58.
2. Spoendlin J, Voegel JJ, Jick SS, Meier CR. A study on the epidemiology of rosacea in the U.K. Br J Dermatol. 2012;167:598–605.
3. Tan J, Berg M. Rosacea: current state of epidemiology. J Am Acad Dermatol. 2013;69:S27–35.
4. Gether L, Overgaard LK, Egeberg A, Thyssen JP. Incidence and prevalence of rosacea: a systematic review and meta-analysis. Br J Dermatol. 2018;179:282–9.
5. Suarez MV, Francesconi F, Gonçalves H, Dal Forno T, Ribeiro BDM, Mulinari-Brenner F, et al. Epidemiological profile of rosacea in dermatology outpatient clinics in Brazil: an observational report

from the Brazilian study group on rosacea. Eur J Dermatol. 2023;33:6–11.
6. Gupta AK, Chaudhry MM. Rosacea and its management: an overview. J Eur Acad Dermatol Venereol. 2005;19:273–85.
7. Steinhoff M, Schmelz M, Schauber J. Facial erythema of rosacea — aetiology, different pathophysiologies and treatment options. Acta Derm Venereol. 2016;96:579–86.
8. Webster G, Schaller M. Ocular rosacea: a dermatologic perspective. J Am Acad Dermatol. 2013;69:S42–43.
9. Tan J, Almeida LMC, Bewley A, Cribier B, Dlova NC, Gallo R, et al. Updating the diagnosis, classification and assessment of rosacea: recommendations from the global ROSacea COnsensus (ROSCO) panel. Br J Dermatol. 2017;176:431–8.
10. Gallo RL, Granstein RD, Kang S, Mannis M, Steinhoff M, Tan J, et al. Standard classification and pathophysiology of rosacea: the 2017 update by the National Rosacea Society Expert Committee. J Am Acad Dermatol. 2018;78:148–55.
11. van Zuuren EJ, Fedorowicz Z, Tan J, van der Linden MMD, Arents BWM, Carter B, et al. Interventions for rosacea based on the phenotype approach: an updated systematic review including GRADE assessments. Br J Dermatol. 2019;181:65–79.
12. Thiboutot D, Anderson R, Cook-Bolden F, Draelos Z, Gallo RL, Granstein RD, et al. Standard management options for rosacea: the 2019 update by the National Rosacea Society Expert Committee. J Am Acad Dermatol. 2020;82:1501–10.
13. Aksoy B, Altaykan-Hapa A, Egemen D, Karagöz F, Atakan N. The impact of rosacea on quality of life: effects of demographic and clinical characteristics and various treatment modalities. Br J Dermatol. 2010;163:719–25.
14. Incel Uysal P, Akdogan N, Hayran Y, Oktem A, Yalcin B. Rosacea associated with increased risk of generalized anxiety disorder: a case-control study of prevalence and risk of anxiety in patients with rosacea. An Bras Dermatol. 2019;94:704–9.
15. Dai R, Lin B, Zhang X, Lou Y, Xu S. Depression and anxiety in rosacea patients: a systematic review and meta-analysis. Dermatol Ther (Heidelb). 2021;11:2089–105.
16. Chang ALS, Raber I, Xu J, Li R, Spitale R, Chen J, et al. Assessment of the genetic basis of rosacea by genome-wide association study. J Invest Dermatol. 2015;135:1548–55.
17. Forton FMN. The pathogenic role of demodex mites in rosacea: a potential therapeutic target already in erythematotelangiectatic rosacea? Dermatol Ther. 2020;10:1229–53.
18. Weiss E, Katta R. Diet and rosacea: the role of dietary change in the management of rosacea. Dermatol Pract Concept. 2017;7:31–7.
19. Yuan X, Huang X, Wang B, Huang YX, Zhang YY, Tang Y, et al. Relationship between rosacea and dietary factors: a multicenter retrospective case-control survey. J Dermatol. 2019;46:219–25.
20. Hayran Y, Lay I, Mocan MC, Bozduman T, Ersoy-Evans S. Vascular endothelial growth factor gene polymorphisms in patients with rosacea: a case-control study. J Am Acad Dermatol. 2019;81:348–54.
21. Trompezinski S, Pernet I, Mayoux C, Schmitt D, Viac J. Transforming growth factor-beta1 and ultraviolet A1 radiation increase production of vascular endothelial growth factor but not endothelin-1 in human dermal fibroblasts. Br J Dermatol. 2000;143:539–45.
22. Yamasaki K, Kanada K, Macleod DT, Borkowski AW, Morizane S, Nakatsuji T, et al. TLR2 expression is increased in rosacea and stimulates enhanced serine protease production by keratinocytes. J Invest Dermatol. 2011;131:688–97.
23. Muto Y, Wang Z, Vanderberghe M, Two A, Gallo RL, Di Nardo A. Mast cells are key mediators of cathelicidin-initiated skin inflammation in rosacea. J Invest Dermatol. 2014;134:2728–36.
24. Margalit A, Kowalczyk MJ, Żaba R, Kavanagh K. The role of altered cutaneous immune responses in the induction and persistence of rosacea. J Dermatol Sci. 2016;82:3–8.
25. Ahn CS, Huang WW. Rosacea pathogenesis. Dermatol Clin. 2018;36:81–6.
26. Li Y, Xie H, Deng Z, Wang B, Tang Y, Zhao Z, et al. Tranexamic acid ameliorates rosacea symptoms through regulating immune response and angiogenesis. Int Immunopharmacol. 2019;67:326–34.
27. Addor FAS. Skin barrier in rosacea. An Bras Dermatol. 2016;91:59–63.
28. Baldwin H, Alexis A, Andriessen A, Berson D, Harper J, Lain E, et al. Supplement article: skin barrier deficiency in rosacea: an algorithm integrating OTC skincare products into treatment regimens. J Drugs Dermatol. 2022;21:SF3595563–35955610.
29. Alia E, Feng H. Rosacea pathogenesis, common triggers, and dietary role: the cause, the trigger, and the positive effects of different foods. Clin Dermatol. 2022;40:122–7.
30. Haber R, El Gemayel M. Comorbidities in rosacea: a systematic review and update. J Am Acad Dermatol. 2018;78:786–92.e8.
31. Akin Belli A, Ozbas Gok S, Akbaba G, Etgu F, Dogan G. The relationship between rosacea and insulin resistance and metabolic syndrome. Eur J Dermatol. 2016;26:260–4.
32. Bonamigo RR, Bakos L, Cartell A, Edelweiss MI. Fatores associados à rosácea em amostras populacionais do Sul do Brasil: análise de estudos casos-controles. An Bras Dermatol. 2008;83:419–24.
33. Tannus FC, Picosse FR, Soares JM, Bagatin E. Rosacea-specific quality of life questionnaire: translation, cultural adaptation and validation for Brazilian Portuguese. An Bras Dermatol. 2018;93:836–42.
34. Staedtler G, Shakery K, Endrikat J, Nkulikiyinka R, Gerlinger C. An empirically generated responder definition for rosacea treatment. Clin Cosmet Investig Dermatol. 2017;10:347–52.
35. Wilkin J, Dahl M, Detmar M, Drake L, Liang MH, Odom R, et al. Standard grading system for rosacea: report of the National Rosacea Society Expert Committee on the classification and staging of rosacea. J Am Acad Dermatol. 2004;50:907–12.
36. Alexis AF, Callender VD, Baldwin HE, Desai SR, Rendon MI, Taylor SC. Global epidemiology and clinical spectrum of rosacea, highlighting skin of color: review and clinical practice experience. J Am Acad Dermatol. 2019;80:1722–9.e7.
37. Chauhan R, Loewenstein SN, Hassanein AH. Rhinophyma: prevalence, severity, impact and management. Clin Cosmet Investig Dermatol. 2020;13:537–51.
38. Hilbring C, Augustin M, Kirsten N, Mohr N. Epidemiology of rosacea in a population-based study of 161,269 German employees. Int J Dermatol. 2022;61:570–6.
39. Fitzpatrick TB. The validity and practicality of sun-reactive skin types I through VI. Arch Dermatol. 1988;124:869–71.
40. Rueda LJ, Motta A, Pabón JG, Barona MI, Meléndez E, Orozco B, et al. Epidemiology of rosacea in Colombia. Int J Dermatol. 2017;56:510–3.
41. Oliveira CMM, Almeida LMC, Bonamigo RR, Lima CWG, Bagatin E. Consensus on the therapeutic management of rosacea – Brazilian Society of Dermatology. An Bras Dermatol. 2020;95:53–69.
42. Silva TD. Ação afirmativa e população negra na Educação Superior: acesso e perfil discente. Texto para Discussão, No 2569. Brasília: IPEA -; 2020.
43. Breton AL, Truchetet F, Véran Y, Doumat-Batch F, Baumann C, Barbaud A, et al. Prevalence analysis of smoking in rosacea. J Eur Acad Dermatol Venereol. 2011;25:1112–3.
44. Mills CM. Cigarette smoking, cutaneous immunity, and inflammatory response. Clin Dermatol. 1998;16:589–94.
45. Sopori M. Effects of cigarette smoke on the immune system. Nat Rev Immunol. 2002;2:372–7.

46. Misery L. Nicotine effects on skin: are they positive or negative? Exp Dermatol. 2004;13:665–70.
47. Li S, Cho E, Drucker AM, Qureshi AA, Li WQ. Alcohol intake and risk of rosacea in US women. J Am Acad Dermatol. 2017;76:1061–7.e2.
48. Liu L, Xue Y, Chen Y, Pu Y, Zhang Y, Zhang L, et al. Alcohol consumption and the risk of rosacea: a systematic review and meta-analysis. J Cosmet Dermatol. 2022;21:2954–61.
49. Li S, Cho E, Drucker AM, Qureshi AA, Li WQ. Obesity and risk for incident rosacea in US women. J Am Acad Dermatol. 2017;77:1083–7.e5.
50. Aldrich N, Gerstenblith M, Fu P, Tuttle MS, Varma P, Gotow E, et al. Genetic vs environmental factors that correlate with rosacea: a cohort-based survey of twins. JAMA Dermatol. 2015;151:1213–9.
51. Natale F, Cirillo C, Granato C, Concilio C, Siciliano A, Credendino M, et al. Worsening of rosacea in patients treated with dihydropyridine calcium channel blockers: a clinical observation. Hypertens Res. 2011;34:790–1.
52. Spoendlin J, Voegel JJ, Jick SS, Meier CR. Antihypertensive drugs and the risk of incident rosacea. Br J Dermatol. 2014;171:130–6.
53. Son JH, Chung BY, Jung MJ, Choi YW, Kim HO, Park CW. The risk of rosacea according to chronic diseases and medications: a 5-year retrospective, multi-institutional case-control study. Ann Dermatol. 2018;30:676–87.
54. Moustafa F, Lewallen RS, Feldman SR. The psychological impact of rosacea and the influence of current management options. J Am Acad Dermatol. 2014;71:973–80.
55. Juliandri J, Wang X, Liu Z, Zhang J, Xu Y, Yuan C. Global rosacea treatment guidelines and expert consensus points: the differences. J Cosmet Dermatol. 2019;18:960–5.
56. Schaller M, Kemény L, Havlickova B, Jackson JM, Ambroziak M, Lynde C, et al. A randomized phase 3b/4 study to evaluate concomitant use of topical ivermectin 1% cream and doxycycline 40-mg modified-release capsules, versus topical ivermectin 1% cream and placebo in the treatment of severe rosacea. J Am Acad Dermatol. 2020;82:336–43.
57. Barakji YA, Rønnstad ATM, Christensen MO, Zachariae C, Wienholtz NKF, Halling AS, et al. Assessment of frequency of rosacea subtypes in patients with rosacea: a systematic review and meta-analysis. JAMA Dermatol. 2022;158:617–25.
58. Schaller M, Dirschka T, Lonne-Rahm SB, Micali G, Stein Gold LF, Tan J, et al. The importance of assessing burning and stinging when managing rosacea: a review. Acta Derm Venereol. 2021;101:adv00584.
59. Holmes AD, Spoendlin J, Chien AL, Baldwin H, Chang ALS. Evidence-based update on rosacea comorbidities and their common physiologic pathways. J Am Acad Dermatol. 2018;78:156–66.
60. Wollina U. Is rosacea a systemic disease? Clin Dermatol. 2019;37:629–35.
61. Li M, He SX, He YX, Hu XH, Zhou Z. Detecting potential causal relationship between inflammatory bowel disease and rosacea using bi-directional Mendelian randomization. Sci Rep. 2023;13:14910.
62. Searle T, Ali FR, Carolides S, Al-Niaimi F. Rosacea and the gastrointestinal system. Australas J Dermatol. 2020;61:307–11.
63. Wang FY, Chi CC. Rosacea, germs, and bowels: a review on gastrointestinal comorbidities and gut–skin axis of rosacea. Adv Ther. 2021;38:1415–24.
64. Alizada M, Sahin T, Sener O, Kocyigit P. Evaluation of dermatological and neurological aspects of the relationship between rosacea and headaches. Diagnostics (Basel). 2023;14:23.
65. Sinikumpu SP, Vähänikkilä H, Jokelainen J, Tasanen K, Huilaja L. Male patients with rosacea have increased risk for migraine: a population-based study. Br J Dermatol. 2021;185:1058–61.
66. Vera N, Patel NU, Seminario-Vidal L. Rosacea comorbidities. Dermatol Clin. 2018;36:115–22.
67. Mar K, Rivers JK. The mind body connection in dermatologic conditions: a literature review. J Cutan Med Surg. 2023;27:628–40.
68. Thapa L, Xia J, Guo W, Usmani H, Miller D, Lozeau D. Rosacea and its association with malignancy: systematic review. JMIR Dermatol. 2023;6:e47821.
69. Li Y, Guo L, Hao D, Li X, Wang Y, Jiang X. Association between rosacea and cardiovascular diseases and related risk factors: a systematic review and meta-analysis. BioMed Res Int. 2020;2020:7015249.
70. Tsai TY, Chiang YY, Huang YC. Cardiovascular risk and comorbidities in patients with rosacea: a systematic review and meta-analysis. Acta Derm Venereol. 2020;100:adv00300.
71. Zhang J, Yan Y, Jiang P, Liu Z, Liu Y, Liu Y, et al. Association between rosacea and cardiovascular disease: a systematic review and meta-analysis. J Cosmet Dermatol. 2021;20:2715–22.
72. Nowowiejska J, Baran A, Flisiak I. Lipid alterations and metabolism disturbances in selected inflammatory skin diseases. Int J Mol Sci. 2023;24:7053.
73. Yi JZ, Lukac D, Li S, McGee JS. Rosacea and subsequent diagnosis of venous thromboemboliS.m: a large, urban academic center case-control study. J Am Acad Dermatol. 2022;86:1420–2.
74. Oussedik E, Bourcier M, Tan J. Psychosocial burden and other impacts of rosacea on patients' quality of life. Dermatol Clin. 2018;36:103–13.
75. Chernyshov PV, Finlay AY, Tomas-Aragones L, Steinhoff M, Manolache L, Pustisek N, et al. Quality of life measurement in rosacea. Position statement of the European Academy of Dermatology and Venereology task forces on quality of life and patient-oriented outcomes and acne, rosacea and hidradenitis suppurativa. J Eur Acad Dermatol Venereol. 2023;37:954–64.
76. Jaworek AK, Wojas-Pelc A, Pastuszczak M. Aggravating factors of rosacea. Przegl Lek. 2008;65:180–3.
77. Morgado-Carrasco D, Granger C, Trullas C, Piquero-Casals J. Impact of ultraviolet radiation and exposome on rosacea: key role of photoprotection in optimizing treatment. J Cosmet Dermatol. 2021;20:3415–21.
78. Jamgochian M, Alamgir M, Rao B. Diet in dermatology: review of diet's influence on the conditions of rosacea, hidradenitis suppurativa, herpes labialis, and vitiligo. Am J Lifestyle Med. 2021;17:152–60.
79. Li S, Chen ML, Drucker AM, Cho E, Geng H, Qureshi AA, et al. Association of caffeine intake and caffeinated coffee consumption with risk of incident rosacea in women. JAMA Dermatol. 2018;154:1394–400.

SOCIEDADE BRASILEIRA DE DERMATOLOGIA

Anais Brasileiros de Dermatologia

www.anaisdedermatologia.org.br

ORIGINAL ARTICLE

Evaluation of *Tyrosine Kinase-2* (*TYK2*) signaling pathway gene expression and the presence of the single-nucleotide polymorphism rs12720356 in the peripheral blood of patients with severe psoriasis and loss of systemic treatment response☆

Paola Borges Eckstein Canabrava [a], Roll Stanley Beauge [b], Samir de Figueiredo Azouz [a,c], Renata Velozo Timbó [a], Luciana Pereira Freire Martins [b], Bruna Côrtes Rodrigues [a], Naiara Daris dos Santos [a], Marcella Palhano Medeiros [a], Andréa Monteiro de Araújo [a], Agenor de Castro Moreira dos Santos Júnior [a], Carla Nunes de Araújo [a], Otávio de Toledo Nóbrega [a], Patrícia Shu Kurizky [a], Licia Maria Henrique da Mota [a,b], Ciro Martins Gomes [a,b,*]

[a] *Graduate Program in Medical Sciences, School of Medicine, University of Brasília, Brasília, DF, Brazil*
[b] *Graduate Program in Molecular Pathology, School of Medicine, University of Brasília, Brasília, DF, Brazil*
[c] *School of Medicine, Federal University of Paraíba, João Pessoa, PA, Brazil*

Received 13 October 2024; accepted 11 February 2025
Available online 4 August 2025

KEYWORDS
Biomarkers;
Molecular epidemiology;
Psoriasis;
Therapeutics;
TYK2 kinase

Abstract
Background: RNA sequencing-based studies have identified the transcription processes that contribute to psoriasis development, but the associations of these processes with specific phenotypes need further investigation.
Objective: The authors aimed to determine the associations of specific Peripheral Blood Mononuclear Cell (PBMC) endotypic profiles with loss of treatment response in psoriasis patients.
Methods: A Psoriasis Area and Severity Index (PASI) > 10 was the main outcome. The gene expression of *Tyrosine Kinase-2 (TYK)*, *Interleukin (IL)-12A*, *IL-12B*, *IL-23A*, *IL-23 Receptor (IL-23R)*, *IL-6*, *IL-6R*,*IL-17A* and *Tumor Necrosis Factor (TNF)* in PBMCs was quantified as possible risk factors. Single-Nucleotide Polymorphisms (SNP) were screened using a genotyping technique. Hierarchical clustering of the gene expression results was performed.

☆ Study conducted at the Universidade de Brasília, Brasília, DF, Brazil.

* Corresponding author.
E-mail: cirogomes@unb.br (C.M. Gomes).

https://doi.org/10.1016/j.abd.2025.501165

Results: The authors included 178 psoriasis patients. *TYK2* was upregulated in the PBMCs of patients with a PASI score > 10, but its distribution was widely variable. A cluster of 19 patients exhibited upregulated expression of most *TYK2*-dependent mediators and increased PASI (p = 0.021) and Dermatology Life Quality Index (DLQI) scores (p = 0.034). Three patients harbored the TYK2I684S variant.
Study limitations: The utility of using single markers for psoriasis diagnosis is limited due to the wide variability of results, but the utility of the simultaneous evaluation of a set of markers has promise.
Conclusions: The present study suggests an association between multiple TYK2 pathway markers and loss of systemic treatment response.

Introduction

The exact pathophysiology of psoriasis is still unknown and involves a combination of genetic and environmental factors.[1] One of the key features of psoriasis is the abnormal production of cytokines both systemically and in skin lesions.[2] Previous studies have identified genes associated with the risk of psoriasis, such as polymorphisms in the genes that encode the *P19* and *p40* subunits of *IL-23* and I*L-12*/*IL-23*, respectively.[3–5]

RNA sequencing (RNA-seq) and microarray techniques have been used to identify various genes involved in transcription-mediated disease processes.[6,7] However, these techniques may not be effective in detecting wide variations in gene expression.[8] Therefore, further investigations are needed because the direct relationship between genetic and clinical findings in psoriasis patients is still unknown.[9,10]

Although new medications that target the cytokines involved in psoriasis are available, treatment choices are almost exclusively dependent on the clinical assessment of the disease.[11–13] Biomarkers are measurable signs that can indicate the presence or severity of a disease.[14] In dermatology, most of these markers are measured in skin samples, but the collection of sequential skin biopsies may be unfeasible.[15–17] In psoriasis patients, many traditional blood markers, particularly those used to detect inflammation (C-reactive protein and erythrocyte sedimentation), have been tested, but the results have been inconclusive.[18]

The primary aim of the current study was to identify specific endotypic profiles of Peripheral Blood Mononuclear Cells (PBMCs) involved in the *Tyrosine Kinase-2* (*TYK2*) signaling pathway and the frequency of the protective psoriasis-related Single-Nucleotide Polymorphism (SNP) rs12720356 and their relationship with the loss of systemic treatment response in psoriasis patients.

Materials and methods

Study design and recruitment

This report complies with the Strengthening the Reporting of Observational Studies in Epidemiology – Molecular Epidemiology (STROBE-ME) guidelines.[14] The study was conducted in a tertiary center for the treatment of patients with psoriasis at the University Hospital of Brasília, which is located in Brasília, Brazil. This center is responsible for a population of more than a million people, and patients are referred from secondary facilities.

From November 1st, 2022, to December 1st, 2023, the authors included consecutive patients attending the Psoriasis Ambulatory Department. To form the main analysis group, the authors included patients who were regularly followed up at the University Hospital of Brasília and who had a confirmed history of severe psoriasis vulgaris (International Classification of Diseases 10th Revision [ICD10 = L40.0]) (Psoriasis Area and Severity Index [PASI > 10] or Dermatology Life Quality Index [DLQI > 10]) and who subsequently achieved disease remission (PASI or DLQI < 5) for at least 1-year after the use of methotrexate or biologics. Consecutive psoriasis patients who were referred to this specialized dermatological center during the same period and who were not receiving systemic treatment were also included to form a comparator group. Twenty healthy controls matched for sex and age to psoriasis patients were also included (convenience sampling) for comparison. The authors excluded patients who had any other autoimmune conditions (except for psoriatic arthritis), pregnant women, or indigenous individuals. All mutation and gene expression tests were conducted on every patient.

After signing an informed consent form, all patients completed a comprehensive questionnaire aimed at gathering detailed clinical information. The information requested included age, sex, time since psoriasis diagnosis and previous medications used for the treatment of psoriasis. All patients were also examined by 2 board-certified dermatologists who collected data related to the type and severity of psoriasis (PASI and DLQI scores).

Definition of loss of systemic treatment response

In the main analysis group, all psoriasis patients were regularly followed up for more than a year and had previously achieved a satisfactory clinical response to systemic treatment. Upon inclusion in the study, patients were divided into two main groups: 1) Those who developed a loss of systemic treatment response (defined as the recurrence of one or both of the following scores – PASI > 10 or DLQI > 10 – after previously effective treatment) and 2) Those who continued to have a sustained effective response to systemic treatment. Although the group of patients who did not receive any systemic treatment was also divided into

patients with a PASI or DLQI > 10 or not, the term ''loss of systemic treatment response'' was not used for this group.

Clinical samples

The authors collected 20 ml of whole blood from the study participants in 2 heparin tubes. Immediately after collection, PBMCs were isolated using a Ficoll Paque Plus (Merck KGaA, Darmstadt, Germany) gradient. The samples were stored in RNA Later (Thermo Fisher Scientific, Waltham, United States) at −80 °C until RNA extraction, which was performed up to 1-month after sample collection. Whole blood and plasma were also stored at −80 °C.

Gene expression analysis

Total RNA from PBMCs was extracted using the mirVana™ PARIS™ RNA and Native Protein Purification Kit (Thermo Fisher Scientific, Waltham, United States). The purified RNA was quantified with a NanoDrop One/OneC UV–vis spectrophotometer (Thermo Fisher Scientific). Samples were treated with RNase-free DNase I (1 U/μl) (Thermo Fisher Scientific). Complementary DNA (cDNA) was generated using a High-Capacity cDNA Reverse Transcription Kit (Thermo Fisher Scientific) in a T100 Thermal Cycler (Bio-Rad, Hercules, United States) according to the manufacturer's instructions.

Messenger RNA (mRNA) expression analysis was performed using TaqMan-based manufactured probes (Thermo Fisher Scientific) labeled with 5'Fluorescein Amidite (FAM) and 3′Minor Groove Binder (MGB) probes. The authors measured the expression of the *TYK2*, *IL-12A*, *IL-12B*, *IL-23A*, *IL-23* receptor, *IL-6*, *IL-6R*, *IL-17A* and *Tumor Necrosis Factor (TNF)* genes using probes that spanned exon junctions. Despite the primary objective of this study being the evaluation of cytokines in the *IL-23* axis and other activators of the *TYK2* receptors, effector cytokines such as *TNF* and *IL-17A* were additionally measured to assess and compare the activation of the entire Th1 and Th17 stimulation pathway. Three target candidates, namely, *Glyceraldehyde-3-Phosphate Dehydrogenase (GAPDH)*, *eukaryotic 18S rRNA* and *beta actin*, were screened for use as endogenous controls, and *GAPDH* was selected. For each assay, the genes analyzed are detailed in Supplementary Table 1.

Reactions were performed in a QuantStudio 5 Thermocycler (Thermo Fisher Scientific). The reaction was initiated at 50 °C for 2 min, followed by 95 °C for 10 min (polymerase activation) and 40 PCR cycles of 95 °C for 15 s and 60 °C for 60 s. Reactions were performed in a final volume of 15 μl comprising 1× TaqMan™ Gene Expression Master Mix (Thermo Fisher Scientific, Waltham, United States), 1× TaqMan-based probes, 2 μl of cDNA sample from each patient and ultrapure water. All the samples were tested in triplicate. For normalization, the authors used a reference sample (calibrator) formed from a pool of total RNA extracted from the PBMCs of the 20 included healthy controls. No-template controls were also used for comparison.

The authors used the comparative Ct (ΔΔCt) method for data analysis. The individual results are reported as the Relative Quantification (RQ) of gene expression (fold change). Calculations were performed with Applied Biosystems™ Analysis Software (Thermo Fisher Scientific). Values of each expression considered inaccurate are suppressed by the analysis software.

TYK2 gene variant analyses

The authors chose a robust manufactured assay that precisely detects the psoriasis-related protective Single-Nucleotide Polymorphism (SNP) rs12720356.19 This SNP was the only SNP in the *TYK2* gene that was found to be related to psoriasis and that was reproduced in more than one scientific article, according to a previous systematic review of the literature and meta-analysis.[19] The kit uses multiplex qPCR with [VIC/FAM] probes to detect the following mutation in the *TYK2* gene: GTGCTCCACGTACTCT-GTCACCATG[A/C]TATCTGTAAAGACACAGCTGCTCTG, located on chromosome 19:10359299 on build GRCh38. Transcripts of this region are similar to those of the target tested for *TYK2* gene expression.

Genomic DNA from whole blood was extracted using the PureLink™ Genomic DNA Mini Kit (Thermo Fisher Scientific). The genotyping mixture included 1× TaqPath™ ProAmp™ Master Mix (Thermo Fisher Scientific), 1× TaqMan™ SNP Genotyping (Thermo Fisher Scientific, Waltham, United States) (CN: C_34042925_10, 4351379), 20 ng of genomic DNA and ultrapure water in a final volume of 25 μl. Reactions were performed in a QuantStudio 5 Thermocycler (Thermo Fisher Scientific). The cycling conditions comprised a preread step of 30 s at 60 °C, followed by an initial denaturation/enzyme activation step of 5 min at 95 °C; 40 cycles of denaturation (15 s at 95 °C) and annealing/extension (60 s at 60 °C); and a post read step of 30 s at 60 °C.

Cytometric bead array assay

The plasma levels of TNF-α, IL-10, IL-1β, IL-8, IL-6 and IL-12p70 in the first 80 included patients were measured using the Human Inflammatory Cytokine Cytometric Bead Array (CBA)-I Kit (RUO) (Becton Dickinson, Franklin Lakes, USA) and a FACSVerse flow cytometer (Becton Dickinson).

Statistical analysis

For initial statistical analysis, the authors considered the PASI score the main outcome and divided patients into two groups: those with a PASI > 10 and those with a PASI ≤ 10. Another important outcome was the loss of systemic treatment response, defined by a PASI or DLQI score > 10.

The authors explored the differences in the RQs of gene expression and clinical characteristics. Subsequently, the authors applied hierarchical cluster techniques and heatmaps to find groups of patients who could represent a different endotypic profile of individuals experiencing loss of systemic treatment response. The assumptions for multivariate analysis were not met, and this analysis was determined to be unreliable.

The clinical relevance of gene expression changes was defined as a minimum 2× difference in gene expression (RQ) between groups.[20,21] A p-value < 0.05 indicated statistical significance. Whenever statistical significance was met for

RQ, the authors applied Benjamini-Hochberg False Discovery Rate (FDR) adjustment. Statistical analysis was performed using the program R version 4.1.2 (R Core Team [2021]). R: A language and environment for statistical computing. R Foundation for Statistical Computing, Vienna, Austria. URL https://www.R-project.org/).

Ethics

All patients were included after signing an informed consent form. This study complied with the Declaration of Helsinki and was approved by the Ethics Committee of the Faculty of Medicine of the University of Brasília, Brazil (CAAE: 68068323.3.1001.5558).

Results

Clinical profile of the included participants

The authors enrolled 198 participants in this study, including 162 patients with psoriasis who had previously achieved disease remission using systemic medications, 16 patients with psoriasis who were not receiving any systemic treatment, and 20 healthy controls. Twenty-seven psoriasis patients exhibited a PASI score > 10 (the main dependent variable), and another 32 patients exhibited DLQI scores > 10. The data in Supplementary Table 2 show that sex, age and disease duration were not different between patients with PASI scores > 10 and those with PASI scores $\leq$ 10.

Regarding the medication used by each patient at recruitment, 21 were using methotrexate, 83 were using anti-TNF biologics (5 etanercept, 7 infliximab, and 71 adalimumab), 17 were using anti-IL-12/23 biologics (ustekinumab), 7 were using anti-IL-23 biologics (5 risankizumab and 2 guselkumab), 34 were using anti-IL-17 biologics (secukinumab) and 16 were not using any systemic treatment. The authors did not detect a PASI > 10 in patients treated with anti-IL-23 biologics (n = 7) (Supplementary Table 3).

The percentage of patients who experienced a loss of systemic treatment response (PASI or DLQI score > 10) did not differ among those receiving different systemic treatments ($p > 0.05$). The number of patients with a PASI or DLQI > 10 was greater among those who did not receive systemic treatment than among patients who received anti-TNF biologics, anti-IL-17 biologics, anti-IL12/23 biologics or anti-IL-23 biologics ($p < 0.05$) (Supplementary Table 3).

Gene expression analysis revealed upregulation of TYK2 pathway genes in patients with PASI scores >10

The authors found a positive correlation between *TYK2* gene expression RQ and *IL-12A*, *IL-23A* or *IL-23R* expression ($p < 0.05$) (Supplementary Fig. 1). Compared with that in the PBMCs of healthy controls, the RQ gene expression of most mediators was similar or reduced in the PBMCs of psoriasis patients. Similar results were found via CBA analysis (Supplementary Tables 4–8).

TYK2 gene expression in PBMCs was upregulated in patients with a PASI > 10 (Table 1). FDR correction revealed that, in isolation, *TYK2* RQ gene expression could not differentiate patients with a PASI greater than 10 from those with a PASI less than or equal to 10. This result is probably due to the very wide range of RQ gene expression (Supplementary Fig. 2). Additionally, the authors did not find any relationship between *TYK2* gene expression and other demographic or clinical characteristics (Supplementary Table 9).

Hierarchical clustering detected a subgroup of upregulated TYK2 pathway genes

For our hierarchical clustering analysis, the authors included only patients who had RQ values less than 2 standard deviations apart from all mediators tested (Fig. 1). The authors included 55 patients in this analysis (Tables 2 and 3). The authors identified a group of 19 patients with increased expression of mediators of the TYK2 signaling pathway. *IL-12A*, *IL-12B*, *IL-23A*, *IL-23R*, and *IL-6* were upregulated in this group (Table 2). This group of patients also presented higher PASI ($p = 0.021$) and DLQI ($p = 0.034$) scores than those with lower *TYK2* mediator expression (Table 3). Patients in this group who exhibited increased expression of mediators of the *TYK2* signaling pathway and also loss of systemic treatment response were using methotrexate, anti-TNF agents and anti-IL-17 biologics but not anti-IL-12/23 or anti-IL-23 biologics (Supplementary Table 10). The remaining patients did not exhibit a gene expression pattern in PBMCs that could distinguish them from other patients (n = 36) (Fig. 1).

Genotyping the TYK2 gene

Three patients (1.69%) were heterozygous for the rs12720356 SNP identified in the *TYK2* gene (Supplementary Fig. 3). This mutation is also known as the *TYK2* I684S variant.[22] Of the 3 patients carrying the *TYK2* I684S variant, 2 were females, 2 had associated nail psoriasis, and 1 had palmoplantar lesions. All 3 patients had a PASI value < 10. Because the frequency of this SNP was low, it was not possible to relate these findings to the measured gene expression. No mutations were found in healthy controls.

Discussion

The *TYK2* gene has recently received substantial attention because of its clinical and therapeutic importance in psoriasis.[3,4] TYK2 is a tyrosine kinase that belongs to the JAK family. The gene is located on chromosome 19p13 and encodes a kinase that promotes *IL-17* transcription via STAT3 phosphorylation, playing a critical role in the pathogenic CD4 T-cell response.[23] Fig. 2 shows a schematic of the influence of circulating CD4+ or CD8+ T-cells on the inflammatory loop in psoriasis.

The authors quantified the gene expression of mediators involved in the *TYK2* pathway and related them to a specific phenotype of psoriasis. The authors found that compared with healthy controls, psoriasis patients had similar or downregulated *TYK2* pathway RQ gene expression in their PBMCs, regardless of whether they underwent treatment with systemic medications. This systemic downregulation has previously been described in microarray studies includ-

Table 1 Median relative quantification of gene expression (fold change) of mediators according to the psoriasis severity index classification.

Association direction (Clinical relevance)		PASI > 10 × PASI < 10 psoriasis patients				PASI > 10 × PASI <10 psoriasis patients × healthy controls	
		PASI > 10	PASI ≤ 10	p-value	FDR correction	Healthy Controls	p-value[b]
		Median (IQR)	Median (IQR)				
TYK2	+	29.23 (66.82)	9.85 (27.92)	0.027[a]	0.243	34.86 (302.45)	0.292
IL-12A	–	26.20 (94.14)	15.58 (40.47)	0.282	0.635	28.63 (160.45)	0.770
IL-12B	+	390.30 (2290.73)	116.29 (1275.15)	0.129	0.438	326.67 (574.00)	0.345
IL-23A	–	12.54 (17.71)	11.66 (19.88)	0.741	0.953	36.17 (19.73)	0.838
IL-23R	–	18.14 (25.03)	9.83 (18.67)	0.366	0.659	27.46 (168.96)	0.310
IL-6	–	35.096 (229.57)	66.19 (155.49)	0.959	0.959	30.23 (567.87)	0.698
IL-6R	–	2.62 (29.65)	1.37 (9.96)	0.146	0.438	1.43 (2.22)	0.165
TNF-α	–	100.41 (337.33)	73.07 (267.18)	0.900	959	203.35 (513.91)	0.911
IL17-A	–	142.92 (1647.96)	77.45 (952.37)	0.465	0.698	137.69 (201.50)	0.345

TYK2, *Tyrosine Kinase-2*; IL, Interleukin; R, Receptor; PASI, Psoriasis Area Severity Index; FDR, False Discovery Rate controlled using the Benjamini-Hochberg method; IQR, Interquartile Range; +, Clinically relevant upregulation according to the relative quantification presenting a minimum of 2× positive association; -, Clinically relevant downregulation according to the relative quantification presenting a minimum of 2× negative association; –, No association.

[a] $p < 0.05$.

[b] No significant difference was observed between the gene expression levels of healthy controls compared to psoriasis subgroups divided by the PASI value.

ing a limited number of patients.[24] In patients treated with systemic drugs, immunological suppression is expected. However, in patients without systemic treatment, decreased expression of mediators in PBMCs may be a result of increased adhesion of circulating effector mononuclear cells to local skin inflammation, resulting in depletion of these cells.[25]

In the second step, the authors found that *TYK2* gene expression was upregulated in the PBMCs of psoriasis patients with a PASI > 10. However, the range of *TYK2* RQ gene expression was very wide, preventing the use of this marker alone to identify loss of systemic treatment response. Next, the authors used hierarchical clustering to reveal that 19 out of 55 patients evaluated in this step exhibited clear upregulation of genes involved in the TYK2-dependent signaling pathway. These patients had higher PASI and DLQI scores (Table 3). Although the number of patients using anti-IL-23 medications was only 7, it is noteworthy that in the total population, no patient using anti-IL-23 biologics had a PASI greater than 10, although some of them had a DLQI greater than 10. This result is consistent with previous clinical trials that demonstrated an impressive PASI-dependent response in patients using IL-23 blockers.[26,27]

The authors found 3 patients who were heterozygous for a protective psoriasis-related SNP, also known as the TYK2 I684S variant. This variant results in a reduction in phosphorylated (p)-STAT4 levels after IL-12 induction[4] and in the function of CD4+ and CD8+ T-cells in PBMCs. The frequency of the *TYK2* I684S variant varies from 1% to 9% in the population.[28] The authors assessed the association between the upregulation of mediators involved in the canonical activation of *TYK2* (*IL-12A, IL-12B, IL-23A, IL-23R, IL-6* and *IL-6R*) and specific phenotypes and identified a cluster of patients with psoriasis who did not use anti-IL-12/23 or anti-IL-23 medications and who exhibited greater PASI scores. Individual markers were not useful for phenotypic psoriasis association, but the utility of the simultaneous evaluation of a set of markers has promise.[29] Other limitations of the study must be acknowledged, including the potential for confounding factors, which are an inevitable concern in any observational study. While such factors could indeed cause worry, all subgroup analyses conducted in this article indicated a significant upregulation of the inflammatory TYK2-dependent pathway in patients who exhibited a loss of response to systemic treatments.

Although this study is one of the largest of its kind to explore complex gene expression analysis in the blood of psoriasis patients, the relatively modest sample size, particularly among patients using IL-23 blockers, must be taken into account. Nonetheless, the findings presented here underscore the necessity for future clinical trials to investigate the efficacy of TYK2 inhibition in bio-experienced psoriasis patients, especially those currently using the most effective biological drugs available on the market. These

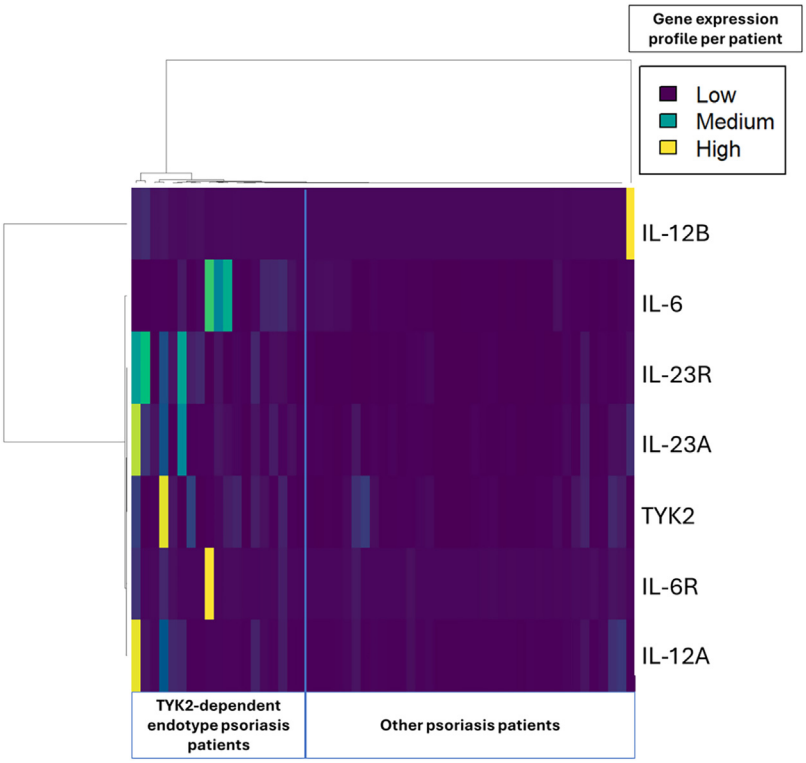

Fig. 1 The image displays a heatmap of the gene expression of mediators that belong to the *TYK2* signaling pathway. The data are derived from 55 psoriasis patients who had all the necessary measurements taken in their peripheral mononuclear cells and for whom the replicate results were within 2 standard deviations. This graphic was generated using the program R version 4.1.2 (R Core Team (2021)). R: A language and environment for statistical computing. R Foundation for Statistical Computing, Vienna, Austria. URL https://www.R-project.org/). TYK2, Tyrosine Kinase-2; IL, Interleukin; R, Receptor.

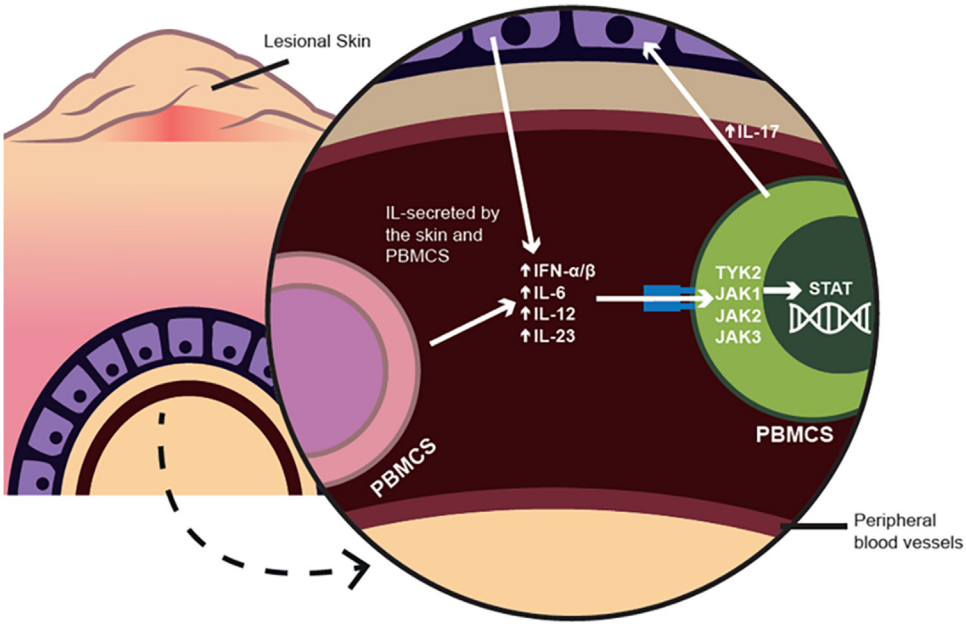

Fig. 2 This schematic presents the influence of CD4+ or CD8+ T-cells on peripheral blood mononuclear cells and their influence on the inflammatory loop in psoriasis patients. IL, Interleukin; PBMCS, Peripheral blood mononuclear cells; IFN, Interferon; TYK, Tyrosine kinase; JAK, Janus kinase; STAT, Signal transducer and activator of transcription.

Table 2 Median relative quantification of gene expression (fold change) of mediators between 2 different endotypic clusters of psoriasis patients identified in this study and healthy controls.

	TYK2- dependent endotype x other psoriasis patients					FDR correction	TYK2- dependent endotype × other psoriasis patients × healthy controls p-value[b]
	Association direction (Clinical relevance)	TYK2-dependent endotype Median (IQR)	Other Median (IQR)	p-value	Healthy Controls		
TYK2	+	25.19 (61.98)	10.12 (22.64)	0.150	0.150	34.86 (302.45)	0.241
IL-12A	+	23.34 (104.99)	11.44 (20.36)	0.005[a]	0.008[a]	28.63 (160.45)	0.259
IL-12B	+	1185.79 (5021.12)	59.25 (216.01)	<0.001[a]	0.002[a]	326.67 (574.00)	0.312
IL-23A	+	21.29 (23.0510)	6.52 (8.68)	<0.001[a]	0.002[a]	36.17 (19.73)	0.141
IL-23R	+	32.25 (64.88)	6.83 (12.79)	<0.001[a]	0.002[a]	27.46 (168.96)	0.063
IL-6	+	163.85 (559.28)	42.52 (115.48)	0.002[a]	0.003[a]	30.23 (567.87)	0.150
IL-6R	–	2.45 (9.70)	1.31 (2.98)	0.141	0.150	1.43 (2.22)	0.347
TNF-α	+	193.09 (457.85)	39.06 (112.66)	0.091	0.117	203.35 (513.91)	0.199
IL17-A		1153.41 (5288.85)	47.47 (228.30)	<0.001	0.002	137.69 (201.50)	0.094

TYK2, Tyrosine Kinase-2; IL, Interleukin; R, Receptor; PASI, Psoriasis Area Severity Index; FDR, False Discovery Rate controlled using the Benjamini-Hochberg method; IQR, Interquartile Range; +, Clinically relevant upregulation according to the relative quantification presenting a minimum of 2× positive association; -, Clinically relevant downregulation according to the relative quantification presenting a minimum of 2× negative association; –, no association.

[a] $p < 0.05$.

[b] No significant difference was observed between the gene expression levels of healthy controls compared to psoriasis subgroups divided by the TYK2-dependent endotype.

Table 3 Comparison of demographic and clinical characteristics between the 2 different endotypic clusters of psoriasis patients identified in this study.

	TYK2-dependent endotype	Other psoriasis patients	p-value
Sex (n)			0.623
Female	9	21	
Male	10	15	
Age Median (IQR)	55.00 (21.50)	46.50 (23.25)	0.190
Loss of systemic treatment response (n)[a]	9	10	0.087
PASI > 10 (n)	6	6	0.352
PASI > 5 (n)	10	7	0.026[a]
PASI Median (IQR)	5.6 (8.65)	0.6 (2.50)	0.021[a]
DLQI Median (IQR)	12.00 (15)	1.50 (8)	0.034[a]
Ungual involvement (n)	8	8	0.218
Scalp involvement (n)	6	10	1.000
Genital involvement (n)	5	8	0.749
Palmoplantar involvement (n)	6	10	1.000
Psoriatic arthritis (n)	4	13	0.360
Total (n)	19	36	

TYK2, Tyrosine Kinase-2; n, Number of patients; IQR, Interquartile Range; PASI, Psoriasis Area Severity Index.

[a] $p < 0.05$.

trials could potentially pave the way for more tailored and efficacious treatment options, bringing renewed hope to patients grappling with this challenging condition.

Recent treatment developments for psoriasis have focused on the TYK2-dependent immunological response. Deucravacitinib is an oral, selective, allosteric TYK2 inhibitor that is licensed for plaque psoriasis treatment in

some countries.[30] Our study revealed that TYK2 pathway activity may be upregulated in patients who do not respond to anti-TNF and anti-IL-17 biologics. This finding suggests that deucravacitinib could be a promising option for patients who require second or third-line treatment.

The successful relation of previously described genotypes to the clinical phenotypes of a group of psoriasis patients who experienced a loss of systemic treatment response reinforces the importance of simultaneously assessing multiple molecular markers for the development of new tools for the evaluation of psoriasis patients.

Editor

Luciana P. Fernandes Abbade.

Financial support

This work was supported by the Fundação de Apoio a Pesquisa do Distrito Federal No. 00193-00000279/2023-70, Brazil. The funders had no role in the study design, data collection and analysis, decision to publish, or preparation of the manuscript.

Authors' contributions

Paola Borges Eckstein Canabrava:
Conceptualization, Investigation.
Roll Stanley Beauge:
Investigation.
Samir de Figueiredo Azouz:
Investigation.
Renata Velozo Timbó:
Software, Validation, Formal analysis.
Luciana Pereira Freire Martins:
Software, Validation, Formal analysis.
Bruna Côrtes Rodrigues:
Software, Validation.
Naiara Daris dos Santos:
Investigation.
Marcella Palhano Medeiros:
Investigation, Validation.
Andréa Monteiro de Araújo:
Data curation.
Agenor de Castro Moreira dos Santos:
Methodology.
Carla Nunes de Araújo:
Investigation, Software, Formal analysis.
Otávio de Toledo Nóbrega:
Investigation, Software, Formal analysis.
Patrícia Shu Kurizky:
Investigation.
Licia Maria Henrique da Mota:
Methodology, Resources.
Ciro Martins Gomes:
Investigation, Supervision, Project administration.

Research data availability

The entire dataset supporting the results of this study was published in this article.

Conflicts of interest

None declared.

Acknowledgments

The authors would like to express our sincere gratitude to the staff at the University Hospital of Brasília for their unwavering support for the successful completion of this research.

Appendix A. Supplementary material

Supplementary material related to this article can be found, in the online version, at doi:https://doi.org/10.1016/j.abd.2025.501165.

References

1. Armstrong AW, Read C. Pathophysiology, clinical presentation, and treatment of Psoriasis:a review. JAMA. 2020;323:1945–60.
2. Boehncke WH. Systemic inflammation and cardiovascular comorbidity in Psoriasis patients: causes and consequences. Front Immunol. 2018;9:579.
3. Strange A, Capon F, Spencer CC, Knight J, Weale ME, et al., Genetic Analysis of Psoriasis Consortium & the Wellcome Trust Case Control Consortium 2. Genome-wide association study identifies new psoriasis susceptibility loci and an interaction between HLA-C and ERAP1. Nat Genet. 2010;42:985–90.
4. Enerbäck C, Sandin C, Lambert S, Zawistowski M, Stuart PE, Verma D, et al. The psoriasis-protective TYK2 I684S variant impairs IL-12 stimulated pSTAT4 response in skin-homing CD4+ and CD8+ memory T-cells. Sci Rep. 2018;8:7043.
5. Puig L, Julià A, Marsal S. The pathogenesis and genetics of psoriasis. Actas Dermosifiliogr. 2014;105:535–45.
6. Krishnan VS, Kõks S. Transcriptional basis of psoriasis from large scale gene expression studies: The importance of moving towards a precision medicine approach. Int J Mol Sci. 2022;23:6130.
7. Zhu D, Yao S, Wu H, Ke X, Zhou X, Geng S, et al. A transcriptome-wide association study identifies novel susceptibility genes for psoriasis. Hum Mol Genet. 2021;31:300–8.
8. Segundo-Val IS, Sanz-Lozano CS. Introduction to the gene expression analysis. Methods Mol Biol. 2016;1434:29–43.
9. Ray-Jones H, Eyre S, Barton A, Warren RB. One SNP at a Time: Moving beyond GWAS in psoriasis. J Invest Dermatol. 2016;136:567–73.
10. Tam V, Patel N, Turcotte M, Bossé Y, Paré G, Meyre D. Benefits and limitations of genome-wide association studies. Nat Rev Genet. 2019;20:467–84.
11. Smith CH, Yiu ZZN, Bale T, Burden AD, Coates LC, Edwards W, et al. British association of dermatologists guidelines for biologic therapy for psoriasis 2020: a rapid update. Br J Dermatol. 2020;183:628–37.
12. Menter A, Strober BE, Kaplan DH, Kivelevitch D, Prater EF, Stoff B, et al. Joint AAD-NPF guidelines of care for the management and treatment of psoriasis with biologics. J Am Acad Dermatol. 2019;80:1029–72.

13. Menter A, Gelfand JM, Connor C, Armstrong AW, Cordoro KM, Davis DMR, et al. Joint American academy of dermatology-national psoriasis foundation guidelines of care for the management of psoriasis with systemic nonbiologic therapies. J Am Acad Dermatol. 2020;82:1445–86.
14. Gallo V, Egger M, McCormack V, Farmer PB, Ioannidis JPA, Kirsch-Volders M, et al. Strengthening the reporting of observational studies in epidemiology-molecular epidemiology STROBE-ME: an extension of the STROBE statement. J Clin Epidemiol. 2011;64:1350–63.
15. Furue K, Ito T, Tsuji G, Nakahara T, Furue M. The CCL20 and CCR6 axis in psoriasis. Scand J Immunol. 2020;91:e12846.
16. Zhang X, Yin M, Zhang LJ. Keratin 6, 16 and 17-Critical Barrier alarmin molecules in skin wounds and Psoriasis. Cells. 2019;8:807.
17. Lee HJ, Hong YJ, Kim M. Angiogenesis in chronic inflammatory skin disorders. Int J Mol Sci. 2021;22:12035.
18. Takahashi H, Iinuma S, Honma M, Iizuka H. Increased serum C-reactive protein level in japanese patients of psoriasis with cardio- and cerebrovascular disease. J Dermatol. 2014;41:981–5.
19. Pellenz FM, Dieter C, Lemos NE, Bauer AC, de Souza BM, Crispim D. Association of TYK2 polymorphisms with autoimmune diseases: A comprehensive and updated systematic review with meta-analysis. Genet Mol Biol. 2021;44:e20200425.
20. Catlett IM, Hu Y, Gao L, Banerjee S, Gordon K, Krueger JG. Molecular and clinical effects of selective tyrosine kinase 2 inhibition with deucravacitinib in psoriasis. J Allergy Clin Immunol. 2022;149:2010–20.e8.
21. Kim J, Oh CH, Jeon J, Baek Y, Ahn J, Kim DJ, et al. Molecular phenotyping small (Asian) versus large (Western) plaque psoriasis shows common activation of IL-17 pathway genes but different regulatory gene sets. J Invest Dermatol. 2016;136:161–72.
22. Li Z, Rotival M, Patin E, Michel F, Pellegrini S. Two common disease-associated TYK2 variants impact exon splicing and TYK2 dosage. PLoS One. 2020;15:e0225289.
23. Oyamada A, Ikebe H, Itsumi M, Saiwai H, Okada S, Shimoda K, et al. Tyrosine kinase 2 plays critical roles in the pathogenic CD4 T cell responses for the development of experimental autoimmune encephalomyelitis. J Immunol. 2009;183:7539–46.
24. Lee SK, Jeon EK, Kim YJ, Seo SH, Kim CD, Lim JS, et al. A global gene expression analysis of the peripheral blood mononuclear cells reveals the gene expression signature in psoriasis. Ann Dermatol. 2009;21:237–42.
25. Golden JB, Groft SG, Squeri MV, Debanne SM, Ward NL, McCormick TS, et al. Chronic psoriatic skin inflammation leads to increased monocyte adhesion and aggregation. J Immunol. 2015;195:2006–18.
26. Reich K, Armstrong AW, Langley RG, Flavin S, Randazzo B, Li S, et al. Guselkumab versus secukinumab for the treatment of moderate-to-severe psoriasis (ECLIPSE): results from a phase 3, randomised controlled trial. Lancet. 2019;394:831–9.
27. Crowley JJ, Langley RG, Gordon KB, Pinter A, Ferris LK, Rubant S, et al. Efficacy of risankizumab versus secukinumab in patients with moderate-to-severe psoriasis: Subgroup analysis from the IMMerge study. Dermatol Ther (Heidelb). 2022;12:561–75.
28. Sollis E, Mosaku A, Abid A, Buniello A, Cerezo M, Gil L, et al. The NHGRI-EBI GWAS catalog: knowledgebase and deposition resource. Nucleic Acids Res. 2023;51:D977–85.
29. Guo P, Luo Y, Mai G, Zhang M, Wang G, Zhao M, et al. Gene expression profile based classification models of psoriasis. Genomics. 2014;103:48–55.
30. Strober B, Thaçi D, Sofen H, Kircik L, Gordon KB, Foley P, et al. Deucravacitinib versus placebo and apremilast in moderate to severe plaque psoriasis: Efficacy and safety results from the 52-week, randomized, double-blinded, phase 3 program for evaluation of TYK2 inhibitor psoriasis second trial. J Am Acad Dermatol. 2023;88:40–51.

SOCIEDADE BRASILEIRA DE DERMATOLOGIA

Anais Brasileiros de Dermatologia

www.anaisdedermatologia.org.br

ORIGINAL ARTICLE

The relationship of FricTest® responses with an urticaria activity score, urticaria control test and quality of life scales in patients with symptomatic dermographism☆

Ömer Faruk Kıraç [a], Mustafa Tosun [a,*], Rukiye Yasak Güner [b], Melih Akyol [b]

[a] *Dermatology Department, Osmaniye Düziçi Hospital, Osmaniye, Turkey*
[b] *Dermatology Department, Sivas Cumhuriyet University Medicine Faculty, Sivas, Turkey*

Received 19 May 2024; accepted 29 July 2024
Available online 7 July 2025

KEYWORDS
Dermographism;
Urticaria;
Quality of Life

Abstract
Background: The FricTest is used as a valuable tool for diagnosing and conducting threshold testing for Symptomatic Dermographism (SD).
Objective: In this study, the authors aimed to make a comparison between the Urticaria Activity Score (UAS), Urticaria Control Test (UCT), Visual Analog Scale (VAS), Dermatology Life Quality Index (DLQI), and Chronic Urticaria-Specific Quality of Life (CU-QoL) used to evaluate disease activity and control in the follow-up of urticaria patients and the Fric Test responses used in the diagnosis of dermographism.
Methods: 71 patients with SD were included in the study. Fric test 4.0 was performed in all patients at baseline and at month 1. The correlations of Fric test scores with UCT, UAS, VAS, DLQI, and CU-QoL at baseline as well as the changes in responses of treatment in the mean scores at month 1 were performed.
Results: In the correlation analyses, positive correlations were observed between UAS, DLQI, and CU-QoL scores and changes in Fric test 4.5 mm and 4 mm responses from baseline to the first month of treatment ($p < 0.05$). No significant correlations were found between Fric test 3.5 mm and 3 mm responses and CU-QoL, UAS, DLQI, and VAS scores ($p > 0.05$).
Study limitations: This study includes results from a small sample size, and larger-scale clinical trials are needed.
Conclusion: Changes in the Fric test 4.5 mm and 4 mm responses of treatment were found to be more sensitive in detecting UCT, UAS, CU-QoL, and DLQI changes than the responses of the Fric test 3.5 mm and 3 mm.

☆ Study conducted at the Sivas Cumhuriyet University Medicine Faculty, Dermatology Department, Sivas, Turkey.
* Corresponding author.
E-mail: doktor699@hotmail.com (M. Tosun).

https://doi.org/10.1016/j.abd.2025.501147

Introduction

Symptomatic dermographism (SD) is characterized by wheals that appear on the skin after pressure or trauma. The term's literal meaning is ''writing on the skin''. Dermographism is observed in approximately 2–5% of the population. The most common form of chronic inducible urticaria (CIndU) is SD (dermographic urticaria, urticaria factitia), characterized by linear wheals with accompanying itching or sometimes burning and stinging sensations upon mild scratching or rubbing of the skin.[1–4] A provocation test using a dermographometer pen, the Fric test, or a blunt, smooth object like the tip of a ballpoint pen or wooden spatula confirms a diagnosis of SD based on the patient's history. The volar forearm or upper back skin is drawn with a blunt object for provocation, and the presence of wheals accompanied by itching, burning, and stinging sensations after ten minutes is positive.[5]

The urticaria activity score (UAS) is used to assess the severity of chronic urticaria based on the number of wheals and intensity of itching over the past week.[6] The urticaria control test (UCT) assesses disease control in chronic urticaria patients over the last four weeks, focusing on symptoms, symptom control, impact on quality of life, and treatment effectiveness.[7] The Chronic Urticaria-Specific Quality of Life (CU-QoL) assesses chronic urticaria's physical, daily, and psychosocial impacts over the past two weeks.[8] The Dermatology Life Quality Index (DLQI) is a widely used, simple, and clear questionnaire that determines the impact of skin diseases and treatments on patients' symptoms, emotions, daily activities, leisure, work, school, and social interactions.[9] Urticaria treatment comprises two main elements: the avoidance of triggering factors and medical treatment. Second-generation H1 antihistamines are the first-choice agents in pharmacological treatment, with omalizumab and cyclosporine forming the second and third stages of the disease control treatment algorithm, respectively.[1,10–12]

This study aims to assess the relationship between Fric test responses, disease activity scores (UAS, UCT, and visual analog scale (VAS), and quality of life scales (CU-QoL and DLQI) in patients with SD. The authors investigated the potential of the Fric Test as a tool to assess disease severity and predict its impact on quality of life.

Methods

The local Ethics Committee approved the present study (approval number: 2022-09/03, date: 20.09.2022). This study included 71 patients with SD who were followed up at the Hospital UCARE (Urticaria Centers of Reference and Excellence) between October 2022 and March 2023. The patients were using second-generation H1 antihistamines and omalizumab.

The authors obtained an informed consent form from all participants and informed them about the study. The authors excluded patients under the age of eighteen, those under immunosuppressive treatment, and those on systemic steroids. The authors recorded the demographic information of all participants.

The authors used UAS, UCT, and VAS to assess disease severity and control. In this study, the authors also used DLQI and CU-QoL to assess the impairment of quality of life (QoL).

Design and evaluation of the study based on Fric test responses, urticaria activity score, urticaria control test, and quality of life tools

FricTest® 4.0 (Moxie, Germany) was applied perpendicular to the skin of the back with a pressure such that all pins (4.5 mm, 4 mm, 3.5 mm, and 3 mm) made complete contact (Fig. 1). The authors applied the Fric test to the back region of the patients in this study, both at baseline and during the first month of treatment. The authors measured the widths of the wheals formed at the 10th minute using a digital caliper within the four corners of the Fric test (4.5 mm, 4 mm, 3.5 mm, and 3 mm) and recorded them in centimeters. The authors calculated daily urticaria activity scores (UAS) at baseline and during the first month of treatment, summing the seven-day scores, to assess the severity of urticarial activity. The authors also applied the urticaria control test (UCT) at both baseline and the first month of treatment to assess the severity of the disease and the response to treatment.

Patients were asked to evaluate itching and burning complaints on a 10-point scale 10 minutes after the application of the Fric test in the first and 1-month examinations and recorded as VAS scores (10 points indicate the most severe itching and burning sensation, 0 points indicate no itching and burning sensation). The authors also administered the DLQI and the CU-QoL questionnaires at baseline and the first month of treatment to assess the impact of urticarial disease on daily activities, home, work, school life, social relationships, sleep, nutrition, personal care, and psychosocial status.

The authors analyzed correlations between the millimeter changes in Fric test responses from baseline to the first month and the changes in UAS, UCT, CU-QoL, DLQI, and VAS scores for the same period.

Statistical analysis

The authors entered the collected data from this study into the SPSS software package (Version 22.0) for evaluation. The authors assessed the normality of the continuous data distribution using the Kolmogorov-Smirnov test. The authors provided mean, SD, median (min–max), frequency, and percentages for quantitative variables as descriptive statistics. The authors used the Chi-Square test to compare categorical ratios. The authors used the Mann-Whitney *U* test to compare two independent groups and the Wilcoxon test to compare two dependent groups. The Spearman correlation test was applied. The authors set the level of significance (p-value) at 0.05.

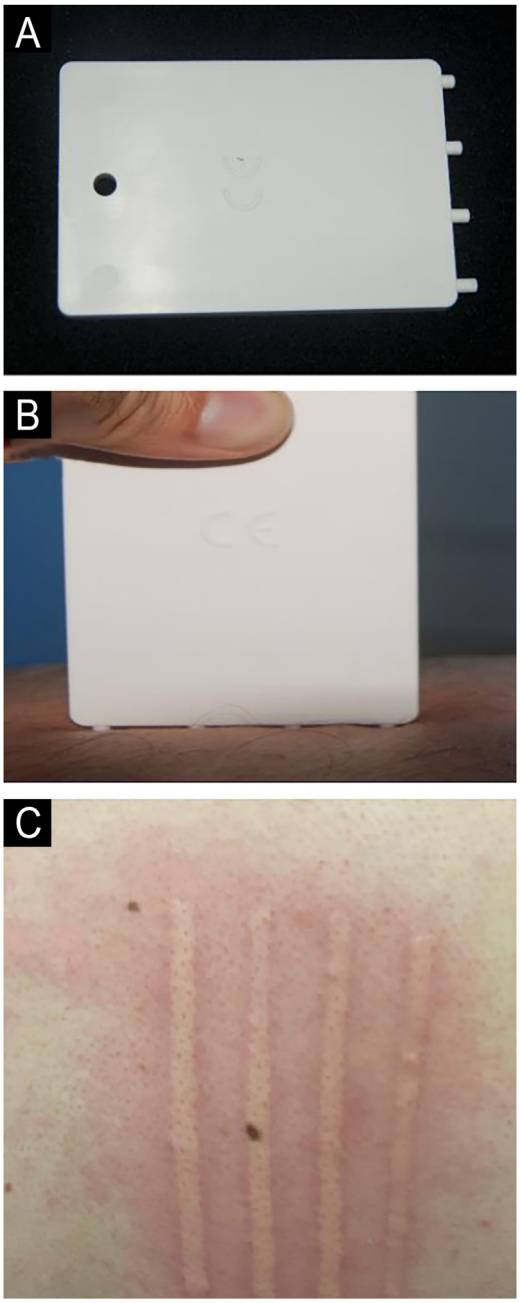

Fig. 1 Fric test to determine dermographism. (A) Fric test 4.0. (B) Fric test applied perpendicular to the skin. (C) Wheals at the 10th minute as a result of the Fric test.

Table 1 Demographic data of patients with symptomatic dermographism (n = 71).

Age, years	
Min–max (Median)	18–75 (41)
Mean ± SD	41.5 ± 15.0
BMI, kg/m^2	
Min–max (Median)	14.2–57.8 (26.4)
Mean ± SD	27.4 ± 6.6
Time of urticaria diagnosis (year)	
Min–max (Median)	0.15–21.0 (4)
Mean ± SD	5.8 ± 5.6
Gender	
Male	18 (25.4%)
Female	53 (74.6%)
Working status	
Not working	42 (59.16%)
Working	29 (40.84%)
Marital status	
Married	52 (73.24%)
Single	19 (26.76%)
Education level	
Primary Education	32 (45.07%)
Secondary Education	18 (25.35%)
Higher Education	21 (29.57%)
Smoking status	
No	54 (76.05%)
Yes	17 (23.9%)
Drinking status	
No	64 (90.14%)
Yes	7 (9.85%)

SD, Standard Deviation; BMI, Body Mass Index.

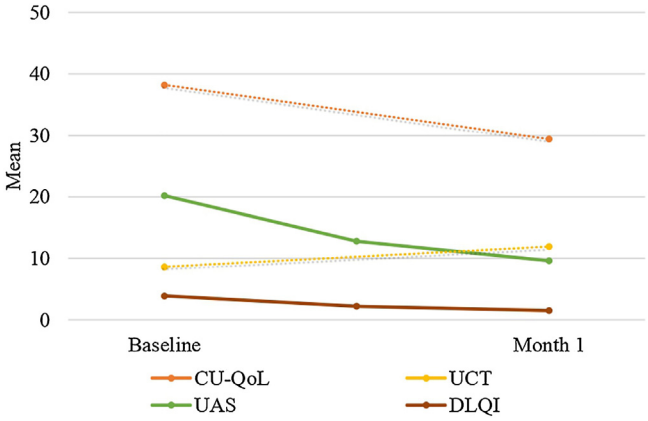

Fig. 2 Changes in CU-QoL, UCT, UAS and DLQI during the treatment process.

Results

The demographic data of patients with SD is in Table 1.

There was a statistically significant decrease in Fric test responses (4.5 mm, 4 mm, 3.5 mm, and 3 mm) from baseline to the first month of treatment ($p < 0.05$). Additionally, there was a statistically significant decrease in UAS, CU-QoL, DLQI, and VAS scores from baseline to the first month of treatment ($p < 0.05$). Furthermore, there was a statistically significant increase in UCT scores from baseline to the first month of treatment ($p < 0.05$) (Table 2, Figs. 2 and 3).

The Fric test 4.5 mm response was found to have a positive correlation with CU-QoL ($r = 0.352$, $p = 0.003$), UAS ($r = 0.402$, $p = 0.001$), and DLQI ($r = 0.369$, $p = 0.002$) from baseline to the first month of treatment. The Fric test 4.5 mm response was found to have a negative correlation with the UCT score ($r = -0.398$, $p = 0.001$). No statistically significant correlation was found between the Fric test 4.5 mm response and the VAS score ($r = 0.180$, $p = 0.142$). The Fric test 4 mm response was found to have a positive correlation with CU-QoL ($r = 0.312$, $p = 0.009$), UAS ($r = 0.341$,

Table 2 Comparisons of measurement parameters from baseline to the first month of treatment.

	Min–max (Median) Mean ± SD	p^a
Baseline of CU-QoL	25–74 (38) 38.2 ± 10.4	<0.001
Month 1 of CU-QoL	12–42 (27) 29.4 ± 7.1	
Baseline of UCT	0–16 (8) 8.6 ± 4.0	<0.001
Month 1 of UCT	4–16 (12) 11.9 ± 2.7	
Baseline of UAS	3–39 (21) 20.2 ± 8.8	<0.001
Month 1 of UAS	0–28 (9) 9.6 ± 6.8	
Baseline of DLQI	0–21 (3) 3.9 ± 3.4	<0.001
Month 1 of DLQI	0–9 (1) 1.5 ± 1.2	
Baseline of Fric test 4.5 mm	1.6–6.3 (3.2) 3.4 ± 1.0	<0.001
Month 1 of Fric test 4.5 mm	0–4.6 (2.2) 2.2 ± 0.9	
Baseline of Fric test 4 mm	1.2–5.6 (2.9) 3.0 ± 1.0	<0.001
Month 1 of Fric test 4 mm	0–4.2 (2) 1.7 ± 1.1	
Baseline of Fric test 3.5 mm	0–4.7 (2.4) 2.3 ± 1.3	<0.001
Month 1 of Fric test 3.5 mm	0–4 (1.5) 1.2 ± 1.2	
Baseline of Fric test 3 mm	0–4.2 (1.5) 1.4 ± 1.5	<0.001
Month 1 of Fric test 3 mm	0–3.7 (0) 0.6 ± 1.1	
Baseline of VAS mm	0–10 (4) 3.8 ± 2.8	<0.001
Month 1 of VAS	0–10 (1) 2.1 ± 2.5	

CU-QoL, Chronic Urticaria Quality of Life Questionnaire; UAS, Urticaria Activity Score; UCT, Urticaria Control Test; DLQI, Dermatology Life Quality Index; VAS, Visual Analog Scale.
[a] The level of significance (p-value) was accepted as 0.05.

p = 0.004), and DLQI (r = 0.424, p < 0.001) from baseline to the first month of treatment. The Fric test 4 mm response was found to have a negative correlation with the UCT score (r = -0.397, p = 0.001). No statistically significant correlation was found between the Fric test 4 mm response and VAS score (r = 0.187, p = 0.130) (Table 3).

There was no statistically significant correlation between Fric test 3.5 mm response with CU-QoL (r = 0.097, p = 0.422), UAS (r = 0.196, p = 0.102), DLQI (r = 0.255, p = 0.052), UCT score (r = -0.194, p = 0.105), and VAS score (r = 0.010, p = 0.936) from baseline to the first month of treatment. Additionally, there was no statistically significant correlation between the Fric test 3 mm response and CU-QoL (r = 0.233, p = 0.052), UAS (r = 0.228, p = 0.058), DLQI (r = 0.152, p = 0.210), or VAS score (r = 0.083, p = 0.504) from baseline to the first month of treatment. There was only a statistically significant negative correlation between the Fric test 3 mm response and the UCT score (r = -0.344, p = 0.004) (Table 3).

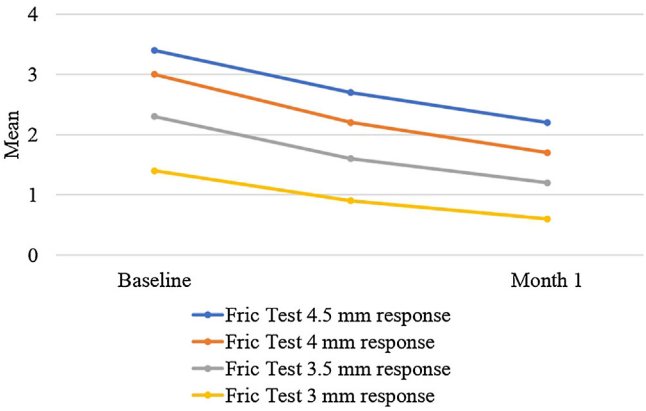

Fig. 3 The change in responses of Fric test mm during the treatment process.

Table 3 Correlation analysis of changes in Fric test responses from baseline to the first month of treatment with different measurements.

Baseline to month 1 differences	R	p^a
Fric test 4.5 mm response baseline to month 1		
CU-QoL	**0.352**	**0.003**
UCT	**-0.398**	**0.001**
UAS	**0.402**	**0.001**
DLQI	**0.369**	**0.002**
VAS	0.180	0.142
Fric test 4 mm response baseline to month 1		
CU-QoL	**0.312**	**0.009**
UCT	**.397**	**0.001**
UAS	**0.341**	**0.004**
DLQI	**0.424**	**<0.001**
VAS	0.187	0.130

CU-QoL, Chronic Urticaria Quality of Life Questionnaire; UCT, Urticaria Control Test; UAS, Urticaria Activity Score; DLQI, Dermatology Life Quality Index; VAS, Visual Analog Scale.
[a] The level of significance (p-value) was accepted as 0.05.

Discussion

SD is the most common subtype of chronic inducible urticaria, significantly limiting patients' daily functionality, work and school performance, and quality of life due to its psychosocial effects. For the diagnosis of SD, provocation tools such as a dermographometer pen, the Fric test, or a blunt-tipped, smooth object can be used. Schoepke et al. found the Fric test 4.0 to be 100% sensitive and 100% specific in diagnosing SD.[13] The authors used the Fric test® 4.0 (Moxie, Germany) in the present study and recorded the corresponding values for 4 different tips (4.5 mm, 4 mm, 3.5 mm, and 3 mm) in millimeters. The authors investigated the correlation of these values with disease activity scores and quality of life scales.

In this study, the authors observed a significant positive correlation between the change in Fric test 4.5 mm response from baseline to the first month of treatment and changes in CU-QoL, UAS, and DLQI, and a significant negative correlation with the change in UCT. Similarly, the change in Fric test 4 mm response from baseline to the first month of treatment also showed a significant positive correlation with changes in CU-QoL, UAS, and DLQI, as well as a significant negative correlation with UCT change. However, the authors detected no significant relationship between the change in Fric test 4.5 mm and 4 mm responses from baseline to the first month of treatment and the VAS score.

No significant correlation was found between the 3.5 mm and 3 mm Fric test responses and changes in CU-QoL, UAS, VAS, and DLQI. Also, no significant relationship was identified between the change in the 3.5 mm Fric test response from baseline to the first month of treatment and the change in UCT score. However, a significant negative correlation was found between the change in the Fric test 3 mm response from baseline to the first month of treatment and the change in UCT score. Considering that an increase in UCT scores indicates improved urticaria control, the negative correlation between UCT score changes and Fric test responses is consistent with other findings in the present study.

Based on these results, it can be inferred that test results corresponding to 4.5 mm and 4 mm responses may provide more accurate information in predicting changes in CU-QoL, UCT, UAS, and DLQI, as well as in assessing disease activity and its impact on quality of life, compared to the responses for 3.5 mm and 3 mm ends.

Can et al. used the total Fric test score (TFS) in their study, which involved 58 patients and included initial visits and one-month follow-ups. In their study, changes in TFS showed a moderate positive correlation with changes in DLQI, and a significant negative correlation was found between changes in TFS and the physician's global assessment of disease control. However, in the same study, while the average changes in TFS showed a negative but non-significant correlation with changes in UCT, no correlation was found between changes in itching scores, the patient's global assessment of disease severity, and changes in TFS. The authors measured the reaction sizes for the four different ends of the Fric test in millimeters in this study, without using TFS; instead, the authors used the differences in millimeter measurements for correlation analysis. In the present study, the correlation of changes in the 4.5 mm and 4 mm ends of the Fric test from baseline to the first month of treatment with DLQI supports each other. Furthermore, the positive correlation of these changes with CU-QoL, UAS, and DLQI and the significant negative correlation with UCT indicate that the Total Fric Score's sensitivity to reflecting disease severity might be low. This suggests the need for recording measurements in millimeters or developing a new scoring method.[14]

In Ferreira et al.'s study comparing the quality of life of patients with chronic urticaria (CU) with its psychometric properties, CU-QoL was found to be highly correlated with DLQI, successfully differentiating between different severities of redness and itching.[15] Although this study did not directly examine the relationship between these two measurement tools, it was observed that they correlate similarly with changes in Fric test responses. Particularly, the change in Fric test 4.5 mm and Fric test 4 mm responses from baseline to the first month of follow-up were found to be correlated with changes in DLQI and CU-QoL. This result supports the conclusion that the Fric 4.5 mm and 4 mm ends are more sensitive in patient follow-up.

Can and Kocatürk's study included patients with SD. The study validated treatment responses with increased UCT scores, physicians' global assessments of disease control, decreased DLQI scores, and patients's global assessments of disease severity. Omalizumab treatment was administered to 18 patients in the study, and by the 24th week, the total response rates of patients had increased to 86%. Over time, UCT scores significantly increased, and VAS scores decreased.[16]

Limitations

A limitation of this study is that it includes results from a small sample size, and larger-scale clinical trials are needed. Future studies assessing Fric test results more comprehensively could help us better understand patients' treatment responses and personalize treatment plans.

Conclusion

In conclusion, the present study identified significant relationships between changes in Fric test results and changes in CU-QoL, UCT Score, UAS, and DLQI. In particular, test results corresponding to the 4.5 mm and 4 mm ends of the Fric test were found to be more sensitive in detecting changes in CU-QoL, UCT, UAS, and DLQI compared to responses from the 3.5 mm and 3 mm ends. There is a correlation between the Fric test results, particularly the 4.5 mm and 4 mm ends, and other clinical assessment measurements. This suggests that the Fric test could be a useful tool for assessing disease severity and predicting its impact on quality of life.

Editor

Luciana P. Fernandes Abbade.

Research data availability

The entire dataset supporting the results of this study was published in this article.

Financial support

None declared.

Authors' contributions

Ömer Faruk Kıraç: Writing, methodology, data curation, software, contributed to the clinical follow-up and management of patients.

Mustafa Tosun: Formal analysis, writing, approval of final manuscript, validation, visualization.

Rukiye Yasak Güner: Writing, methodology.

Melih Akyol: Formal analysis, and approval of the final manuscript.

Conflicts of interest

None declared.

References

1. Zuberbier T, Abdul Latiff AH, Abuzakouk M, Aquilina S, Asero R, Baker D, et al. The international EAACI/GA^{2}LEN/EuroGuiDerm/APAAACI guideline for the definition, classification, diagnosis, and management of urticaria. Allergy. 2022;77:734–66.
2. Schoepke N, Młynek A, Weller K, Church MK, Maurer M. Symptomatic dermographism: an inadequately described disease. J Eur Acad Dermatol Venereol. 2015;29:708–12.
3. Beck LA, Bernstein JA, Maurer M. A review of ınternational recommendations for the diagnosis and management of chronic urticaria. Acta Derm Venereol. 2017;97:149–58.
4. Weller K, Siebenhaar F, Hawro T, Altrichter S, Schoepke N, Maurer M. Clinical measures of chronic urticaria. Immunol Allergy Clin North Am. 2017;37:35–49.
5. Magerl M, Altrichter S, Borzova E, Giménez-Arnau A, Grattan CEH, Lawlor F, et al. The definition, diagnostic testing, and management of chronic inducible urticarias—the EAACI/GA(2)LEN/EDF/UNEV consensus recommendations 2016 update and revision. Allergy. 2016;71:780–802.
6. Zuberbier T, Aberer W, Asero R, Bindslev-Jensen C, Brzoza Z, Canonica GW, et al. The EAACI/GA(2)EN/EDF/WAO guideline for the definition, classification, diagnosis, and management of urticaria: the 2013 revision and update. Allergy. 2014;69:868–87.
7. Weller K, Groffik A, Church MK, Hawro T, Krause K, Metz M, et al. Development and validation of the urticaria Control test: a patient-reported outcome instrument for assessing urticaria control. J Allergy Clin Immunol. 2014;133:1365–72.
8. Kocatürk E, Weller K, Martus P, Aktas S, Kavala M, Sarigul S, et al. Turkish version of the chronic urticaria quality of life questionnaire: cultural adaptation, assessment of reliability and validity. Acta Derm Venereol. 2012;92:419–25.
9. Öztürkcan S, Ermertcan AT, Eser E, Şahin MT. Cross validation of the Turkish version of dermatology life quality index. Int J Dermatol. 2006;45:1300–7.
10. Kocatürk Göncü E, Aktan Ş, Atakan N, Bülbül Başkan E, Erdem T, Koca R, et al. The Turkish guideline for the diagnosis and management of urticaria-2016. Turkderm. 2016;50:82–98.
11. Maurer M, Church MK, Gonçalo M, Sussman G, Sánchez-Borges M. Management and treatment of chronic urticaria (CU). J Eur Acad Dermatol Venereol. 2015;29:16–32.
12. Dressler C, Werner RN, Eisert L, Zuberbier T, Nast A, Maurer M. Chronic inducible urticaria: a systematic review of treatment options. J Allergy Clin Immunol. 2018;141:1726–34.
13. Schoepke N, Abajian M, Church MK, Magerl M. Validation of a simplified provocation instrument for diagnosis and threshold testing of symptomatic dermographism. Clin Exp Dermatol. 2015;40:399–403.
14. Can PK, Etikan P, Kızıltaç U, Kızıltaç K, Singer R, Kocaturk E. Fric test revisited: a suggestion for a new scoring system and ıts correlation with urticaria control test and dermatology life quality ındex. Int Arch Allergy Immunol. 2019;178:76.
15. Ferreira PL, Gonçalo M, Ferreira JA, Costa AC, Todo-Bom A, Abreu CL, et al. Psychometric properties of the portuguese version of the chronic urticaria quality of life questionnaire (CU-Q2oL). Health Qual Life Outcomes. 2019;17:190.
16. Can PK, Kocatürk E. Evaluation of the treatment responses with the recommended tools in patients with symptomatic dermographism. Turkderm-Turk Arch Dermatol Venereol. 2019;53:135–9.

SOCIEDADE BRASILEIRA DE DERMATOLOGIA

Anais Brasileiros de Dermatologia

www.anaisdedermatologia.org.br

ORIGINAL ARTICLE

Xeroderma pigmentosum: a 12-year experience in digital dermoscopy and reflectance confocal microscopy follow-up at a Cancer Center in Brazil☆

Joyce Gouvêa Freire, Tatiana Cristina Moraes Pinto Blumetti, Rafaela Brito de Paula, Juliana Casagrande Tavoloni Braga *

AC Camargo Cancer Center, São Paulo, SP, Brazil

Received 30 October 2024; accepted 1 January 2025
Available online 13 August 2025

KEYWORDS
Xeroderma pigmentosum;
Dermoscopy;
Reflectance confocal microscopy;
Malignant melanoma

Abstract

Background: Xeroderma pigmentosum (XP) is an autosomal recessive genetic disorder characterized by a defect in the nucleotide excision repair (NER) pathway, responsible for repairing DNA damage induced by ultraviolet rays. The most common symptom in affected patients is an increased photosensitivity associated with early development of cutaneous and internal malignancies.

Objective: To describe whether the follow-up of xeroderma pigmentosum patients using total body mapping (TBM) with digital dermoscopy (DD) and *in vivo* reflectance confocal microscopy (RCM) increases early detection of melanoma and reduces unnecessary biopsies of benign melanocytic lesions.

Methods: Twelve XP patients were followed-up with TBM and DD from February 2008 until March 2020. The number of melanocytic lesions excised (NNE) was counted before and after the surveillance with TBM, DD, and RCM.

Results: In the 12-year surveillance period, twelve XP patients were followed-up with TBM, DD, and RCM. The proportion of thinner and *in situ* melanomas diagnosed increased after the implementation of TBM and DD in the follow-up of this group (from 67% to 82%). The association of technologies caused a reduction in the NNE from 4.02 to 2.88 and promoted early detection of melanoma.

Study limitations: Maintaining regular follow-up with some XP patients can be challenging due to comorbidities and social issues. Although XP is a rare disease, this represents an especially small number of cases.

☆ Study conducted at the AC Camargo Cancer, São Paulo, SP, Brazil.

* Corresponding author.
E-mails: jcasagrande.dermato@gmail.com, juliana.braga@accamargo.org.br (J.C. Braga).

https://doi.org/10.1016/j.abd.2025.501182

Conclusion: XP patients are generally submitted to multiple surgical excisions, with high morbidity. Based on this experience, TBM, DD and RCM have improved the early detection of melanoma and reduced the NNE with a positive impact on health and quality of life.

Introduction

Xeroderma pigmentosum (XP) is an autosomal recessive genetic disorder characterized by a defect in the nucleotide excision repair (NER) pathway. The NER pathway is responsible for repairing DNA damage induced by ultraviolet, thus the most common symptom in affected patients is an increased photosensitivity associated with early development of cutaneous and internal malignancies.[1]

The disease is comprised of eight complementation groups (A to G) with defects in different steps of the NER pathway, and an XP variant V (XP-V), which has normal repair of photoproducts but defective DNA polymerase *n* (pol *n*).[1] Multiple skin cancers are more common in XP-C, XP-E, and XP-V groups.[2] The incidence of XP varies among different countries in the world: in Japan, the incidence is 1 in 20,000 to 40,000 live births, while in the United States and Europe is 1 in 250,000 to 1,000,000 live births.[3]

The clinical manifestations of XP are predominantly cutaneous and ocular, but neurologic findings are reported in a few cases.[1] The photosensitivity is the first skin manifestation and occurs in 50% of the patients. It is characterized by exaggerated sunburn (with blisters and prolonged erythema) with minimal UV exposure.[4] Freckling is usually seen within the first two years of age.[1] Hyperpigmented and hypopigmented macules, telangiectasias and premature photoaging are also seen in childhood.

Early diagnosis and sun protection measures are crucial for the survival of XP patients. Individuals who are less than 20 years old have a 10,000-fold increased risk of developing non-melanoma skin cancers and a 2,000-fold increased risk of melanoma (MM) when compared to the general population. The median age of the onset of non-melanoma skin cancer is at 9 years and for the first melanoma is 22 years.[1]

It has been reported that dermoscopy significantly increases the sensitivity and specificity of the diagnosis of melanoma compared with naked-eye examination.[5] However, in XP patients with a high number of actinic lesions (solar lentigos, lentigines and solar elastosis), the early recognition of malignancies can be challenging.[6]

With the goal to improve follow-up for patients with XP, few reports showed that digital dermoscopy could be useful. Salerni et al suggested that the use of baseline and follow-up photographs of the skin (total-body photography) combined with digital dermoscopy increases the diagnostic accuracy of malignant melanoma in high-risk patients, including those with genodermatoses like XP. In that cohort, more than 600 patients were evaluated, although only 3 were XP.[7] In 2005, Malvehy et al. described the dermoscopy of skin lesions in two XP patients, and in 2009 Green et al. reported the follow-up of a 39 y.o. woman with XP using total-body examination and photography and, dermoscopy.[6,8]

In vivo reflectance confocal microscopy (RCM), a noninvasive imaging technique with cellular resolution, enables the early detection of melanoma with a lower rate of excisions.[9] It has already been proved that RCM improves the diagnostic accuracy in skin cancer detection when combined with dermoscopy, especially for difficult-to-diagnose lesions.[9–12] In 2019, Rocha et al first published the use of RCM on dermoscopic suspicious lesions, improving the diagnostic accuracy of malignancy in XP patients.[13]

Here the authors describe the experience in the follow-up of twelve XP patients at the Department of Cutaneous Oncology of the AC Camargo Cancer Center, São Paulo, SP, Brazil based on total-body photography associated with digital dermoscopy and the use of RCM as a complementary exam to avoid unnecessary excisions.

Objective

To describe whether the follow-up of xeroderma pigmentosum patients using total body mapping (TBM) with digital dermoscopy (DD) and in vivo reflectance confocal microscopy (RCM) increases early detection of melanoma and reduces unnecessary biopsies of benign melanocytic lesions.

Methods

Twelve XP patients were retrospectively retrieved from the Department of Cutaneous Oncology of the AC Camargo Cancer Center, São Paulo, SP, Brazil. They had been followed up with total-body photography and digital dermoscopy from February 2008 until March 2020. The study was approved by the AC Camargo Cancer Center Ethics Committee (CEP 1524/11). These patients were also referred to a multidisciplinary team of oncology surgeons, oncogenetic evaluation and ophthalmologic evaluation if necessary (Fig. 1).

The follow-up was performed every 6 months during regular dermatology clinics. The dermatological visits comprised complete dermatological examination using a manual dermatoscope (DermLite® DermLite LCC, California) as well as Total-Body photography and digital dermoscopy using Fotofinder® (Fotofinder Systems GmbH, Germany).

In a first step, previous and current total-body images were compared, and changes in color, shape, and size of pigmented lesions were evaluated, and the search for new lesions was performed. The second step consisted of the evaluation of digital dermoscopy images; the melanocytic lesions previously recorded were compared to the current images, and new observed lesions were included. Pre-existing lesions or new lesions that showed asymmetry, multiple colors and at least one of the dermoscopy

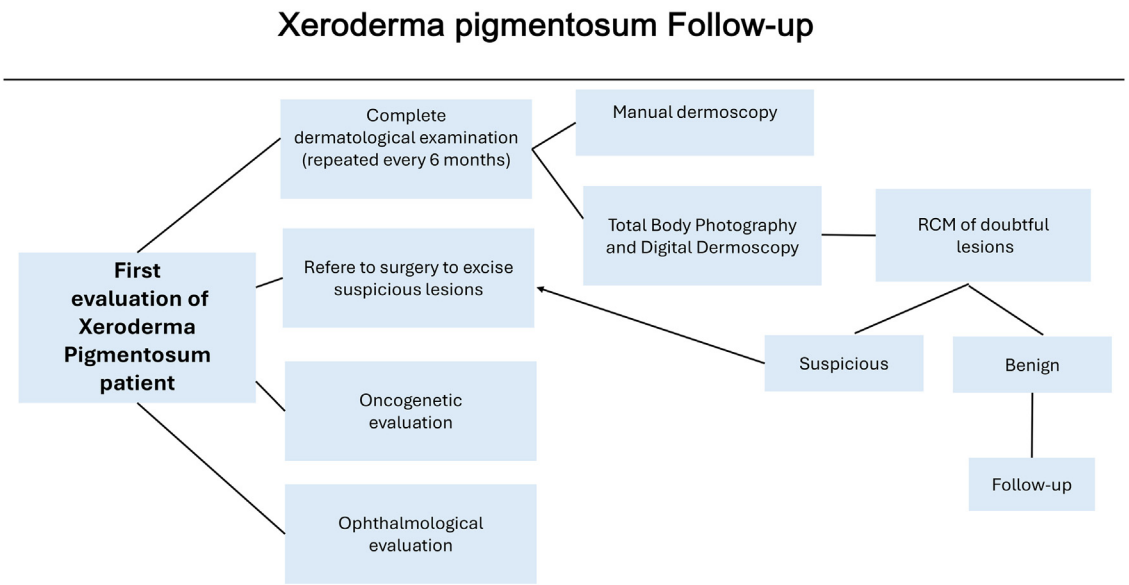

Figure 1 Fluxogram of the xeroderma pigmentosum patients.

suspicious features associated with MM by dermoscopic pattern analysis were included.[14] In lesions under surveillance, increasing in size, changes in color and appearance of the following dermoscopy features were considered suspicious: peppering or multiple brown or dark globules with irregular shape or distribution, prominent pigment network, blotches, and structureless areas. The melanocytic lesions included in the digital dermoscopy records that presented atypical dermoscopic features but no changes from the previous images were entitled to follow-up. New lesions with atypical features and the ones with subtle changes were considered suspicious and referred to RCM, while melanocytic lesions with specific dermoscopic features of melanoma were excised (as described in Pattern Analysis).[14] All the steps were performed by certified dermatologists, without the use of the Fotofinder® artificial intelligence-based system.

RCM examination was performed by an experienced dermatologist using the Vivascope 1500® confocal microscope (Lucid-Tech, Rochester, New York, USA). The RCM evaluation was based on features previously described for melanocytic lesions in the general population following the Brazilian Portuguese consensus terminology and translated to English for publication purposes.[9,10] The RCM confocal criteria indicative of melanoma suspicion included the presence of disarranged epidermal pattern and pagetoid cells in the epidermis, non-edged papillae, cellular atypia at the dermoepidermal junction, atypical nests, and bright nucleated cells in the upper dermis.[9,10]

The number needed to excise (NNE) was calculated by dividing the total number of excised melanocytic lesions by the total number of melanomas, regardless of whether they underwent RCM evaluation or not.

Results

During the 12years of surveillance, total-body photography and digital dermoscopy were performed with a median of 6 exams per patient (range: 2–13). Three of the 12 patients have done only two total-body photographs and digital dermoscopies during the follow-up.

Five patients had their molecular mutation identified: three females in DNA repair gen XP-C (C.2251-1G>C), one female in XP-C (C.2251-1G>C and nonsense mutation c.1969G>T) and one male in XP-V (C.1221-1224del; T408LfsX36) (Table 1).

Among the 12 XP patients, 6 (50%) were female and 2 were from the same family (sister and brother). The mean age at the first exam with total-body photography and digital dermoscopy was 27 y.o. (range: 7–54 y.o.). The youngest and the oldest patients who underwent digital dermoscopy were 7 and 54 y.o., respectively.

In the present data, all patients developed skin cancer before 11 y.o.; the youngest one developed a basal cell carcinoma (BCC) at 4 years of age while her first melanoma was diagnosed at 15 y.o.. The youngest patient with melanoma diagnosed during the follow-up was a 7 y.o. male.

Eleven patients had a previous history of surgical removal of squamous cell carcinoma (SCC) (n = 33) and/or basal cell carcinomas (n = 254) and eight patients of melanoma (n = 88) before the first total-body photography and digital dermoscopy. Fifty-eight (67%) of all excised malignant melanomas were *in situ*, 24 (28%) were classified as thin melanoma (Breslow $\leq$ 1 mm) and 4 (5%) were thick melanoma (Breslow > 1 mm). The most frequent histopathological subtype found was superficial spreading melanoma and the highest Breslow thickness was 1.55 mm. The melanomas were predominantly localized on the trunk (n = 33), followed by upper limbs (n = 24), lower limbs (n = 22) and head and neck (n = 8) (Table 1).

During the follow-up, based on total-body photography and digital dermoscopy 187 BCC, 51 SCC and 68 MM were excised. Among the excised melanomas, 56 (82%) were *in situ*, 9 (13%) with Breslow <1 mm, one with Breslow 1.8 mm, one with Breslow 8 mm (desmoplastic subtype), and the other was a primary dermal melanoma. No melanoma metas-

Table 1 Melanoma diagnosis and mutation profile.

Patient	Age at first DD	MM *in situ*		MM < 1 mm		MM > 1 mm		Total of melanoma	Mutation
		Before DD	After DD	Before DD	After DD	Before DD	After DD		
1	26	0	2	0	0	0	0	2	XP-C (C.2251-1G>C)
2	18	1	23	2	4	1	0	31	XP-C (C.2251-1G>C and nonsense mutation c.1969G>T
3	54	2	1	3	1	0	1	8	XP-V (C.1221-1224del; T408LfsX36
4	41	4	9	0	0	0	0	13	NT
5	13	0	4	0	1	0	0	5	XP-C (C.2251-1G>C)
6	7	0	0	0	0	0	0	0	NT
7	41	8	7	0	2	1	1	19	NT
8	8	2	3	0	0	0	1	6	NT
9	27	2	0	1	0	1	0	4	NT
10	9	0	0	0	0	0	0	0	NT
11	37	6	2	4	0	0	0	12	XP-C (C.2251-1G>C)
12	39	33	5	14	1	1	0	54	NT
Total		**58**	**56**	**24**	**9**	**4**	**3**	**154**	

DD, Digital Dermoscopy; MM, Melanoma; NT, Not Tested.

tases were seen. Before the follow-up period 67% (n = 58) of all melanomas excised were *in situ* and after, the value increased to 82% (n = 56).

The dermoscopy features found on invasive melanomas were: atypical, pigmented network (90%), blotches (40%), irregular globules (30%), blue-whitish veil (30%), dotted vessels (30%), polymorphic vessels (20%), structureless areas (10%), shiny-white streaks (10 %) and milky-red areas (10%) (Table 1; Figs. 2–6).

During the XP patient surveillance, lesions with small changes in dermoscopy and the new ones showing atypical patterns without melanoma features were evaluated under RCM. The features described for melanoma in the general population were applied. Disarranged pattern and the presence of dendritic nucleated cells at the spinous-granular layer, areas with non-edged papillae and dermis with atypical meshwork were the most common features in malignant lesions in the patients (Fig. 7). A total of 48 lesions were evaluated under RCM. Of these, 23 were excised, while the remaining lesions were kept under surveillance. Among the excised lesions, 16 (69%) were malignant, including 14 melanomas, 1 BCC and 1 SCC. Histological analysis of the 7 benign lesions revealed 5 cases of atypical intradermal melanocytic hyperplasia and 2 dysplastic junctional nevi.

Over the 12-year follow-up period, a total of 503 lesions were excised, 197 of which were benign. Among these benign lesions, 128 were melanocytic, while 69 were non-melanocytic, including seborrheic keratosis and actinic keratosis. In the current study, the NNE found was 2,88. However, when the patients were evaluated using RCM, a significant improvement was observed, reducing the NNE to 1.64.

Discussion

Xeroderma pigmentosum is a rare genetic inherited disorder caused by a defect in UV-induced DNA repair (nucleotide excision repair or translesion synthesis).[15] Mutations in eight different genes have already been identified in XP patients, from which seven (XPA-XPG) are associated with a defect in nucleotide excision repair and one (XP-V) which codes a defective DNA polimerase *n*.[16,17] Therefore, photoprotection is the only imperative measure to avoid the development of sunburn and skin cancers.

XP-C, XP-E and XP-V groups are characterized by normal sunburn reactions. In XP-C patients, the first symptoms are photo-distributed lentigines around the age of 2 y.o. Due to the absence of exacerbated sunburns, they generally have a later age diagnosis and thus accumulate more photodamage, leading to an earlier age of first skin cancer.[18,25] Among the four XP-C patients in the present study, the earliest skin cancer diagnosed was at the age of 4 y.o.

XP-V patients tend to be diagnosed much later, with patients living two decades or more without symptoms. Consequently, they accumulate more UVR-induced mutations and can develop hundreds of skin tumors later in life.[2] The XP-V patient in the data developed his first carcinoma and melanoma at the ages of 24 y.o. and 43 y.o, respectively. This is the oldest patient, aged 60 and who has already had removed five melanomas and ninety-three carcinomas.

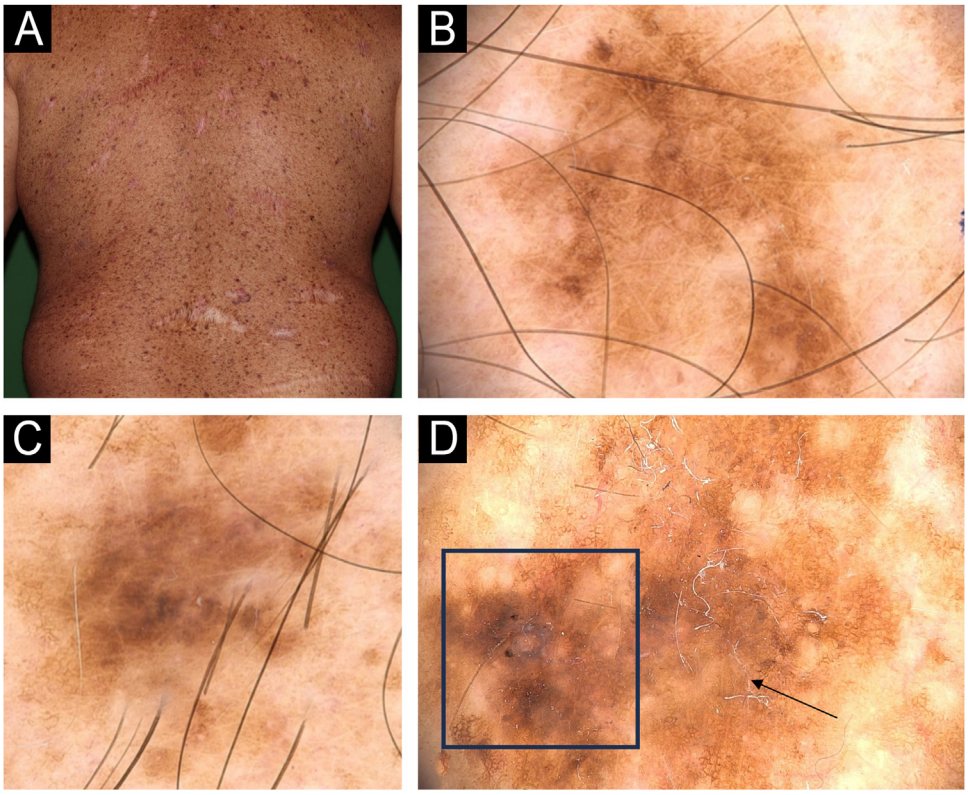

Figure 2 Dermoscopy patterns of benign and malignant melanocytic lesions observed in a XP patient. (A) Clinical aspect of a skin torso showing multiple freckles and pigmented lesions. (B and C) Dermoscopy of pigmented lesions with lentiginous reticular homogeneous pattern. (D) Dermoscopy of a melanoma *in situ* showing atypical, pigmented network, structureless area (arrow), hyperpigmented excentric area (blotch) with granularity (square).

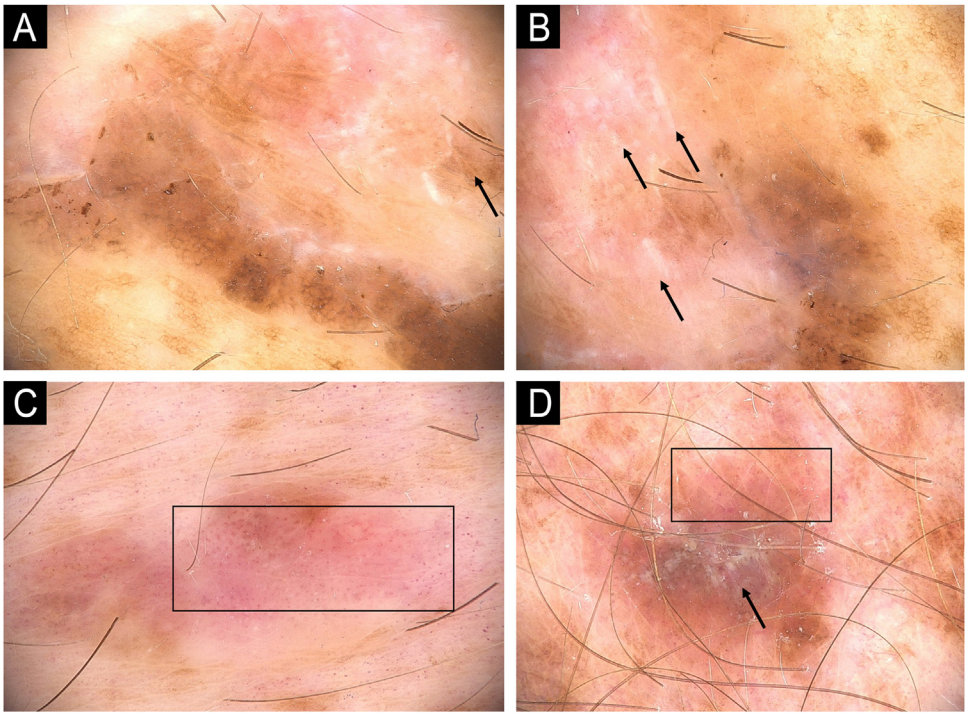

Figure 3 Melanoma in a XP patient. (A and B) Melanoma *in situ*: Dermoscopy showing hyperpigmented structureless areas at the periphery of the lesions and shiny-white streaks in the center (arrows). (C) Melanoma *in situ*: Hypopigmented structureless lesion showing atypical and dotted vessels in a milky red area (rectangle). (D) Superficial spreading melanoma, Breslow 0.4 mm showing shiny-white structures (arrow) and dotted vessels (rectangle).

Figure 4 Melanoma *in situ* in a XP patient: Dermoscopy showing atypical network (square) and blue-white veil (circles).

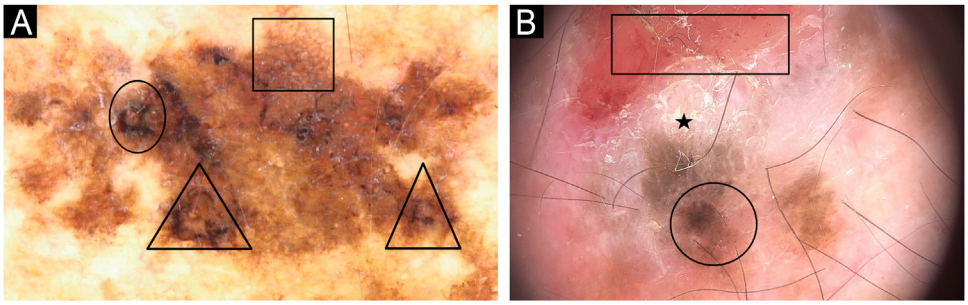

Figure 5 Melanoma *in situ*: (A) Dermoscopy showing atypical network (square), rhomboidal structure (circle) and angulated lines (triangle)(B) Desmoplastic melanoma: ulceration (rectangle), hyperkeratosis (star) and hyperpigmented excentric area (circle).

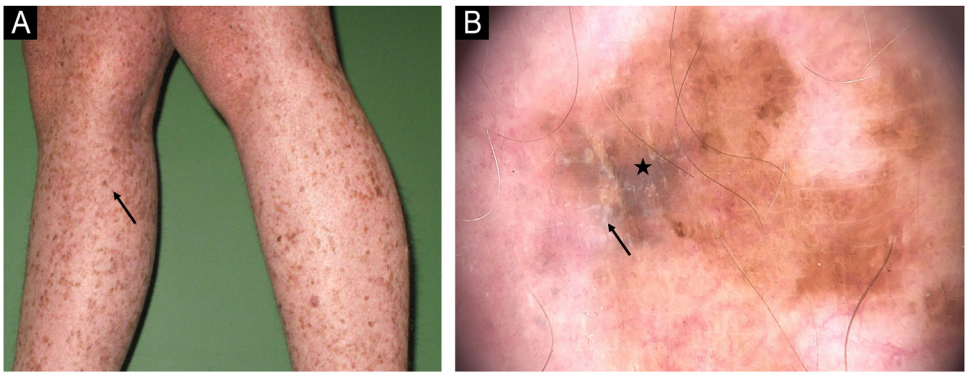

Figure 6 (A) Melanoma *in situ* on the right leg in a 15-year-old girl. (B) Dermoscopy showing shiny-white streaks (arrow) and blotch (star).

This data is similar to the literature about XP-V, in which symptoms occur later, and the patients have a longer life expectancy than the other groups.[19]

The skin of these patients was characterized by the presence of a great number of solar lentigines and poikiloderma on sun-exposed areas. This phenotype adds a challenge to the early diagnosis of skin cancers, even for an experienced dermatologist, either because of the presence of an extensive number of lesions with delicate pigment network from lentigines as well as the telangiectasia due to poikiloderma that can mimic the arborizing vessels described in BCC.[6]

Regarding melanocytic lesions, the majority of patients presented lentiginous lesions and the absence of common acquired (junctional, compound, dermal) and congenital nevi. These findings were similar to the study by Malvehy et al., which described phenotypic aspects from two siblings with XP.[6] Massaki et al. compared melanocytic lesions from XP and non-XP patients and showed histological differences: XP nevi are characterized by a lentiginous proliferation of single unit or small nests of melanocytes along the dermal-epidermal junction and often show attenuation of rete ridges, in contrast to the junctional nevi seen in general pop-

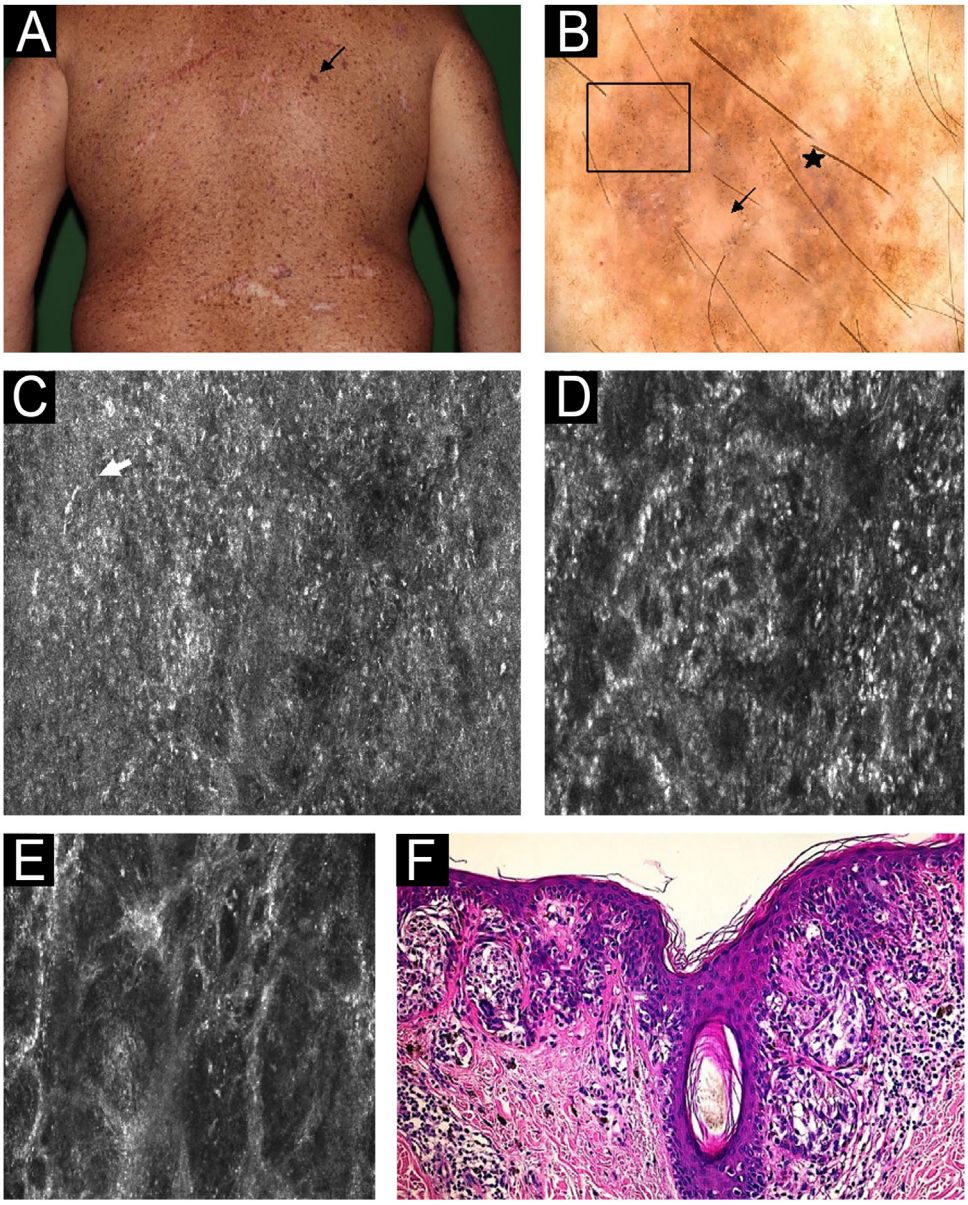

Figure 7 Melanoma *in situ* on the back in a 40-year-old man. (A) Clinical image: pigmented lesion on a photodamage skin (black arrow). (B) Dermoscopy: atypical dots and globules (square), peppering (star), structureless area (arrow). (C) Reflectance Confocal Microscopy (RCM); individual image (0.5 × 0.5 mm) of the spinous-granular layer. Disarranged pattern, presence of dendritic nucleated cells (white arrow). (D) RCM individual image (0.5 × 0.5 mm) of the dermoepidermal Junction (DEJ) area showing ringed pattern (center). (E) RCM at the DEJ individual image (0.5 × 0.5 mm) at the dermis showing atypical meshwork and non-edged papillae. (F) Histopathology: nested atypical melanocytes growing along dermoepidermal junction with pagetoid spread, involvement of adnexal structures and absence of dermal invasion. These microscopic features allow to confirm the diagnosis of Melanoma *in situ* (hematoxylin and eosin, 200×).

ulation which show elongated rete ridges with small nests of melanocytes along the tips and sides of the rete ridges.[18] This explains the dermoscopy pattern that the authors found in the follow-up during these years.

The most common dermoscopy feature observed in invasive melanomas was an atypical pigmented network, which was seen in 90% of cases. The blue-white veil was seen in 30% of cases, and shiny-white lines, described as associated with invasive melanoma by Lallas et al. and Silva et al. were observed in 10% of invasive melanomas.[26,27] More recently, Polesie et al. observed that shiny-white lines and atypical blue-white structures were both associated with a Breslow thickness >1 mm.[28] In the present findings, unlike what is reported in the literature, shiny-white lines were frequently observed in melanoma *in situ*, while blue-white structures were only associated with Breslow greater than 1 mm.

Total-body photography and digital dermoscopy were shown to improve the surveillance of high-risk groups by providing the benefit of not overlooking featureless melanoma and reducing the unnecessary excision of benign lesions.[5]

In addition, in XP patients, sun-damaged skin and high density of light to dark brown pigmented lesions, dermoscopy allows for the discrimination between the delicate pigment network of the multiple actinic lentigo from the true pigment network characteristic of melanocytic lesions. The digital follow-up in 3-, 6- or 12-months intervals that had already been proved to be effective for other high-risk groups, and in our opinion, is also effective in XP patients. Previous descriptions regarding the follow-up of XP patients using digital dermoscopy have already been published, although all of them have involved a small number of studied patients.[6–8,13,22]

In an attempt to improve the diagnostic accuracy in skin cancer detection, even for difficult-to-diagnose lesions and to avoid unnecessary excisions, RCM was performed in association with digital dermoscopy. During the XP patient surveillance, lesions with small changes in dermoscopy and the new ones showing atypical patterns without melanoma features were evaluated under RCM. The features described for melanoma in the general population were applied.[9,10,29]

The present study showed an improvement in diagnosing melanoma at earlier stages after the implementation of total body mapping, digital dermoscopy, and reflectance confocal microscopy in the XP patients (from 67% to 82% of melanomas *in situ*). The association of this cellular resolution technology as a complementary exam in doubtful lesions allowed for earlier melanoma diagnosis and avoided unnecessary excisions. Recently, Rocha et al showed 85.7% sensitivity and 46.8% specificity for melanoma diagnosis in XP patients using RCM.[12] This result validates the need for close and specialized follow-up of these high-risk patients by a specialized center with the aim of reducing the risk of advanced disease and mortality.

The NNE is an effective method to measure the accuracy in melanoma detection and has decreased significantly over time in specialized clinics dedicated to skin cancer because of the routine use of diagnostic techniques such as digital dermoscopy and reflectance confocal microscopy.[20,21] Argenziano et al showed in a 10-year multicenter survey an improvement from 12.8 to 6.8 in the NNE with the use of digital dermoscopy in the evaluation of melanocytic lesions.[19] More recently, RCM has demonstrated to be able to reduce the number of excised lesions, reaching numbers close to 3–6.[23,24] Despite the challenges of the follow-up in XP patients, this study found an NNE of 2.88, similar to the 2.87 previously published by Alarcon et al. using RCM and dermoscopy in general and XP patients.[12] Prior to the adoption of digital dermoscopy and RCM, the NNE was 4.02, indicating a 28% improvement.

XP patients are generally submitted to multiple surgical excisions from an early age, with high morbidity. The combined use of total-body photography, digital dermoscopy and RCM has great potential to promote the early diagnosis of cutaneous malignancies and avoid unnecessary excisions in an attempt to enhance the prognosis and quality of life of XP patients.

Editor

Sílvio Alencar Marques.

Financial support

None declared.

Authors' contributions

Joyce Gouvêa Freire: Statistical analysis; approval of the final version of the manuscript; conception and planning of the study; drafting and editing of the manuscript; collection, analysis, and interpretation of data; critical review of the literature; critical review of the manuscript.

Tatiana Cristina Moraes Pinto Blumetti: Approval of the final version of the manuscript; conception and planning of the study; drafting and editing of the manuscript; effective participation in research orientation; critical review of the literature; critical review of the manuscript.

Rafaela Brito de Paula: Drafting and editing of the manuscript.

Juliana Casagrande Tavoloni Braga: Approval of the final version of the manuscript; conception and planning of the study; drafting and editing of the manuscript; effective participation in research orientation; critical review of the literature; critical review of the manuscript.

Data Availability

The entire dataset supporting the results of this study was published in this article.

Conflicts of interest

None declared.

References

1. Yew YW, Giordano CN, Spivak G, Lim HW. Understanding photodermatoses associated with defective DNA repair: Photosensitive syndromes without associated cancer predisposition. J Am Acad Dermatol. 2016;75:873–82.
2. Fassihi H, Sethi M, Fawcett H, Wing J, Chandler N, Mohammed S, et al. Deep phenotyping of 89 xeroderma pigmentosum patients reveals unexpected heterogeneity dependent on the precise molecular defect. Proc Natl Acad Sci U S A. 2016;113:E1236–45.
3. Bhutto AM, Kirk SH. Population distribution of xeroderma pigmentosum. Adv Exp Med Biol. 2008;637:138–43.
4. Lehmann AR, Norris PG. DNA repair deficient photodermatoses. Semin Dermatol. 1990;9:55–62.
5. Vestergaard ME, Macaskill P, Holt PE, Menzies SW. Dermoscopy compared with naked eye examination for the diagnosis of primary melanoma: a meta-analysis of studies performed in a clinical setting. Br J Dermatol. 2008;159:669–76.
6. Malvehy J, Puig S, Martí-Laborda RM. Dermoscopy of skin lesions in two patients with xeroderma pigmentosum. Br J Dermatol. 2005;152:271–8.
7. Salerni G, Carrera C, Lovatto L, Puig-Butille JA, Badenas C, Plana E, et al. Benefits of total-body photography and digital dermatoscopy (''two-step method of digital follow-up'') in the early diagnosis of melanoma in patients at high risk for melanoma. J Am Acad Dermatol. 2012;67:e17–27.
8. Green WH, Wang SQ, Cognetta AB Jr. Total-body cutaneous examination, total-body photography, and dermoscopy in the

care of a patient with xeroderma pigmentosum and multiple melanomas. Arch Dermatol. 2009;145:910–5.
9. Pellacani G, Pepe P, Casari A, Longo C. Reflectance confocal microscopy as a second-level examination in skin oncology improves diagnostic accuracy and saves unnecessary excisions: a longitudinal prospective study. Br J Dermatol. 2014;171:1044–51.
10. Pellacani G, Guitera P, Longo C, Avramidis M, Seidenari S. The impact of in vivo reflectance confocal microscopy for the diagnostic accuracy of melanoma and equivocal melanocytic lesions. J Invest Dermatol. 2007;127:2759–65.
11. Pellacani G, Cesinaro AM, Seidenari S. Reflectance mode confocal microscopy of pigmented skin lesions – improvement in melanoma diagnostic specificity. J Am Acad Dermatol. 2005;53:979–85.
12. Alarcon I, Carrera C, Palou J, Alos L, Malvehy J, Puig S. Impact of in vivo reflectance confocal microscopy on the number needed to treat melanoma in doubtful lesions. Br J Dermatol. 2014;170:802–8.
13. Rocha L, Ferreira PS, Avancini J, Lourenço S, Barbosa CF, Colacique C, et al. In vivo confocal microscopy of dermoscopic suspicious lesions in patients with xeroderma pigmentosum: a cross-sectional study. J Am Acad Dermatol. 2020;83:1668–73.
14. Pehamberger H, Steiner A, Wolff K. In vivo epiluminescence microscopy of pigmented skin lesions. Pattern analysis of pigmented skin lesions. J Am Acad Dermatol. 1987;17:571–83.
15. Braga JCT, Barcaui CB, Pinheiro AM, Sortino AMF, Abdalla CMZ, Campos-do-Carmo G, et al. Reflectance confocal microscopy - Consensus terminology glossary in Brazilian Portuguese for normal skin, melanocytic and non-melanocytic lesions. An Bras Dermatol. 2024;99:100–10.
16. Moriwaki S, Kanda F, Hayashi M, Yamashita D, Sakai Y, Nishigori C. Xeroderma pigmentosum clinical practice guidelines revision committee. Xeroderma pigmentosum clinical practice guidelines. J Dermatol. 2017;44:1087–96.
17. Karass M, Naguib MM, Elawabdeh N, Cundiff CA, Thomason J, Steelman CK, et al. Xeroderma pigmentosa: three new cases with an in-depth review of the genetic and clinical characteristics of the disease. Fetal Pediatr Pathol. 2015;34:120–7.
18. Masaki T, Wang Y, DiGiovanna JJ, Khan SG, Raffeld M, Beltaifa S, et al. High frequency of PTEN mutations in nevi and melanomas from xeroderma pigmentosum patients. Pigment Cell Melanoma Res. 2014;27:454–64.
19. Argenziano G, Cerroni L, Zalaudek I, Staibano S, Hofmann-Wellenhof R, Arpaia N, et al. Accuracy in melanoma detection: a 10-year multicenter survey. J Am Acad Dermatol. 2012;67:54–9.
20. Carli P, De Giorgi V, Crocetti E, Mannone F, Massi D, Chiarugi A, et al. Improvement of malignant/benign ratio in excised melanocytic lesions in the ''dermoscopy era'': a retrospective study 1997–2001. Br J Dermatol. 2004;150:687–92.
21. Pezzini C, Kaleci S, Chester J, Farnetani F, Longo C, Pellacani G. Reflectance confocal microscopy diagnostic accuracy for malignant melanoma in different clinical settings: systematic review and meta-analysis. J Eur Acad Dermatol Venereol. 2020;34:2268–79.
22. Malvehy J, Puig S. Follow-up of melanocytic skin lesions with digital total-body photography and digital dermoscopy: a two-step method. Clin Dermatol. 2002;20:297–304.
23. Stanganelli I, Longo C, Mazzoni L, Magi S, Medri M, Lanzanova G, et al. Integration of reflectance confocal microscopy in sequential dermoscopy follow-up improves melanoma detection accuracy. Br J Dermatol. 2015;172:365–71.
24. Lovatto L, Carrera C, Salerni G, Alós L, Malvehy J, Puig S. In vivo reflectance confocal microscopy of equivocal melanocytic lesions detected by digital dermoscopy follow-up. J Eur Acad Dermatol Venereol. 2015;29:1918–25.
25. Sethi M, Lehmman AR, Fawcett H, Stefanini M, Jaspers N, Mullard K, et al. Patients with xeroderma pigmentosum complementation groups C, E and V do not have abnormal sunburn reactions. Br J Dermatol. 2013;169:1279–87.
26. Silva VP, Ikino JK, Sens MM, Nunes DH, Di Giunta G. Dermoscopic features of thin melanomas: a comparative study of melanoma in situ and invasive melanomas smaller than or equal to 1mm. An Bras Dermatol. 2013;88:712–7.
27. Lallas A, Longo C, Manfredini M, Benati E, Babino G, Chinazzo C, et al. Accuracy of dermoscopic criteria for the diagnosis of melanoma in situ. JAMA Dermatol. 2018;154:414–9.
28. Polesie S, Sundback L, Gillstedt M, Ceder H, Gyllencreutz JD, Fougelberg J, et al. Interobserver agreement on Dermoscopic features and their associations within situ and invasive cutaneous melanomas. Acta Derm Venereol. 2021;101:adv00570.
29. Braga JC, Macedo MP, Pinto C, Duprat J, Begnami MD, Pellacani G, et al. Learning reflectance confocal microscopy of melanocytic skin lesions through histopathologic transversal sections. PLoS One. 2013;8:e81205.

Anais Brasileiros de Dermatologia 2025;100(5):501198

SOCIEDADE BRASILEIRA DE DERMATOLOGIA

Anais Brasileiros de Dermatologia

www.anaisdedermatologia.org.br

REVIEW

Chronic spontaneous urticaria: update on pathogenesis and therapeutic implications☆

Paulo Ricardo Criado [a,b,*], **Roberta Fachini Jardim Criado** [a,c], **Hélio Amante Miot** [d], **Beatrice Martinez Zugaib Abdalla** [a], **Helena Zenedin Marchioro** [e], **Renan Rangel Bonamigo** [f,g]

[a] *Centro Universitário Faculdade de Medicina do ABC, Santo André, SP, Brazil*
[b] *Faculdade de Ciências Médicas de Santos (Fundação Lusíada), Santos, SP, Brazil*
[c] *Alergoskin Alergia e Dermatologia, UCARE Center and ADCARE, Santo André, SP, Brazil*
[d] *Department of Infectology, Dermatology, Diagnostic Imaging and Radiotherapy, Faculty of Medicine, Universidade Estadual Paulista, Botucatu, SP, Brazil*
[e] *Dermatology Residency, Hospital Irmandade Santa Casa de Misericórdia de Curitiba, Curitiba, PR, Brazil*
[f] *Service of Dermatology, Santa Casa de Porto Alegre, Porto Alegre, RS, Brazil*
[g] *Service of Dermatology, Hospital de Clínicas, Universidade Federal do Rio Grande do Sul, Porto Alegre, RS, Brazil*

Received 16 November 2024; accepted 29 January 2025
Available online 21 August 2025

KEYWORDS
Chronic urticarial;
Chronic urticaria/therapy;
Chronic urticaria/pathology;
Immunobiologicals;
Small molecules;
Urticaria

Abstract

Background: The understanding of chronic spontaneous urticaria pathogenesis has been increasing recently. The central role of mast cells is being reinforced, but multiple cells, pathways, and mediators are involved in a complex interrelationship. Modern therapies for its management reflect the need to encompass different mechanisms and promise to alter the course of urticaria and the long journey of those with refractory disease. Continuous updating of these aspects is necessary to optimize patient care.

Objectives: To review concepts and advances in the pathogenesis of chronic spontaneous urticaria, in addition to contextualizing promising drug options for its management.

Method: A narrative review was conducted between 1977 and 2024, including relevant articles published in the scientific literature, indexed in the PubMed system.

Results: A total of 25,732 articles were found. Inclusion criteria were determined by the authors' decision regarding their level of importance for furthering knowledge in the areas of pathogenesis and treatment of chronic spontaneous urticaria, with preference given to meta-analyses, systematic reviews, and randomized trials. Regarding therapeutics, 138 articles from the last 15 years were prioritized, in addition to records on ClinicalTrials.gov, and the drugs could be in the clinical trial phase. Immunobiologicals and small molecules hold promise for future treatment regimens for chronic spontaneous urticaria.

☆ Study conducted at the Centro Universitário Faculdade de Medicina do ABC, Santo André, SP, Brazil.

* Corresponding author.
E-mail: prcriado@uol.com.br (P.R. Criado).

https://doi.org/10.1016/j.abd.2025.501198

Study limitations: Narrative reviews do not provide statistical value to the results and outcomes studied.
Conclusion: A review of the pathogenesis of chronic spontaneous urticaria was conducted, contextualizing these aspects with promising drug options for its treatment, particularly immunobiologicals and small molecules.

Introduction

Urticaria is a cutaneous inflammatory process of varying intensity in which mast cell degranulation initially leads to vasodilation, increased capillary permeability, and dermal edema (hives), accompanied or not by subcutaneous and/or submucosal edema (angioedema).[1,2]

Mast cell degranulation results from several factors associated with cell receptors, physical stimuli, chemical stimuli, or those linked to immunity (innate and/or adaptive), which promote, within minutes, the release of preformed mediators (stored within intracytoplasmic granules). Newly formed mediators (lipid derivatives and cytokines/chemokines) are released minutes to hours after stimulation of these cells (Fig. 1 and Tables 1–3).[2] In general, infections/infestations, foods, and medications are the main causes of acute urticaria.

The main mediator responsible for the initial events of urticaria is histamine, which binds to H1 and H2 receptors on the vascular endothelium, determining the effects

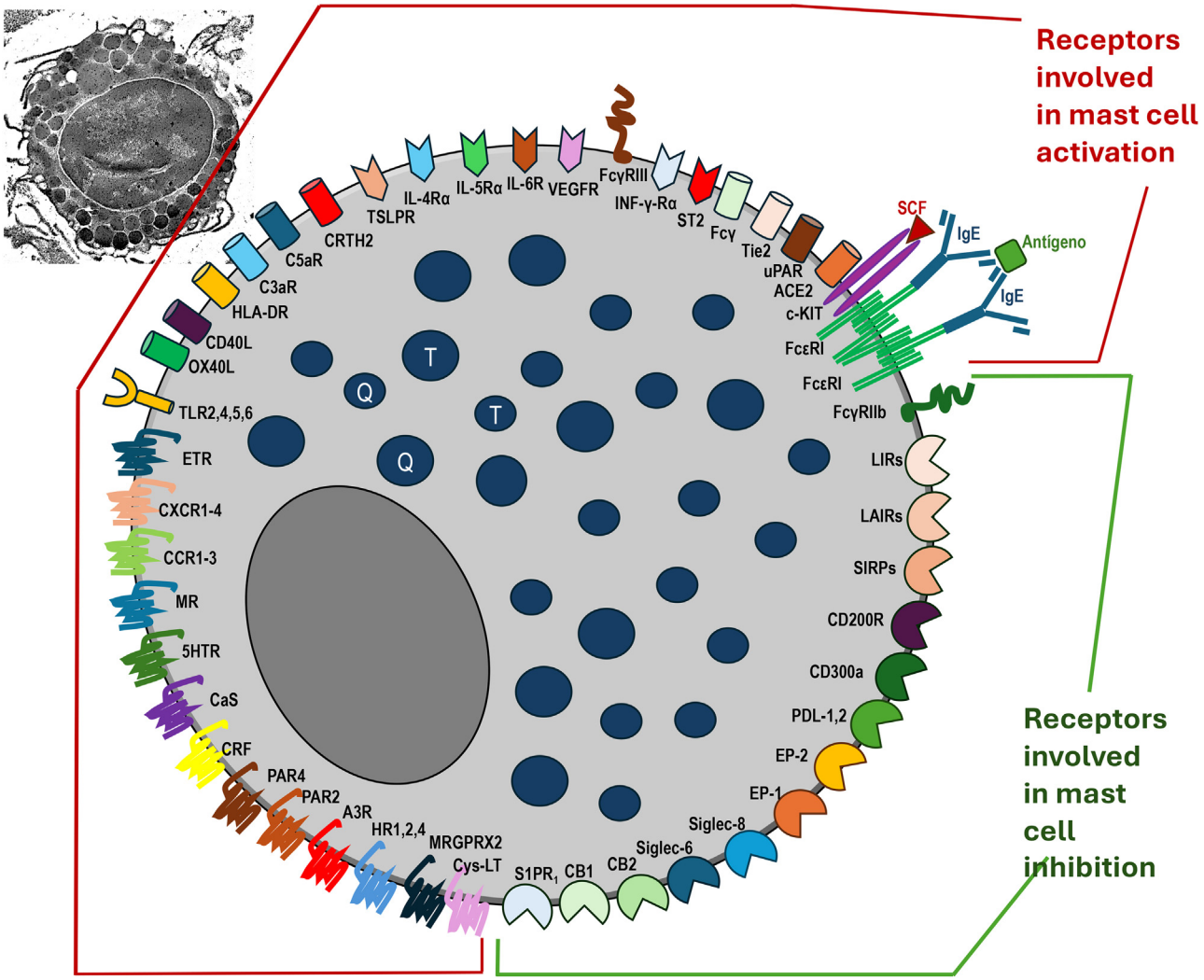

Figure 1 Mast cells and their receptors that stimulate activation, degranulation via IgE-dependent and non-IgE-dependent pathways, synthesis of newly formed mediators, and receptors that suppress mast cell activation. Top left, a still-intact mast cell in the non-urticaria skin of a patient with hives, under transmission electron microscopy (×10,000 magnification). T, Tryptase; C, Chymase.

Table 1 Main receptors, ligands and mediators that promote mast cell activation.

Receptors and Type of Mediators	Name	Functions/Actions
Immunoglobulin superfamily receptors	FcεRI	Expressed on mast cells and basophils as a tetramer composed of subunits (αβγ2), the α subunit responsible for binding the FcεRI receptor to IgE, the β subunit for regulating receptor expression and signaling, and the γ subunit responsible for signal transduction. FcεRI circulates free in the blood, either in a soluble form (sFcεRI) or bound to IgE. IgE binds to FcεRI with high affinity (Kd ∼10-9 to 10-10), and the dissociation half-life of IgE from FcεRI is very slow, on the order of weeks. Due to IgE's high affinity for the receptor and slow dissociation, there is long-lasting sensitization of mast cells exposed to specific antigens.
	FcγRIII	When activated by IgG1, in mice, it promotes anaphylaxis
G protein-coupled receptors	Mas-related G protein-coupled receptor X2 (MRGPRX2)	Expressed predominantly in mast cells of the skin, peripheral neurons, basophils, and eosinophils. Activated by eosinophil major basic protein (MBP) and eosinophil cationic protein, fluoroquinolone antibiotics, opioids, neuromuscular blockers, human β-defensin 2 (hBD2), cathelicidin (LL-37), neuropeptides (such as substance P), Calcitonin Gene-Related Peptide (CGRP), Vasoactive Intestinal Substance (VIP), Staphylococcus aureus δ-toxin, hormone receptor modulators, phenothiazines, corticostatin-14, icatibant, cetrorelix, leuprolide, octreotide, sermorelin, atracurium, tubocurarine, rocuronium, and herbal medicines.
	Histamine receptors H1, H2 and H4 (H1R, H2R and H4R)	The binding of histamine to its H1R on mast cells stimulates the release of more histamine and other mediators, increasing the expression of cell adhesion molecules and chemotaxis of eosinophils and neutrophils, in addition to increasing antigen presentation capacity and costimulatory activity in B cells, and suppressing IgE production. Histamine binding to the H2R inhibits mast cell chemotaxis, as well as that of eosinophils and neutrophils, suppressing Th2 responses. Stimulation of the H4R leads to increased intracellular calcium influx, mast cell degranulation, and the release of cytokines, cysteinyl leukotrienes, and leukotriene B4 (LTB4). It is also relevant to the histaminergic pathways of cutaneous sensory nerve endings that conduct pruritus.
	Adenosine receptor (A3R)	Adenosine receptors differ in the type of G protein they recruit, their effect on adenylyl cyclase (AC) activity, and the downstream signaling pathway they trigger. Adenosine can both increase and inhibit mast cell degranulation, indicating that its effects on these receptors are controversial and still need to be clarified. Depending on the study model, A1, A2b, and A3 receptors demonstrate anti- or pro-inflammatory activity.
	Cystil-Leukotriene Receptors	Cysteinyl leukotrienes (CysLTs), released from mast cells, are important mediators of allergy. Type 1 receptors for CysLTs (CysLT1Rs) are involved in accelerating IgE-mediated MC activation.
	Protease-activated receptor (PAR) types 2 (PAR2) and 4 (PAR4)	PAR2: can be activated by proteases (chymase, tryptase) PAR4: activated by thrombin.
	Corticotropin-releasing factor (CRF) receptor	CRF1 receptor: induces the release of VEGF. They are co-receptors of VEGFR-2.

Table 1 (*Continued*)

Receptors and Type of Mediators	Name	Functions/Actions
	Calcium sensor (CaS)	Increases mast cell activity.
	Serotonin receptor (5-HTR)	Amplifies mast cell activation
	Acetylcholine receptor (Muscarinic M)	Its binding to acetylcholine evokes mast cell degranulation.
	Chemokine receptors: CCR 1-3 and CXCR1-4	The CCR3 receptor has high affinity for eotaxin-1/CCL-11, eotaxin-2/CCL-24, and eotaxin-3/CCl-26 and mediates mast cell migration
	Endothelin receptor ($ET_{A,B}$)	Via this receptor, endothelin-1 determines mast cell degranulation and can induce the production of TNF-α and IL-6.
Activated complement receptors	C3aR	Activates mast cells, amplifying degranulation
	C5aR	Activates mast cells, amplifying degranulation
Maturation, differentiation, and activation receptor (type II receptor of tyrosine kinase)	c-Kit (CD117)	Its ligand targets Stem Cell Factor (SCF), for which it has high affinity (Kd —200 pM), causing receptor dimerization and phosphorylation of tyrosine residues. It is expressed in mast cells, hematopoietic and non-hematopoietic cells (such as melanocytes and interstitial cells of Cajal), and some tumors. In mast cells, it is expressed from their progenitors until their differentiation and maturation, and their development and survival depend on its activation by SCF, mediated intracellularly by the PI3K pathway, causing degranulation in response to allergens and cytokine production.
Neuropilin Receptors	Receptors NRP 1 and 2	Relevant in angiogenesis
Tyrosine kinase receptors for angiopoietin	Tie 1 and Tie 2	Its ligand is angiopoietin, which, together with VEGFs, is important for the proliferation, migration and survival of endothelial cells, including the formation of lymphatic vessels.
Neurokinin Receptor	NK1	This receptor is expressed when the mast cell is stimulated by IL4 or SCF.
Pattern Recognition Molecular Receptors (PAMPs and DAMPs)	TLR 1,2, 3,4, 5, 6,7, 8,9 e 10	Recognition of bacteria and fungi in particular, as well as peptides such as Gram-negative lipopolysaccharides (LPS), which can reach the bloodstream due to dysbiosis of the intestinal microbiome. Viral receptors (TLRs 3, 5, 7, and 9) are intracytoplasmic.
Major histocompatibility antigen	MHCII	HLA-DR
Sphingosine-1phosphate receptors	$S1PR_2$	Upregulates both allergen-induced degranulation and chemokine secretion
Glycosylphosphatidylinositol (GPI)-anchored cell surface receptor	CD48	Expressed on mast cells, eosinophils, and nearly all hematopoietic cells, including basophils, it is regulated by bacterial and viral products and immune-associated proteins. It is important as a costimulatory molecule in lymphocyte activation, facilitating cell adhesion and innate responses to bacteria (such as S. aureus and its exotoxins). Its soluble form (sCD48) is elevated in lymphoproliferative diseases, Sjögren's syndrome, and asthma compared to healthy individuals.
Receptors of Interleukins and Other Cytokines	IL-33	ST2 receptor: its ligand, IL-33, is a member of the IL-1 superfamily, initiating and amplifying the responses of type (2) innate lymphoid cells by stimulating the synthesis of IL-5 and IL-13 by these cells. IL-33 is also synthesized by mast cells after IgE-mediated activation and acts autocrinely on the mast cells themselves, stimulating them. IL-33 produced by the bronchial epithelium stimulates mast cells to produce IL-1β and IL-6, inducing the differentiation of Th0 lymphocytes into the Th17 phenotype after challenge with ovalbumin (OVA).

Table 1 (*Continued*)

Receptors and Type of Mediators	Name	Functions/Actions
	IL-4	IL-4 Rα (type I) and IL-4Rα coupled to IL-13Rα2 (type II): when IL-4 binds to these receptors, it decreases mast cell proliferation, increases the expression of ICAM-1 (Intercellular Adhesion Molecule-1) and reduces the expression of c-Kit, but in synergy with SCF, IL-4 promotes mast cell proliferation and directs the production of cytokines in the IgE-dependent pattern.
	IL-5	IL-5Rα: activates mast cells, but is crucial for stimulating eosinophils, prolonging their survival, activation, adhesion to endothelial cells, differentiation and maturation, in addition to promoting the interaction between mast cells and eosinophils
	IL-6	IL6R: activated by IL-6, also synthesized by mast cells and innate immunity
	Vascular endothelial growth factor (VEGF) types 1 and 2	VEGF1R and VEGF2R: Mast cells can express receptors for VEGF, which they produce.
	Interferon gamma receptor	INFγ-Rα: INFgamma can determine mast cell apoptosis.
	Thymic Stromal Lymphopoietin (TSLP)	TSLPR: is a heterodimer composed of the α-chain and α-chain of IL-7R, and is the target of TSLP, produced primarily by epithelial and endothelial cells, which causes differentiation and proliferation of mast cells. It also induces the production of chemokines and the synthesis of Th2-type cytokines.
Prostaglandin D2 Receptor	CRTH2 or DP2	PGD2 is the main metabolite derived from arachidonic acid, released by IgE-activated mast cells. CRTH2 or DP2 is present intracellularly in mast cells and on the membranes of other cells such as LTh2, eosinophils, basophil macrophages, and dendritic cells. By binding to the PGD2 receptor, it mediates cell chemotaxis and promotes degranulation of mast cells, basophils, and eosinophils.
Costimulatory molecules	CD40L (CD154)	Transmembrane glycoprotein that binds CD40 on other immune cells, such as CD4+ T cells and platelets. The interaction between CD40L and CD40 on B cells is relevant for immunoglobulin class switching and memory B cell generation. Blocking the CD40L-CD40 interaction reduces the generation of regulatory T cells (Tregs). Activation of CD40 allows the expression of costimulatory molecules such as CD80 and CD86.
	OX40L (CD134L)	Involved in interaction with antigen-presenting cells (macrophages). Interacts with OX40 (CD134) of T lymphocytes, including promoting Th17-dependent inflammation, together with TNF-α and IL-6. The interaction between OX40L and its ligand OX40 on T cells induces T cell expansion and proliferation and decreases the immunosuppressive effect of regulatory T cells (Treg)
Angiotensin-converting enzyme type 2 receptor	ACE2	Studies demonstrate its presence in mast cells of the respiratory tree.

Table 2 Main receptors, ligands and mediators that suppress mast cell activation.

Receptors and Type of Mediators	Name	Functions/Actions
Cannabinoids	CB1	Under the action of endocannabinoids (anandamide and 2-arachidonoylglycerol), it promotes regulatory actions. In mast cells, it has anti-inflammatory effects, with CB1 suppressing mast cell degranulation by increasing cytosolic cAMP levels.
	CB2	Under the action of endocannabinoids (anandamide and 2-arachidonoylglycerol), it promotes regulatory actions. In mast cells, it has anti-inflammatory effects by suppressing the release of pro-inflammatory mediators.
Sphingosine-1phosphate receptors	$S1PR_1$	Its activation by agonists decreases allergic inflammation in the airways and reduces the accumulation of eosinophils and T cells
Immunoglobulins	FcγRIIb (low-affinity receptor for IgG type b) (expressed only in mice, but not in human mast cells)	In murine mast cells, FcγRIIb can cross-link adjacent FcεRI on the cell membrane with the same multivalent ligand and form an immune complex and inhibit FcεRI-dependent mast cell activation, preventing degranulation and synthesis of newly formed mediators.
CD300 Family	CD300a	Its ligands are phosphatidylserine and phosphatidylethanolamine (expressed in the early stages of apoptosis/cell death) as membrane signals for phagocytosis. In the intracellular space, its action activates the SHP-1 protein, dephosphorylates SYK, and decreases intracellular calcium influx. CD300a expression on mast cells can be inhibited by eosinophil major basic protein (MBP) and eosinophil-derived neurotoxins.
Siglecs Family (sialic acid-binding immunoglobulin-like lectins)	Siglec-6	Its activation prevents mast cell activation.
	Siglec-7	Its activation results in inhibition of mediator release via FcεRI-dependent pathway, by cross-linking with adjacent FcεRI on the cell membrane.
	Siglec-8	Stimulated by IL-5, IL-33, or GM-CSF, mast cell apoptosis is induced. Activation of mast cell mediators results in FcεRI-dependent inhibition of mast cell mediator release.
Leukocyte Ig-like receptor (LIR)	Inhibitory receptors LIR-1, LIR-2 and LIR-3	LIR-1 is expressed in mature mast cells and LIR2 and LIR-3 in mast cell progenitors. They promote inhibition of mast cell activity.
Membrane glycoprotein receptor belonging to the SIRP family	SIRP-α	Its activation inhibits FcεRI-mediated mast cell activation in mice
CD200R	CD200R	Its activation inhibits FcεRI-mediated mast cell activation
c-lectin mast cell function-associated antigen (a variant of lectin-like type II transmembranal glycoprotein)	MAFA	Inhibits degranulation and cytokine release by IgE-activated mast cells in rat mucosa
Platelet-Endothelial Cell Adhesion Molecule-1	PECAM-1	Its activation inhibits FcεRI-mediated mast cell activation
Leukocyte-associated I-like receptor (LAIR)	LAIR-1	Its activation results in the reduction of preformed mediators and the release of cytokines. Its ligand is collagen.

Table 2 (*Continued*)

Receptors and Type of Mediators	Name	Functions/Actions
Prostanoid-E Receptors	EP2 e EP4	Prostaglandin E2 (PGE2) binds to the EP2 receptor and inhibits mast cell degranulation, cytokine transcription, and eicosanoid production via stimulation of FcεRI. Binding to EP4 inhibits mast cell activation. One of the mechanisms of urticaria caused by nonsteroidal anti-inflammatory drugs is the decrease in PGE2 synthesis and loss of its mast cell-silencing mechanisms.
Programmed death receptor	PDL1	Induces mast cell apoptosis

of vasodilation, increased capillary permeability (in conjunction with other mediators released by mast cells), and pruritus, its cardinal symptom, initially caused by stimulation of histaminergic cutaneous sensory pathways (via H1 and H4 receptors) and the action of tryptase.[2]

Hives are transitory, generally lasting in the same location for no more than 24 hours, while angioedema is more long-lasting (varying between 48 and 96 hours).[1] Urticaria is classified according to its temporal evolution as acute (<6 weeks) or chronic (>6 weeks). Although hives are common in Chronic Urticaria (CU), 43% to 59% of patients also present with angioedema; however, approximately 10% present with angioedema alone (mast cell angioedema).[1]

Over time, in addition to pre-synthesized substances (histamine, tryptase, and other proteases) released by damaged mast cell granules, ''de novo'' synthesized mediators, such as lipid derivatives (prostaglandins and leukotrienes) and cytokines/chemokines, are released by mast cells, activating the cutaneous vascular endothelium (expression of cell adhesion molecules such as PECAM-1/CD31, E-selectin, P-selectin, ICAM-1, VEGF expression, and tissue factor production), and leading to the chemotaxis of other blood cells to the skin, such as basophils, lymphocytes, eosinophils, and neutrophils. These recruited cells, like a feedback loop, determine the establishment of chronic and intermittent inflammatory responses in distinct areas of the skin, which are recurrent and of varying intensity. Other mediators, besides histamine, play a key role in the chronicity of the disease.[2]

Conceptually, Chronic Urticaria (CU) is classified as induced: related to identifiable and generally external triggering stimuli, such as cold, heat, pressure, water, solar radiation, or even cholinergic or symptomatic dermographism; or spontaneous, when the trigger is not always the same, appearing in different situations throughout the disease's history.[1]

This article aims to present a review of the pathogenesis of Chronic Spontaneous Urticaria (CSU), as well as to support the rationale for its current and developing therapies.

Methods

This narrative review addressed the literature from January 1977 to October 2024, in PubMed/Medline, using the terms (*idiopathic* OR *spontaneous* = 4.169) AND *urticaria*, *prevalence* AND *urticaria* (3.320), *genetic* AND *urticaria* (2.486), *autoantibodies* AND *urticaria* (766), *coagulation* AND *urticaria* (757), *gut* AND *microbiota* AND *urticaria* (43), *stress* AND *urticaria* (482), *treatment* AND *urticaria* (13.709), totaling 25.732 articles. The authors selected relevant articles on these topics that have provided advances in these areas. Priority was given to articles and records in Clinical Trials (ClinicalTrials.gov) addressing aspects of the pathogenesis of chronic spontaneous urticaria, its currently recommended treatment, and the prospects for new medications such as small molecules or biological agents.

Prevalence and Natural History of Urticaria

Different population groups have variable prevalence rates for CU. Latin America has the highest prevalence, 1.5% (95% CI 0.0–6.0), followed by Asia, 1.4% (95% CI 0.5–2.9), Europe, 0.5% (95% CI 0.2–1.0), and North America, 0.1% (95% CI 0.1–1.0). Women are more affected by CU than adult men, while no gender differences were observed in children.[3]

In Brazil, a retrospective study estimated a 1.7% prevalence of CU among dermatological patients.[4] Another study, which analyzed retrospective data from 2011, 2012, and 2015, from a national health and well-being survey with 36,000 respondents, resulted in a 0.41% prevalence of CU.[5] In Brazil, two studies demonstrated a higher incidence of CU in adults among women, with estimates ranging from 80%[4] to 86%.[6]

There is little published data on the natural history of urticaria, and some of it has methodological limitations, most focusing on the duration of CSU.[7] In general, the frequency of progression of acute urticaria (AU) cases to CU is not adequately explored, and some studies are conducted in hospital settings rather than population-based.[7]

In an evaluation of data from the Korean national healthcare system between 2002 and 2013, with a population sample of 1,025,340 individuals, a total of 4.8% were identified with urticaria, which determined its annual incidence rate ranging from 45.7 to 82.5 per 100,000 person-years.[7] In this study, among all patients with urticaria; 6.1% were identified with progression to CU. Among these; 46.6% already had CU when they were first diagnosed with urticaria. The remainder had AU at their first diagnosis, but they subsequently developed CU when the disease recurred after a median of 614 days.[7] Over the five-year and ten-year periods, the cumulative incidence rates of CU among all patients with urticaria ranged between 6.3% and 7.8%, respectively,

Table 3 Major preformed and newly formed receptors, ligands and mediators.

Receptors and Type of Mediators		Name	Functions/Actions
Preformed (generally stored in granules of 0.2 to 0.8 μm in diameter, of skin mast cells. TC mast cells, chymase-tryptase positive)	Amines	Histamine	Vasodilation, expression of VCAM in the vascular endothelium activating endothelial cells, increased capillary permeability, stimulation of pruritus
		Polyamines	Vasodilation
	Proteoglycans	Heparin	Anticoagulation
		Chondroitin sulfate	Inhibits the activation of other connective tissue mast cells
		Serglycin	Proteoglycan to which heparin binds and whose function is to maintain the homeostasis of mast cell granules to be secreted.
	Proteases	Tryptases (expressed only in mast cells)	Tryptase-α, Tryptase-βI Tryptase-βII, Tryptase-βIII, Tryptase-γ, Tryptase-δ: Increased capillary permeability, stimulation of pruritus via PAR2
		Chymase-1 (expressed only in skin mast cells)	Protease stored in skin mast cell granules, promoting inflammation and tissue destruction
		Cathepsin G	
		Carboxypeptidase A	
		Granzyme B 3	
	Lysosomal enzymes	β-glucoronidase	Glycosidase that participates in the catabolism of mucopolysaccharides
		β-Hexosaminidase	Involved in hydrolysis mechanisms.
		Arylsulfatase	Catalyzes reactions of sulfonated hexoses.
	Cytokines	TNF-α	Stimulates TH1 polarization
		bFGF	Stimulation of fibroblasts in the regeneration of the intercellular matrix
		IL-4	Stimulates type 2 inflammation
		SCF	Maturation, differentiation and increased survival of mast cells
		VEGFb	Increased capillary permeability and angiogenesis
Neoformed (synthesized minutes to hours after mast cell stimulation)	Lipids	Prostaglandin D2 (PGD2)	Vasodilation and increased capillary permeability Recruitment and activation of Th2 lymphocytes Chemotaxis and activation of basophils and eosinophils Migration of type 2 innate immune lymphoid cells (ILC2)
		Leukotriene B4 (LTB4)	Chemotaxis of neutrophils, mast cells, and dendritic cells Recruitment of CD8+ lymphocytes
		Leukotriene C4 (LTC4)	Eosinophil migration
		Leukotriene D4 (LTD4)	Migration of eosinophils and neutrophils
		Leukotriene E4 (LTD4)	Migration of eosinophils and ILC2
		Prostaglandin E2 (PGE2)	Stabilization of mast cells and their decreased activation and migration of dendritic cells
		Platelet activating factor (PAF)	Vasodilation, increased capillary permeability, increases adhesion of blood cells to the vascular endothelium and promotes migration to the extravascular space
	Cytokines	Interleukin-1 (IL-1) (increased serum expression in CSU)	Recruitment of eosinophils, neutrophils, migration of dendritic cells, activation of the inflammasome; IL-1β determines plasma extravasation from vessels

Table 3 (*Continued*)

Receptors and Type of Mediators	Name	Functions/Actions
	Interferon type I (INF-α and INF-β) and II (INF-γ and has decreased serum expression in CSU)	Secreted in viral infections such as respiratory syncytial virus. It leads to the aggregation of lymphocytes, eosinophils, mast cells, macrophages, and neutrophils.
	IL-2 (increased serum expression in CSU)	Proliferation of effector T lymphocytes and B lymphocytes; development of Treg cells; growth factor for B lymphocytes and stimulation of antibody synthesis
	IL-3 (increased expression in CSU lesions)	Activation of eosinophils and basophils; enhancement of FcεRI expression in basophils and stimulation of their longer survival
	IL-4 (increased serum expression in CSU)	Activation of T lymphocytes and basophils; increased humoral immunity; recruitment of eosinophils; differentiation from Th0 to Th2 with induction of type 2 inflammatory response and monocytes; differentiation into M2 macrophages; factor of increased survival for T and B lymphocytes; promotes immunoglobulin class switching, determining the production of IgE and IgG1 by B lymphocytes.
	IL-5 (increased serum expression in CSU)	Increase in the number of eosinophils due to increased adhesion and chemotaxis capacity to the skin.
	IL-6 (increased serum expression in CSU)	Differentiation of B lymphocytes and subsequent production of IgG, IgM and IgA; increased mast cell proliferation, maturation and reactivity (priming)
	IL-8 (increased serum expression in CSU)	Acts as a chemoattractant for T lymphocytes, basophils, eosinophils, NK cells, and neutrophils
	IL-9 (increased serum expression in CSU)	Acts as a growth factor for mast cells and T lymphocytes; inhibits Th1-type cytokines and promotes the proliferation of CD8+ lymphocytes and mast cells
	IL-10 (increased serum expression in CSU)	Inhibits Th1 and Tc1 cell function; activates B lymphocytes and induces autoantibody production by B cells
	IL-12	Recruitment of CD8+ T lymphocytes; induction of Th1 lymphocyte responses
	IL-13 (increased serum expression in CSU)	Activation of mast cells and eosinophils; increased eosinophil survival
	IL-16	T lymphocyte recruitment and dendritic cell migration
	IL-17A (increased serum expression in CSU)	Induction of pro-inflammatory cytokines and chemokines, with recruitment of neutrophils
	IL-18	Dendritic cell migration
	IL-25 (increased expression in CSU lesions)	Induction of Th2 responses and inhibition of Th1 and Th17 responses; induction of the production of IgE and IgG1, IL-4, IL-5, IL-9 and IL-13

Table 3 (*Continued*)

Receptors and Type of Mediators		Name	Functions/Actions
		IL-31 (increased serum expression in CSU)	Induction of IL-6 and IL-8, CXCL1, CXCL8, CCL2 and CCL8 in eosinophils
		IL-33 (increased serum expression in CSU)	Increases allergic stimulation of mast cells and basophils; induces IL-31 production in mast cells; increases integrin expression in basophils and eosinophils, leading them to the skin; promotes mast cell maturation
		TNF-α (''de novo'' synthesis: increased serum expression in CSU)	Promotes activation of endothelial cells, proliferation of effector T lymphocytes, increases the expression of ICAM-1 in eosinophils allowing them to migrate to the skin; activation of monocytes and macrophages, recruitment of neutrophils and proliferation of T lymphocytes
		GM-CSF	Determines migration of dendritic cells to lymph nodes
	Chemokines	CCL1	Recruitment of T cells and monocytes
		CCL2	Recruitment of T cells, monocytes, and neutrophil migration
		CCL3	Recruitment of T cells and monocytes
		CCL4	Recruitment of T cells and monocytes
		CCL5	Recruitment of CD8+ T cells, monocytes, basophils, eosinophils, NK cells and dendritic cells
		CCL7	Recruitment of T cells: monocytes, basophils, eosinophils, NK cells, immature dendritic cells, and hematopoietic progenitor cells
		CCL18	Recruitment of naive T cells, CD4+ and CD8+ T lymphocytes, memory T lymphocytes, B lymphocytes, and immature dendritic cells
		CCL20	Recruitment of B lymphocytes, memory effector T lymphocytes, recruitment of CD11b+ dendritic cells
		CXCL1	Neutrophil recruitment
		CXCL2	Recruitment of neutrophils, basophils, and eosinophils
		CXCL3	Neutrophil recruitment
		CXCL8	Recruitment of neutrophils and CD4+ T lymphocytes
		XCL1	Dendritic cell migration and antigen cross-presentation
		CXCCL1	Recruitment of monocytes and T lymphocytes and increased survival

and approximately 50% of patients with CU experienced remission after 11 months of disease, with CU remission rates ranging from 52.6% in the first year of disease, 78% in the third year, and 89% at 5 years.[7]

Higher financial income was associated with higher CU remission rates.[7] Furthermore, the study demonstrated that several other clinical factors interfered with the progression to CU, conferring a higher risk: age ≥ 10 years, male gender, urban residence, and autoimmune thyroid disease. Women were more affected by AU than men in the age range between 20–44 years and 45–64 years, which may be linked to estrogen, which stimulates humoral immunity.[7]

Regarding the average duration of CSU, in patients aged ≥12 years, it is estimated to last approximately five years, although it can persist for longer periods in severe cases.[8] In a review that included eight observational studies and two reviews, aimed at determining the duration of the CSU course and disease remission rates, the average age ranged from 34 to 68 years, and the proportion of women ranged from 61% to 80%.[8] The proportion of patients who achieved CSU remission within the first year of disease ranged from 21% to 47%, while remission rates reported in the fifth year of disease were between 34% and 45%.[8] Based on a four-week consecutive CSU remission, cumulative remission rates ranged from 9% to 38% in the first year, from 29% to 71% in the fifth year of disease, and from 52% to 93% in the twentieth year of CSU.[8]

Chronic pruritus without hives or angioedema occurred in 12.2% of patients. There was a greater likelihood of CSU persisting in patients diagnosed with hypothyroidism (HR = 0.43; 95% CI 0.29–0.60) and with each point increase in the UAS7 severity score (HR = 0.93; 95% CI 0.92–0.95).[9]

Thus, regarding the natural course of the disease, urticaria is a condition that will affect approximately 10% to 20% of the world's population at some point in their lives. There is a consensus that acute spontaneous urticaria is common; however, it is often associated with upper respiratory tract infections. Most of these infections are self-limited, and less than 10% progress to CU, although some studies indicate higher rates.[7,10,11] CU, in turn, persists for periods of > 1 year in most patients, significantly impairing quality of life, causing psychiatric and systemic comorbidities, and incurring high costs to the healthcare system.[7,8,10,11]

Genetic and Epigenetic Basis

CU is a multifactorial disease, in which the hypersensitivity reaction is based on a genetic and epigenetic basis that inflicts susceptibility.

Regarding histocompatibility antigens, HLA-Bw35 has been associated with CU and other endocrine diseases in the Japanese population.[12] CD4+ T lymphocytes in the infiltrate, as well as vascular endothelium, sweat glands, and nerves, express HLA-DR.[13–15]

In Caucasian patients with CSU, a strong association with HLA-DRB1*04 (HLA-DR4) was found in patients who manifested histamine-releasing activity in their serum, demonstrating that, despite being heterogeneous, CU has an autoimmune pathogenesis in a subgroup of patients.[16]

In a sample of Chinese individuals, CSU patients had lower methylation in 439 genes, with 86.5% of these genes hypomethylated, especially on chromosome 6, suggesting an autoimmune behavior similar to diseases such as rheumatoid arthritis, multiple sclerosis, and lupus. The study also identified that the sphingolipid pathway, particularly sphingosine-1-phosphate (S1p), may be involved in CSU, as hypomethylation increases its production, influencing inflammation and the immune response. Indeed, the prevalence of autoimmune diseases in CSU patients is high, and many have specific antibodies and a family history of autoimmunity.[17,18]

Under homeostatic conditions, S1p levels are low in tissues, but mast cells can release S1p in response to stimuli, which increases capillary permeability and recruits immune cells, contributing to allergic inflammation. S1p, through the s1p1 receptor, promotes Th17 T-cell differentiation and can polarize lymphocytes toward the Th2 immunophenotype, in addition to suppressing the differentiation of thymic and extrathymic T-regulatory (LTreg) cells, leading to chronic inflammation.[19] The autocrine effect of s1p on sip2 receptors on mast cells themselves leads to degranulation.[19]

In a GWAS study, CSU was associated with SNPs in the genes TDGF1, HLA-G, PTPN22, LILRA3, and IGHG1/IGHG2, which explain 8.07% of CSU heritability at the estimated disease prevalence point of 0.5%–1% in the general population. The first three are associated with CSU autoimmune phenotypes.[20] These alterations underlie macrophage activation in the pathogenesis of CSU.[20,21]

The TDGF1 gene increases the phagocytic activity of macrophages and stimulates the production of pro-inflammatory and anti-inflammatory cytokines through the NF-Kb pathway.[20,22] The transcription factor c-Maf determines the production of IL-10 by type 2 phenotype macrophages (M2 macrophages), helping to perpetuate inflammation mediated by Th2 lymphocytes, which maintain the inflammatory process and contribute to the chronicity of urticaria.[20,21] The HLA-G gene identified among the alleles of SNPs related to CSU encodes HLA-G, an HLA class I molecule that induces immunotolerance by suppressing the functions of NK cells, CD4+ and CD8+ T cells, and dendritic cells. Therefore, elevated levels of soluble HLA-G are observed in patients with allergic rhinitis and asthma, which correlate with serum IgE specific to allergens.[20,23]

Two studies demonstrated an association between CSU and autoimmune diseases with the CRTH2[24] and ORAI1 genes.[25] Other studies indicated a relationship between CSU and the HLA-DRB1*04,[26] HLA-DRB1*01, HLA-B44 and HLA-DRB*15 alleles,[27] TGF-β1,[28] PTPN22 (a factor that regulates the production of anti-TPO and anti-TG IgG)[29] and IL-2.[30] In particular, the presence of an association between CSU and the CRTH2 and TGF-β1 genes is related to cases associated with allergic/atopic asthma, and with HLA-DRB1*01, HLA-B44 and HLA-DRB*15 with autoimmune diseases, but not atopic disease.[20]

In a study with knocked-down Human Mast Cell Line-1 (HMC-1) after incubation with thrombin to mimic the pathogenesis of CSU, Fang et al.[31] observed the relevance of the CCL2 (Chemokine C-C motif ligand-2) and CH25H (Cholesterol 25-Hydroxylase) genes and the tumor necrosis factor signaling pathway.

In another GWAS study, two loci associated with CSU risk were identified: HLA-DQA1 and ITPKB. Inositol 1,4,5-Triphosphate Kinase B (ITPKB) is part of a family of kinases

that phosphorylate inositol as a second messenger in the calcium signaling pathway.[32] The regulation of inositol-1,4,5 is involved in neuronal signaling and immune function, including mast cell and basophil degranulation, suggesting that ITPKB may play a role in the loss of tolerance in CSU and enhance calcium-dependent secretion responses in mast cells.[32]

Based on these models, stimulated primarily by exogenous factors, a small proportion of patients with acute urticaria, under the influence of endogenous factors (such as genetic and epigenetic aspects), interact within the phenotypic spectrum of CSU, where different HLAs and gene polymorphisms determine a breakdown in immune tolerance, with a predisposition to the disease and an association with other autoimmune conditions, which together determine the background of the disease pathogenesis (Fig. 2).

Pathogenesis

The pathogenesis of CSU is centered on the activity of mast cells, whose degranulation in the skin and subcutaneous/submucosal tissues leads to the formation of hives and angioedema, and its cardinal symptom, pruritus. Therefore, CSU is considered a mast cell-dependent disease, with the participation of basophils and other cell elements that are attracted to the skin, involving various immune mechanisms such as autoimmunity, inflammation, coagulation factors, and activation of mast cell membrane receptors (Figs. 3 and 4), which cause chronic inflammation.[10,32]

Several authors classify CSU as an autoimmune disease, due to genetic findings and the coexistence of other autoimmune diseases.[32]

Malmros H.[33] in 1946 described the first finding of what is termed an ''autoreactivity'' phenomenon in CU patients, when he injected the own serum (autologous serum) of six CU patients, as in an intradermal test, and observed the formation of erythema and hives within 30 minutes of the injection, suggesting passive transfer of antibodies. Subsequently, in 1986, it was demonstrated that seven of 12 tests of autologous serum from patients with Chronic Idiopathic Urticaria (CIU) reinjected intradermally, produced erythema and hives at the injection site.[33–35]

In recent decades, considerable discoveries have been revealed about the mechanisms involved in mast cell activation, with the description of new activating and inhibiting receptors expressed on their cell membrane surface.[36] Most mast cell progenitors already express the c-Kit receptor and FcεRI on their membrane, which are essential for the survival and activity of these cells.[36] Different cytokines, chemokines and adhesion molecules, such as IL-4, IL-5, IL-6 IL-15, TNF-α, CCL-2 and vascular cell adhesion molecule (VCAM-1) released into the tissue microenvironment regulate the expansion, homing and maturation of mast cell precursors. However, the binding of Stem-Cell Factor (SCF) to the c-Kit receptor remains the most potent signal of mast cell differentiation, proliferation, and survival.[32] Different authors have described the presence of IgG and IgM autoantibodies directed against IgE and/or its membrane receptor alpha subunit (FcεRIα),[37–40] in addition to basopenia in the peripheral blood of these patients.

Subsequent advances led to the understanding of the existence of two main autoimmune mechanisms that determine the so-called ''autoreactivity'' in patients with CSU: type I autoimmunity (or autoallergic, aaCSU), primarily mediated by IgE specific to self-antigens (endogenous peptides),[41] with IgE directed against serum thyroperoxidase, and type IIb autoimmunity (autoimmune CSU, aiCSU), mediated by IgG,[38] and to a lesser extent also by IgM and IgA, directed against IgE or the FcεRIα receptor, expressed on mast cells and basophils.[32]

Both mechanisms (endotypes) suggest the common principle that CSU is fundamentally an autoimmune disease, not influenced by exogenous agents/factors.[42] However, the observation that autoantibodies are not always detected in patients with CSU indicates that mechanisms other than autoimmunity, whether immunological or non-immunological, are involved in the pathogenesis, contributing to the understanding of different CSU phenotypes.[32]

Type I/aaUCE is inherent in the existence of IgE antibodies to several currently recognized antigens such as thyroperoxidase or thyroid peroxidase (TPO), thyroglobulin (TG), tissue factor (TF), eosinophil peroxidase (EPO), double-stranded DNA (dsDNA), eosinophil cationic protein (ECP), interleukin-24 (IL-24), and IgE anti-FcεRI.[11,42,43] The most common autoantigens are TPO and IL-24, and IgE-antiTPO and IgE-antiIL-24 demonstrate *in vitro* the activation of mast cells and/or basophils.[42,44,45] IgE anti-IL-24 is present in approximately 70% to 80% of patients with CSU, and its serum concentration in patients with CSU correlates with disease activity.[44]

When the patient's autologous serum (autohemotherapy) was used to treat CSU, the Autologous Serum Test (ASST) was negative in 28% and 34% of patients, respectively, at weeks 9 and 21. However, this did not correlate with the overall response to treatment, as there was a reduction of slightly more than 50% in the antihistamine doses required for CSU treatment compared to the period prior to autohemotherapy.[46] The selective activation of mast cells in the skin by IgE autoantibodies can be explained by the occurrence of certain autoallergens, expressed almost exclusively in the skin, such as IL-24, and cross-reactivity with certain proteins, such as TPO (absent in the skin) and EPO (expressed in the skin).[42]

Type IIb/ai CSU occurs in the form of IgG anti-FcεRIα in approximately 20%–50% of patients.[11,47] These autoantibodies activate mast cells and basophils, for example via IgE and FcεRI, but are present in 8% of patients with CSU when strict criteria are applied, which include the presence of triple positivity in the following tests: ASST, immunoassay for IgG autoantibodies, and Basophil Activation Test (BAT).[47] Type IIb autoimmune CSU is characterized by the presence of high disease activity (elevated UAS7), concomitant with other autoimmune diseases (such as Hashimoto's thyroiditis), low serum levels of total IgE, high levels of IgG anti-thyroid peroxidase (TPO) antibodies, basopenia (< 10 cells/μL) and eosinopenia (< 50 cells/μL),[48] in the peripheral blood and poor therapeutic response to antihistamines, poor response or partial response to omalizumab, in addition to a good therapeutic response to cyclosporine.[47] In mechanism IIb, the presence of IgG (subtypes IgG1 and IgG3) was demonstrated in 24% of the patients evaluated, and more than

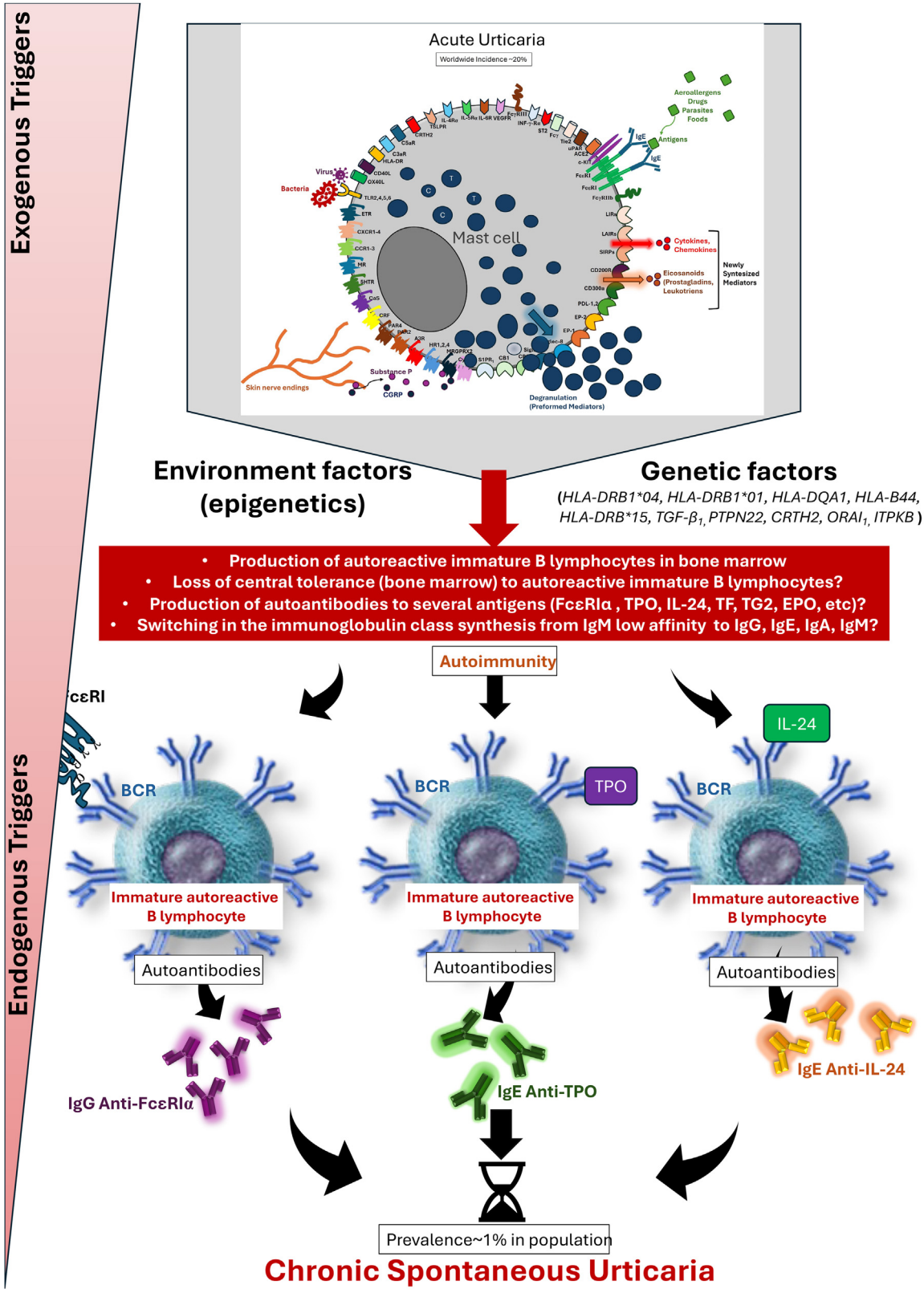

Figure 2 Main epigenetic and genetic mechanisms involved in acute urticaria in its evolution to chronic spontaneous urticaria.

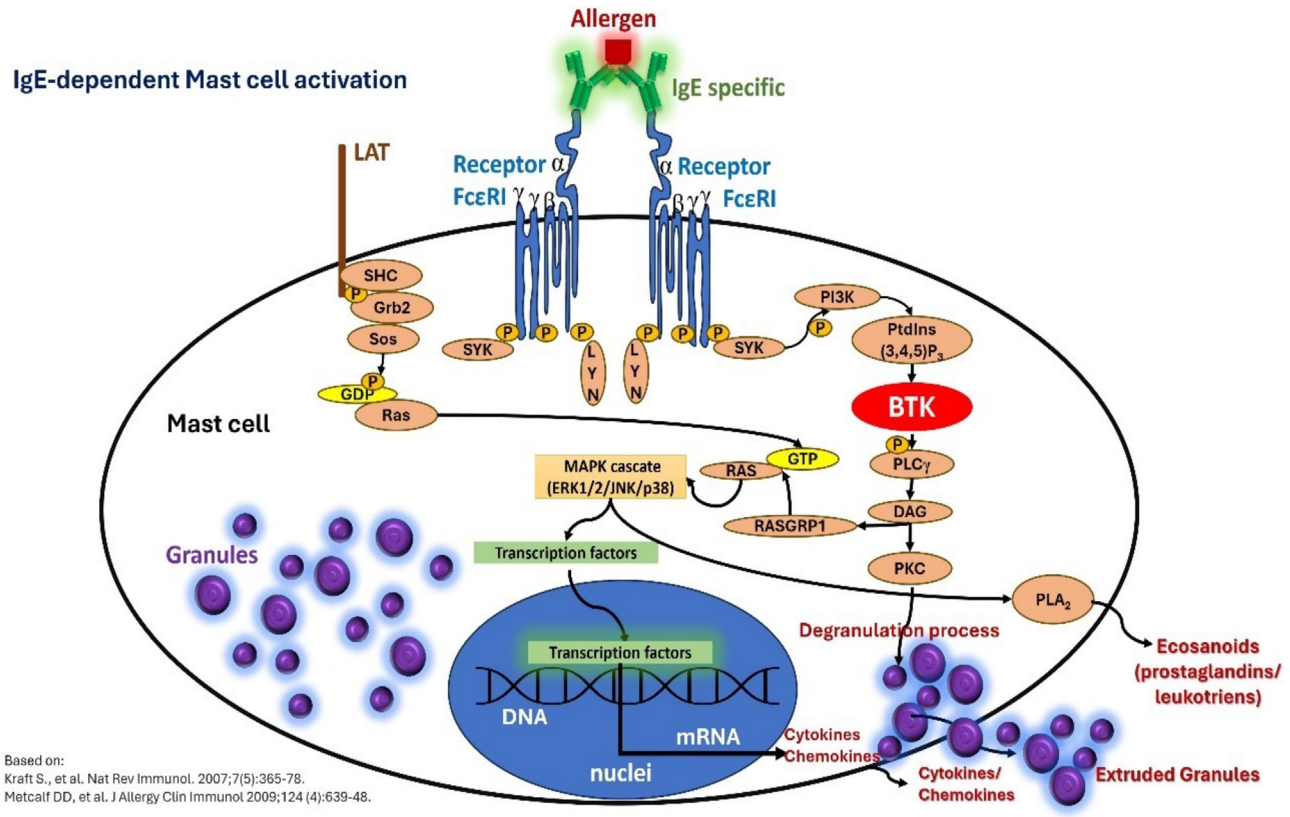

Figure 3 Mast cell activation and degranulation to external antigens in IgE-mediated reactions outside the context of chronic spontaneous urticaria: IgE specific to a given allergen, binding to contiguous FcεRI receptors on the mast cell membrane, and intracellular signaling events mediated by Bruton's tyrosine kinase (BTK). The phenomenon culminates in mast cell degranulation and synthesis of newly formed mediators.

half of the patients had IgM (60%) or IgA (5%) against the FcεRI receptor (most common), when these antibodies were tested by the ELISA method and against IgE.[42,49] In clinical practice, it is recommended to evaluate the relationship between serum levels of anti-thyroid peroxidase IgG/total serum IgE, which in these patients can result in values above 15, as an assessment of the existence of aiUCE (type IIb), since serum levels of total IgE <40 IU/mL are frequently observed.[50]

In fact, many patients with CSU show the coexistence of auto-IgE and IgG autoantibodies (coexistence of type I and type IIb mechanisms), which indicates an overlap between these two endotypes.[43,51] In Brazil, the authors observe 38% of patients with type I mechanism endotypes, 51% with concomitant type I and IIb mechanism endotypes, 9% with IIb endotypes, and 2% of patients who did not meet criteria for any endotype.[51] Thus, overlapping autoreactivity mechanisms in CSU types I and IIb, with IgG and IgE anti-TPO, can coexist in the same patient. However, patients with aiUCE with or without coexisting aaUCE are generally women, with higher levels of antiperoxidase autoantibodies (both IgG and IgE anti-TPO), and demonstrate a greater negative impact on quality of life, while patients with aaUCE without association with aiUCE are younger individuals.[36,52] However, considering different studies, less than 35% of patients with CSU will not have any autoantibodies (non-autoimmune endotype).[51,52]

In addition to autoantibodies, another factor involved in the amplification of mast cell degranulation is the activation of the complement system through the alternative pathway. This is particularly relevant in the mechanism of type IIb CSU, where after activation of FcεRI on the mast cell membrane by IgG-anti-FcεRI, C5a (anaphylatoxin) is generated and this acts as a ligand for the C5aR receptor expressed only on cutaneous mast cells, and exacerbates mast cell degranulation, worsening and amplifying CSU, which makes the skin the target organ in CSU due to the unique expression of C5aR, sensitizing it to inflammatory and autoimmune processes.[36]

Understanding the pathogenesis of CSU has allowed us to clarify the action of therapeutic agents, such as the monoclonal antibody omalizumab, directed against human IgE, sequestering it and suppressing the expression of its membrane receptors (FcεRI) on mast cells and basophils, so that there is a decrease in the density of antigen to which the anti-FcεRI IgG is directed, with a consequent decrease in the signaling of mast cell and basophil degranulation.[53] Consequently, cross-linking between two contiguous FcεRI receptors on the cell membrane, a necessary step for degranulation, is reduced.[53] Furthermore, as complement activation via the alternative pathway, which is caused by the aggregation of IgG1 and IgG3 to the FcεRI antigen, responsible for complement activation, with the use of omalizumab, the expression of FcεRI on the cell membrane

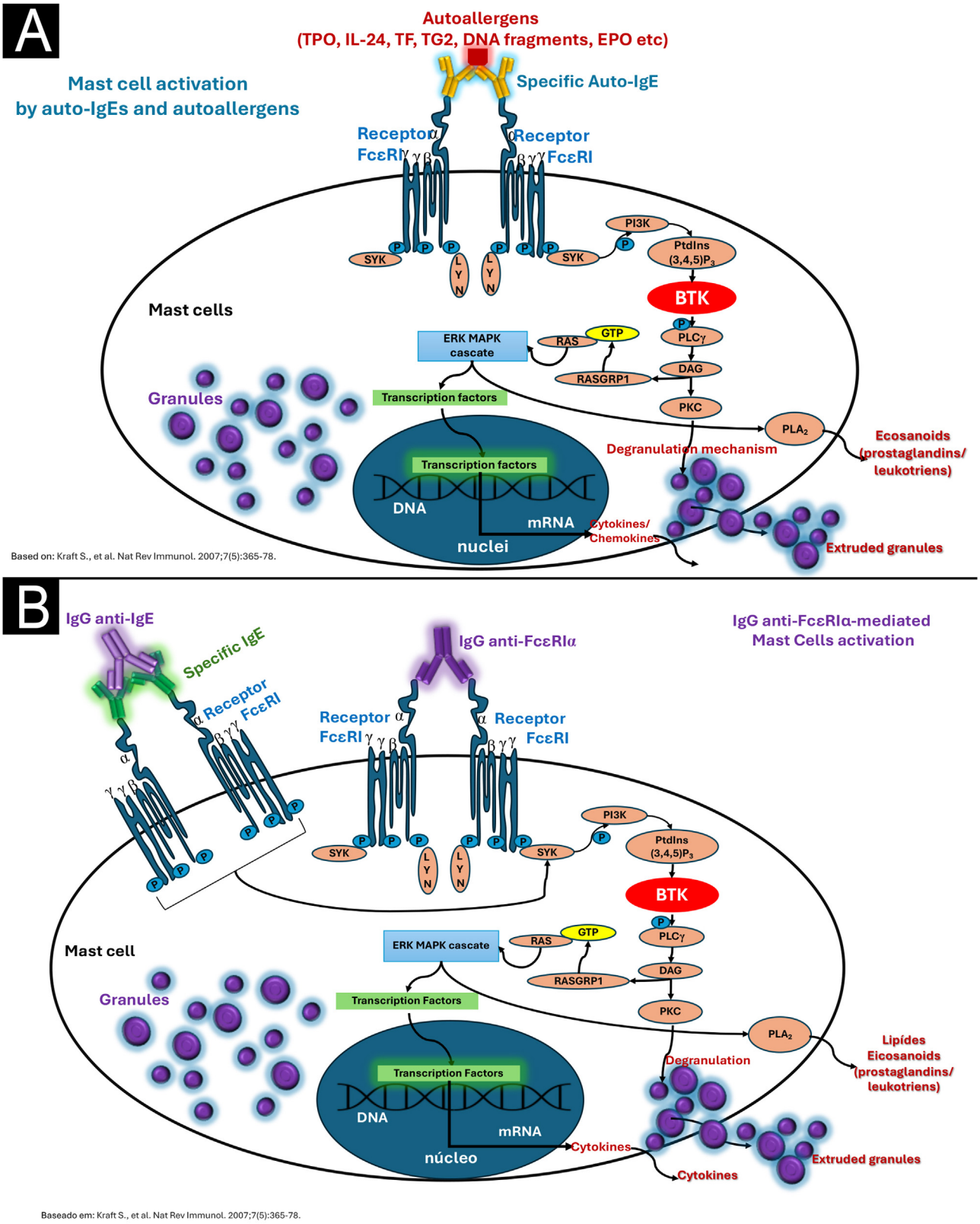

Figure 4 (A) Type I autoimmunity mechanism (autoallergy), with the participation of IgE alloantibodies against circulating autoantigens. (B) Mechanism IIb (autoimmunity) mediated by the presence of IgG autoantibodies, possibly IgM and IgA, against the alpha subunit of the high-affinity IgE receptor (FcεRIα) on mast cells and basophils, or against the patient's own IgE, either circulating or bound to FcεRI receptors. In both mechanisms, mast cell degranulation and synthesis of newly formed mediators occur through the activation of specific intracellular and nuclear signaling pathways, which share the activation of Bruton's tyrosine kinase (BTK).

of mast cells was reduced. This reduces the interaction between IgG-anti-FcεRI and the receptor antigen, consequently decreasing the generation of C5a and its binding to the receptors C5aR on the membrane of cutaneous mast cells, silencing the signals that potentiate the activation of these cells, CSU protagonists.[53]

In addition to the FcεRI receptor, mast cells can be activated by other activating receptors on their surface, including the Mas-related G protein-coupled receptor X2 (MRGPRX2), the C5Ra receptor, protease activated receptors (PAR1 and PAR2, which have trypsin, tryptase, thrombin, and the FVIIa/FXa/TF complex as ligands), a molecule homologous to chemoattraction receptors expressed on Th2 cells (CRTh2), and cytokine receptors (ST2, for IL-33; IL-4Rα receptor for IL-4, among others such as IL-5, IL-6, IL-15, IL-25, thymic stromal lymphopoietin [TSLP], and TNF-α), and the c-Kit receptor.[36]

The diversity of mast cell receptors (FcεRI, MRGPRX2, PAR1 and PAR2, CRTh2, c-Kit [CD117], and receptors for various cytokines and histamine H1 and H4) makes this cell capable of being subjected to a stimulus that influences an underlying response (priming).[11] Activation of FcεRI involves several intracytoplasmic signaling proteins, such as LYN, splenic tyrosine kinase (SYK), and Bruton's tyrosine kinase (BTK), which promote subsequent phosphorylation signals in other proteins and induce mast cell activation and degranulation.[11] Thus, the first step of FcεRI-mediated signaling is the phosphorylation of the FcεRI beta chain (FcεRIβ-chain) and gamma chain (FcεRIγ-chain) by the LYN protein, followed by the activation of SYK and BTK.[11] Thus, cytosolic BTK is the central positive regulator of mast cell activation and cytokine production in FcεRI-mediated stimuli.[11] In addition to its role in mast cell activation, BTK is required for the B Cell Receptor (BCR) signaling pathway and subsequent antibody synthesis.[11]

In addition to the membrane receptors that activate mast cells, these cells have receptors that inhibit their function, such as CD200R, CD300a, FcγRIIb, and sialic acid-binding immunoglobulin-like lectin 8 (Siglec 8), which can block their activation and interaction with other ligands.[11]

Of growing interest is the MRGPRX2 receptor, a G-protein-coupled receptor with seven transmembrane domains, highly expressed in mast cells of patients with CSU and overregulated in severe forms of the disease, participating in degranulation mechanisms called pseudoallergic/neurogenic.[36] Its activation occurs by several mediators, including compound 48/80, eosinophil-derived mediators (major basic protein, MBP, and EPO), neuropeptides (such as substance P, vasoactive intestinal peptide, VIP), innate host defense peptides (catechecidin), small molecule drugs (nicotine antagonists and neuromuscular blocking drugs), opioids, antibiotics (vancomycin, ciprofloxacin, levofloxacin, and moxifloxacin), and iodinated contrast media, all of which are involved in the development and exacerbation of CSU. After activation of MRGPRX2, there is an increase in calcium in the CM cytosol, mediating Ca2+ channels, Gai, Gaq, extracellular signal regulated by kinase, PI3K/AKT, and phosphoinositide phospholipase Cγ with subsequent degranulation and further cytokine release.[36] Communication between eosinophils and mast cells, independent of IgE-related mechanisms, can occur in CSU due to MBP and EPO binding to MRGPRX2 receptors, contributing to the maintenance of CSU lesions.[36]

Cutaneous mast cells chronically exposed to IL-33 (alarmin) have their FcεRI-mediated degranulation attenuated; however, IL-33 can sensitize them to greater acute reactivity to MRGPRX2 receptor ligands.[36] IL-33's half-life is reduced by the action of proteases and histamine released during degranulation, which constitutes a negative feedback loop, controlling its actions.[36]

Inflammation and coagulation in CSU

Some patients with CSU demonstrate features of chronic inflammation, including increased mast cell numbers, increased eosinophils, basophils, and other cell elements infiltrating the dermis, increased cytokine expression, neovascularization, and increased expression of vascular adhesion molecules.[10] However, several other cell types also participate in the pathogenesis, which can be inferred from resistance to several mast cell-targeted medications.[42] The higher number of mast cells in the skin of patients with CSU is associated with more active urticaria, so that patients with active CSU also have a higher number of mast cells in the skin, compared to patients with CSU in remission and healthy controls.[54]

Histopathologically, more than 90% of patients with CSU have a non-necrotizing perivascular cell infiltrate with no evidence of immunoglobulin or complement deposition, with a prominent increase in mononuclear cells accompanied by a ninefold increase in the number of mast cells with signs of degranulation. The authors speculated that CSU would be an ''allergic reaction'' -type of disease, even without an identifiable antigen. Furthermore, the infiltration of mononuclear cells and eosinophils in the perivascular environment of the dermis would suggest a molecular immunopathology in CSU similar to late-phase allergic reactions.[55] Also in this study, the authors identified that the perivascular infiltrate in hives consisted of 47% T lymphocytes and 22% monocytes.[55]

There are different cytokines, cell adhesion molecules, chemokines and enzymes increased in the blood of patients with CU (CSU, symptomatic dermographism, cold urticaria, heat urticaria, cholinergic and delayed pressure urticaria), compared to healthy controls, such as: TGF-β1, IL-2, IL-4, IL-5, IL-6, IL-10, IL12p70, IL-13, IL-17, IL-18, IL-18 BP, IL-21, IL-23, IL-31, INF-γ, TNF-α, TNF-β, CCL5/RANTES, sICAM-1, sVCAM-1 and Transglutaminase-2 (TG2) activity).[54]

Serum levels of IL-33 and TSLP were evaluated in 50 patients with CSU and 38 healthy controls. Elevated serum levels of these alarmins were observed in the patients, including a correlation between IL-33 levels and UAS7 and DLQI scores, concluding that IL-33 may be a diagnostic and prognostic biomarker in CSU.[56,57]

In addition to the increased number of mast cells (CCL3+) in the hives of patients with CSU, a perivascular infiltrate of CD4+/CCR5+ lymphocytes, monocytes, neutrophils, eosinophils, basophils, and macrophages (mostly of the M2 phenotype) was observed, contributing to amplifying the inflammatory state of the disease.[21,36,42,54,55,58] In this context, cytokines detected in the skin with hives (lesional skin)

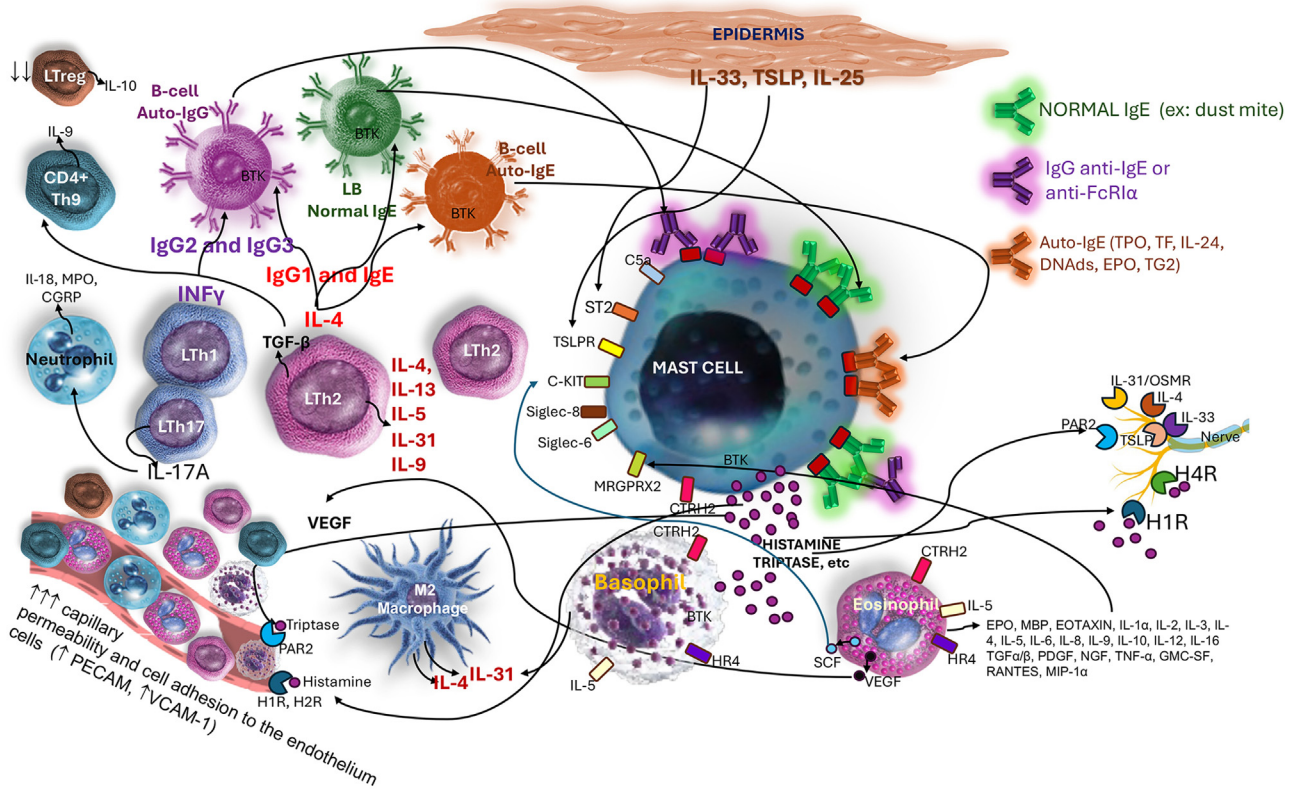

Figure 5 Main inflammatory interactions between mast cells and different cell elements in chronic spontaneous urticaria.

indicate response patterns. Inflammatory Immune System type 1 (INFγ) and type 2 (IL-4, IL-5); type 2 inflammation is maintained by the production of alarmins (IL-25, IL-33, TSLP), which are mediators of the innate immune system, especially involved in allergic responses.[36,56]

Originally, the presence of autoreactive CD4+ T cells in the blood of patients with CSU, specifically targeting the FcεRiα antigen, generated the first evidence of the sequence of autoimmune events in CSU, as in other autoimmune diseases: its onset is related to the activation of autoreactive T cells, stimulated by INFγ (type 1 inflammatory reaction, with initial participation of Th1 CD4+ T cells). Autoreactive T cells (in response to INFγ) are detected earlier than autoantibodies in CSU patients, suggesting that both are present at distinct stages of the CSU course.[59,60] In parallel, the IL-23/IL-17 and TNF-α axis may contribute to the maintenance of inflammation in CSU.[36]

There is an increase in Th17 cells and IL-17A expression in both CD4+ T cells and mast cells in the skin of patients with severe CSU, in hives, and in apparently normal skin, where these cells are arranged in close proximity, supporting the involvement of T cells in the pathogenesis of CSU.[60] This observation led to the hypothesis that pro-inflammatory cytokines such as IL-17 and microparticles derived from T lymphocytes can induce mast cell degranulation, in a transient and short-lived manner, which can resolve spontaneously. Once activated, CD4+ cells and mast cells are placed close to each other, and a new exacerbation of urticaria occurs, which is one of the explanations for the episodic/transient nature of the appearance of erythema and hives in CSU.[60]

Thus, the cells that infiltrate the skin in CSU migrate from the blood to the cutaneous compartment in response to different chemotactic factors, for example eotaxin, MCP3, RANTES, IL-5, C3a, C5a, TNF, IL-17 and Platelet Activating Factor (PAF), released by mast cells, activated endothelial cells (by histamine and TNF-α, initially, and also by thrombin, IL-25, IL-33, VEGF), LTh2, dermal fibroblasts and other cells.[11] Cell adhesion molecules, such as P-selectin, E-selectin, ICAM, VCAM and PECAM, are highly expressed in the hives (lesional skin) of patients with CSU due to the action of histamine, tryptase, and other factors.[11] This explains why 10% to 15% of patients with CSU present with eosinopenia and basopenia in their peripheral blood, which occurs due to the migration of these cells from the blood to the skin. This is associated with CSU activity, the presence of autoantibodies, and a poor therapeutic response to antihistamines and omalizumab.[11]

In the early stages of hives formation, 30 minutes after injection of autologous serum from CSU patients, neutrophils and eosinophils are observed in the perivascular area of the dermis (along with T lymphocytes). They increase in number within two hours and decrease around 48 hours (neutrophils) or later (eosinophils and lymphocytes).[11] Communication between mast cells and eosinophils is relevant in CSU, since both activate each other, with eosinophils releasing SCF, stimulating mast cells, and these producing IL-5, PAF, TNF and eotaxin (Fig. 5).[11]

Cutaneous activation of the coagulation cascade and complement

Eosinophils and endothelial cells of the dermal microvasculature can express tissue factor (TF) on their surfaces, resulting from various stimuli, such as histamine, VEGF, lipopolysaccharide (LPS), TNF, IL-6, IL-33, and IL-1β, promoting coagulation activation.[11]

Blood coagulation has two main pathways: extrinsic and intrinsic. In the pathogenesis of CSU, the extrinsic pathway triggered by TF is relevant in many patients. Elevated plasma levels of Prothrombin Fragment 1+2 (PF1+2), Fibrin/Fibrinogen Degradation Products (FDP), and D-dimers rose in the blood in proportion to the activity and severity of CSU symptoms.[61–64] When small amounts of FVIIa bind to TF on the surface of eosinophils and activated monocytes in the cellular infiltrate of hives and to activated endothelium in the dermal microvasculature, the extrinsic coagulation pathway is activated in the transudate plasma, along with Phosphatidylserine (PS) and Ca2+, and subsequently activates factor Xa, which converts prothrombin (FII) to FIIa (thrombin), which generates fibrin (Fia) from fibrinogen (FI) and, as a waste product, PF1+2.[65] Plasmin from the fibrinolytic pathway of coagulation then degrades fibrin into PDF and D-dimers.[65] Fibrin can stimulate Toll-Like Receptor 4 (TRL4), including on mast cells.[65]

Although activation of the coagulation cascade occurs in CSU, it is notable that it occurs as a local process, with active fibrinolysis and no risk of thromboembolic events.[65,66] TF expression in CSU hives is thus due to activated eosinophils expressing TF on their cell membranes and due to TF expressed by dermal endothelial cells in response to the synergy of two classes of its inducers, Group 1 (LPS, TNF-α, IL-33, IL-1β, which activate the nuclear factor kappa B-related signaling pathway, NF-κB) and Group 2 (histamine and VEGF, which activate the intracellular pathway linked to phospholipase C).[65] TF expression in endothelial cells can be suppressed by adenosine (a metabolite of ATP).[65]

As subsequent events, there is both activation of PAR1,2,3,4 receptors by activated factors of the extrinsic coagulation pathway [FVIIa activates PAR_2, FXa activates $PAR_{1,2,3}$ and prothrombin (IIa or FIIa) activates $PAR_{1,3,4}$] which act on different target cells such as mast cells (where PAR_2 is intensely expressed in urticaria lesions), stimulating the production and release of inflammatory mediators, mitogenesis and in the vascular endothelium promoting capillary hyperpermeability, proliferation, chemotaxis and cell differentiation.[65] Activated coagulation factors of the extrinsic pathway (FXa, FIIa and plasmin) also act by triggering the alternative complement pathway, converting C3 into the C3b+C3a complex, which, acting on C5, generates C5a and C5b, which act as anaphylatoxins, with C3a and C5a binding to their receptors (C3aR and C5aR) on mast cells and basophils and amplifying the stimulation of these cells.[65]

Intestinal microbiota and chronic urticaria

CSU occurs with intestinal dysbiosis, and its relevance in the pathogenesis of the disease has been highlighted, presumably by promoting signals that reduce the activation threshold of mast cells (such as IL-33 and bacterial lipopolysaccharides (LPS)) or stimulate inhibitory signals (short-chain fatty acids (SCFAs) such as butyrate and propionate) in these cells.[67]

LPS influence the activation thresholds of mast cells or promote their priming and are produced by the intestinal microbiota.[67] SCFAs promote epithelial barrier integrity and function by stabilizing Hypoxia-Inducible Factor (HIF), stimulating the expression of tight junction molecules [occludin-1, Mucin 2 (MUC-2), and Zonula Occludens-1 (ZO-1)], and producing antimicrobial peptides. This protects enterocytes and prevents LPS from reaching the bloodstream, which can reach the skin and bind to TLR4 on mast cells, activating them and producing inflammatory mediators such as TNF-α and IL-13.[67] SCFAs act by stimulating IL-10, which has anti-inflammatory properties, and inhibiting mast cell activation after stimulation by IgE, and also without IgE participation via epigenetic regulation.[67]

SCFAs are responsible, in part, for promoting intestinal homeostasis and its immune balance, being produced and released by Firmicutes, including *Clostridium leptum* and *Roseburia* spp., which regulate the growth and virulence of enteric pathogens, such as *Escherichia coli* and *Klebsiella*, LPS producers.[67] SCFAs such as butyrate and propionate can facilitate the differentiation of regulatory T lymphocytes (Tregs), which control Th2 (CD4+) LT cells and their cytokines, including IL-4 and IL-13, which contribute to the pathogenesis of CSU. Increased LPS uptake and reduced SCFAs contribute to abnormal differentiation of naive T cells, increasing their differentiation into Th2 and Th17 T cells, and decreasing the number of Th1 and Treg cells.[68]

High-fiber diets increase blood levels of propionic acid, blocking allergic inflammation via G-protein-coupled receptors (GPCR41), while butyrate and propionate inhibit IgE-dependent and non-dependent mast cell activation.[67] On the other hand, the *Enterobacteriaceae* family (genera *Megamonas*, *Dialister*, and *Megasphaera*) recovered from patients with CU is one of the pro-inflammatory members of the intestinal microbiota of these patients, with a reduction in bacteria from the *Firmicutes* and *Bacteriodetes* strains that constitute 90% of the beneficial bacteria in the intestine being observed.[68] Thus, intestinal dysbiosis is linked to CSU, as well as to other skin diseases such as psoriasis, atopic dermatitis, and acne.

Adult patients with CSU in endemic areas have more protozoa, showing a higher risk of seropositivity for toxocariasis and sensitization to *Anisakis simplex*, both *Ascarididae* helminths, compared to healthy controls. In children with CSU, infection by *Blastocystis hominis* is important.[68] In addition to helminths, protozoa such as *Blastocystis hominis* and *Giardia lamblia* have the ability to produce high levels of specific IgE antibodies against host antigens, which can result in degranulation of mast cells in the human host.[68] Furthermore, helminths disrupt the body's protective barriers, fostering a Th2 immune response and tissue repair, inhibiting Th1 differentiation, and encouraging the development of more Th2 cells. B cells support Th1 responses by producing IgG1 and IgG3, which can form immune complexes (CICs) with parasite antigens, activating anaphylatoxins (C3a and C5a) that act on mast cells, contributing to urticaria. These data demonstrate that the composition and alter-

Table 4 Biomarkers related to increased activity/severity of chronic spontaneous urticaria (CSU).[74–77]

Clinical aspects	Hematological and/or serological aspects
• Older age at disease onset • Female sex • Presence of angioedema • Poor response to antihistamines • Positive autologous serum test • Hypersensitivity to nonsteroidal anti-inflammatory drugs (NSAIDs) • Long-lasting CSU	• Low eosinophil count (<0.05 × 109/L) • Low basophil count (<0.01 × 109/L) • Low serum vitamin D levels • Elevated CD2023c expression on basophils • Elevated eotaxin levels • Elevated VEGF levels • Elevated MMP-9 levels • Elevated IL-6 levels • Elevated IL-18 levels • Elevated IL-33 levels • Elevated C-reactive protein (CRP) • Elevated D-dimers (in half of patients with severe disease) • Elevated antithyroid antibodies (anti-TPO ≥ 34 kU/L) • Elevated mean platelet volume • Elevated erythrocyte sedimentation rate (ESR) • Positive basophil activation test (BAT) • Elevated serum adenosine levels • Elevated transglutaminase 2 activity

ations of the intestinal microbiome and parasites can have significant impacts on the pathogenesis of CSU.

Pathogenesis of pruritus

Pruritus is the cardinal symptom of CSU. Although signs of excoriation are uncommon among patients with the disease, the pleasure of scratching the skin is extremely high among them, and much greater when compared to other pruritic dermatological diseases.[69]

Histamine released during mast cell degranulation and by basophils plays a prominent role in the pathogenesis of urticaria and its pruritus.[70] Sensory nerve endings in the dermis have histaminergic pathways (H1 and H4 receptors), to which histamine binds and determines the perception of pruritus. However, with chronic disease, the Th2 immune pathway, supported by increased cytokines IL-4 and IL-5, activates mast cells, reducing their threshold for degranulation through the production of IgE and its binding to the FcεRI receptor.[70] Furthermore, both IL-31 and IL-33 are type 2 inflammatory cytokines and are crucial in the formation of hives and the induction of pruritus, since they bind to receptors in the non-histaminergic sensory pathways of the cutaneous nerves.[70] Finally, proteases such as tryptase act on pruritogenic receptors in cutaneous sensory fibers (PAR1 and PAR2), serotonin (5-HT), in addition to the cytokines IL4, IL-13, and TSLP released by activated mast cells in CSU. Circulating basophils in the peripheral blood of patients with CSU synthesize IL-31 in response to IgE-dependent stimuli, as well as to IL-31 stimulation itself, which, in an autocrine manner, feeds back the release of IL-4 and IL-13.[70] These cytokines also have receptors on sensory neural terminals in the non-histaminergic pathways. Therefore, pruritus in CSU is not solely histaminergic, as demonstrated by the ineffectiveness of second-generation H1 antihistamines in controlling it even at quadruple doses in a significant portion of patients, since the non-histaminergic pathway of pruritus is significantly important.[71]

Biomarkers of Disease Activity and Therapeutic Response

Biomarkers, or ''biological markers,'' are objective and quantifiable characteristics of biological processes that refer to a broad subcategory of medical signs. These are objective indications of a medical condition, or a biological process, pathogenesis, or pharmacological response to a given therapeutic intervention, observed in patients. These findings can be accurately measured and are reproducible.[72]

Regarding CSU, there are no biomarkers related to diagnosis, except for clinical definition criteria.[73,74] Biomarkers in CSU can be divided into: (i) Clinical and serological biomarkers related to disease activity/clinical severity; (ii) Clinical and serological biomarkers of response to treatment. Such markers in CSU continue to be studied by several researchers, particularly cytokines/chemokines and substances expressed in the blood of patients[74,75] (Table 4).

Regarding the therapeutic response, there are different markers that express a better or worse response[73] to the main therapeutic agents proposed in the CSU treatment scale, by the International Consensus on Urticaria in 2022[74]: (i) Antihistamines [poor therapeutic response in patients with elevated UAS7 and concomitant CSU with induced CU, positivity of ASST and/or BAT (Basophil Activation Test), elevated CRP and/or ESR, and/or elevated serum D-dimer levels]; (ii) Omalizumab (late or poor response in the presence of signs of autoimmunity, such as positivity on ASST and BAT or ANA; adequate response in the absence of basophil-

activating IgG autoantibodies, high expression of FcεRI on basophils, and elevated serum total IgE levels; markers of omalizumab effectiveness are represented by increased basophil counts during treatment, decreased D-dimer and C-reactive protein levels, and reduced serum IL-31 levels); (iii) Cyclosporine: good response to treatment in the presence of signs of autoimmunity, such as positivity on BAT and/or ASST associated with low serum total IgE levels (<30–43 IU/mL)[76]; elevated d-dimer values correlate with a poor response to cyclosporine).[73]

Stress and urticaria

CSU has a significant negative impact on quality of life (QoL), with approximately 40% of patients having a DLQI > 10 (severe or very severe impairment in QoL), resulting in considerable expenditures for the healthcare system (US$907 to US$2,084 annually per patient, especially due to the monetary costs of treatment).[76,77] In addition to the symptom burden that CU imposes on the patient and society, causing disturbances in sleep quality and productivity at work and school, the disease and its unpredictable course increase healthcare expenses for medications, outpatient and emergency room visits, hospitalizations, and laboratory tests, which are consequently associated with emotional imbalance, including mental conditions such as anxiety, depression, and stress, which can contribute to the persistence of the disease.[77,78]

Any physical (e.g., illness, trauma, dehydration) or psychological (e.g., intense emotional stress) stimulus that imbalances homeostasis results in a systemic stress response.[77] The brain is a receptor for stress stimuli and promoter of stress responses, transmitting stimuli to the periphery, such as the skin, through different mediators, either through a rapid and transient response mediated by the Sympathetic-Adrenomedullary (SAM) system or through a slow and transient/persistent response mediated by the Hypothalamic-Pituitary-Adrenal (HPA) axis.[77]

The acute stress response affects the immune system by increasing the secretion of IL-6, TNF-α, and IL-1β, mobilizing neutrophils through skeletal-muscle-derived neutrophil-attracting chemokines (CXCL-1) out of the bone marrow and temporarily directing these cells, lymphocytes, and monocytes from peripheral organs to the bone marrow through CXCR-4.[77]

Chronic stress can cause changes in innate and adaptive immunity through the actions of neuroendocrine mediators of the SAM and HPA axes.[77] Stress causes the release of corticotropin-releasing hormone (CRH) by the hypothalamus, which activates the secretion of adrenocorticotropin (ACTH) by the anterior pituitary gland, which stimulates the adrenal cortex to release corticosteroids.[77] As a negative feedback, elevated serum cortisol inhibits the secretion of CRH and ACTH.[77] Chronic stress increases Th2 cell responses and reduces NK cell activity, also causing dysregulation of the HPA axis, leading to hypocortisolism and sustained hyperactivity of the sympathetic nervous system.[77] Hypocortisolism is significantly associated with elevated levels of high-sensitivity CRP and IL-18, demonstrating the contribution of a vicious cycle of inflammation and hypocortisolism to the pathogenesis of CU.[77]

Furthermore, psychological stress can trigger the release of substance P by nerve endings in the skin, which activates the MRGPRX2 receptors on the mast cell membrane or Neurokinin-1 Receptors (NK1R), and together with the neural release of CGRP, constitute the link between stress and neurogenic inflammation, causing a bidirectional communication between mast cells and peripheral sensory neural endings. This is facilitated by the anatomical location of mast cells abundantly close to nerve endings, blood and lymphatic vessels, in the microvascular unit of the dermis, allowing a rapid response to environmental changes and participation in cutaneous inflammation.[77] The increased expression of Corticotropin-releasing Hormone Receptor 1 (CRH-R1) in CU lesions also suggests a close connection between the skin and the HPA axis.

Some studies indicate that stressful events (loss of family members, financial difficulties, family conflicts, and work-related issues) precede CU exacerbations in a significant proportion of patients.[77,78] However, in light of current knowledge, it is important to exercise caution when interpreting the relationship between psychological stress and CSU.[76,77]

Comorbidities

CSU determines different areas of comorbidities, including sleep disorders (36.7%), depression (48.1%), anxiety (30.6%), mood disorders (29.4%), suicidal ideation (18.8%), and other psychiatric disorders (in 33% of patients), associated autoimmune diseases, atopic diseases, cardiovascular disorders, and, less frequently, an association with malignancies.[79] Overall, approximately 30% of patients with CSU have at least one autoimmune disorder, while 2% may have one or more autoimmune diseases, with Hashimoto's thyroiditis and vitiligo constituting the most common coexisting diseases.[79] Thyroid disease occurs in approximately 50% of patients with CSU, with a 5–7-fold increased risk of positive anti-TPO antibodies compared to controls. Other autoimmune diseases have a higher prevalence, depending on the population studied: pernicious anemia (>5%), vitiligo (>3%), insulin-dependent diabetes mellitus, rheumatoid arthritis, and celiac disease (>1% of patients, respectively).[79] Approximately 80% of patients with CSU develop some autoimmune disease within ten years of their CSU diagnosis.[77]

Among children (<12 years) with CSU, ASST positivity, thyroid biological abnormalities, and the presence of antinuclear antibodies (ANA) were observed in 36.8%, 10.4%, and 6.4%, respectively, in addition to low serum vitamin D levels (69.1%) and psychiatric disorders (70.4%).[80]

Among adults with CSU, atopic comorbidities have been observed, including asthma (19.6%), allergic rhinitis (16.5%), atopic dermatitis (6.3%), and food allergy (8.2%), in data from the Scandinavian arm of the AWARE study.[81] This pattern is similar to that observed in children with CSU, where atopic comorbidities were highly prevalent: atopic dermatitis (17.2%), allergic rhinitis (16%), asthma (13.2%), and food allergy (3.2%).[82]

Regarding malignancies, CU was associated with cancer in 0.007% of the population. It is resistant to H1 antihistamines, disappears after chemotherapy or tumor removal, can recur in tumor recurrence, and presents two to eight

months before the diagnosis of malignancy.[79] The most common malignancies are internal carcinomas (24% of which are papillary thyroid carcinomas), hematological malignancies, including non-Hodgkin's lymphoma, and stomach and liver cancer. However, it should be noted that although these cases are reported in the literature associated with CSU, the overall rates of cancer among patients with the disease are relatively low, so the international urticaria guidelines do not recommend screening for malignancies as a potential cause of the disease.[74,79]

With the inflammatory skin condition and in persistent cases of CSU, an association is observed with metabolic syndrome, increased abdominal circumference, hyperlipidemia, hypertension, and cardiovascular disease.[79] These conditions may be related to chronic inflammation and elevated TNF-α levels in these patients with CSU.[79]

Urticaria and urticarial manifestations

CSU should be primarily differentiated from induced forms of chronic urticaria, such as pressure urticaria, symptomatic dermographism, cholinergic, solar, aquagenic, vibratory, and cold urticaria. These urticarias arise after exposure to an identifiable, usually external, triggering factor, unlike CSU; however, CSU can coexist with induced CU in approximately 30%–40% of patients, who may have more than one induced CU associated with CSU.[83]

Patients are advised to photograph their lesions approximately 48 hours before their appointment, as this can aid in visualizing the lesions and provide information about clinical characteristics, such as topography, shape, and size. This may indicate certain induced CU, persistent lesions, or residual brownish or purpuric hyperchromic lesions that suggest differential diagnoses such as urticarial vasculitis (UV).[84]

UV is the main differential diagnosis for CSU, and CSU and normocomplementemic UV can coexist in rare cases. UV should be suspected if at least one of the following characteristics occurs: hives lasting more than 24 hours in the same location, post-inflammatory purpura/hyperpigmentation, vesicles/blisters, residual desquamation, and associated systemic symptoms (arthralgia, fever, lymphadenopathy, etc.).[85] On histopathology, the presence of leukocytoclasia and fibrin deposits constitutes the minimum criteria for the diagnosis of UV, and the presence of red blood cell extravasation is not exclusive.[85] There is still debate as to whether CSU and normocomplementemic UV may constitute part of the same disease spectrum.[85]

Skin biopsy of the lesion is indicated in all cases where urticaria or angioedema are not characteristic, with typical symptoms and signs of urticaria/angioedema observed in CSU.[74,86]

Situations have been proposed where skin biopsy is indicated in unusual situations in patients with CSU: absence of pruritus, presence of pain or burning prevailing over the pruritus symptom, presence of general symptoms (fever, arthralgia, lymphadenopathy, hepatomegaly, or splenomegaly), presence of a violaceous halo, purpura or residual hyperpigmentation, or laboratory findings with substantially elevated erythrocyte sedimentation rate and C-reactive protein values, alterations in protein electrophoresis (monoclonal gammopathy, in particular), exaggerated elevation of ferritin, and consumption of complement factors (C3, C4, CH50; hypocomplementemia). The authors also propose that the lack of response to appropriate treatment as recommended by the international urticaria guidelines would also constitute a warning sign for a skin biopsy.[86,87]

An interesting semiotic resource for visualizing purpura in urticarial lesions is diascopy (with a glass slide or transparent plastic ruler), where compression fades the erythema of vasodilation and allows petechiae to persist, and dermoscopy, as demonstrated by Suh et al.,[88] which can reveal linear vessels more commonly in CSU (86%), while the incidence of red-purplish dots or globules (90%) was more evident in the early stages of UV.

Other differential diagnoses for CSU include drug reactions, atypical bullous pemphigoid (urticarial), urticarial dermatitis, neutrophilic urticarial dermatosis (NUD/NUSI), autoinflammatory diseases with monogenic urticarial lesions, Schnitzler syndrome, and Adult-Onset Still's Disease (AOSD) (Table 5).[86,87]

Therapeutic Basis and Perspectives

The goal of CSU treatment is to achieve complete disease control, with the absence of symptoms and signs of the disease, as reflected by the application and collection of PROMs (Patient Report Outcome Measure: UCT, Urticaria Control Test, in a four-question format, and the seven-day Urticaria Activity Score, UAS7), with the goal of achieving a UCT = 16 and UAS7 = 0 in patients, in addition to a DLQI equal to zero, if possible. The achievement of these less subjective parameters demonstrates that the therapeutic intervention restored normality to the patient's life, aiming to interrupt the natural course of the disease, treating it until it disappears definitively.[74,77]

In this therapeutic journey, various factors can trigger CSU exacerbations throughout treatment, even with completely asymptomatic periods, such as those reported in the Chronic Urticaria Registry (CURE)[89]: stress (13.9%), exposure to NSAIDs (6.7%), infections (5.5%; especially viral infections of the upper respiratory tract, including COVID-19 and its vaccines),[90–92] and, rarely, foods such as milk, fish, seafood, nuts, peanuts, spices, fruits, chocolate, and alcohol.[77,89]

The current international guidelines on urticaria provide a systemic treatment algorithm for CSU, which includes the use of daily second-generation antihistamines (anti-H1sg); Omalizumab (a humanized monoclonal anti-IgE IgG antibody) is prescribed monthly, and cyclosporine is prescribed daily, sometimes for long periods of years.[74,77]

Old medications used to treat CSU before the advent of omalizumab, such as colchicine, dapsone, methotrexate, montelukast, hydroxychloroquine, H2-blocking antihistamines, and doxepin, have little scientific evidence due to the lack of randomized, double-blind, placebo-controlled studies with relevant case studies. Therefore, they are not included in the recommendations of the 2022 international urticaria guideline.[74] However, in patients who do not respond to the measures recommended in the consensus, these medications can be used exceptionally.[93]

At least 25% to 50% of patients with CSU, even using quadruple doses of H1sg antihistamines, continue to have

Table 5 Characteristics of chronic spontaneous urticaria and its main differential diagnoses.

	CSU	AIS	Schnitzler	NUD/NUSI	UV	UD	Drug	AIBD	Wells	AOSD
Laboratory alterations	None relevant	Elevated CRP, ESR, leukocytosis, neutrophilia, lymphopenia in some cases, elevated serum protein amyloid	Leukocytosis, neutrophilia, elevated CRP/ESR, IgM or IgA monoclonal gammopathy. Normal or elevated serum complement	Leukocytosis, neutrophilia, elevated CRP and ESR	May have complement consumption (↓C3 and/or ↓C4). In case of hypocomplementemia, it may present with cytopenias, ANA+, in addition to glomerulonephritis and COPD.	None relevant	Uncommon, possibly eosinophilia.	Eosinophilia, D-Dimer, and elevated total serum IgE in bullous pemphigoid. IgA antitransglutaminase antibodies in dermatitis herpetiformis.	Eosinophilia may occur.	Leukocytosis with neutrophilia, anemia, very high ferritin levels, elevated ceruloplasmin, elevated ESR and CRP during disease activity, as well as elevated AST and ALT and LDH, in addition to polyclonal gammopathy.
Systemic manifestations	Uncommon	Fever, arthralgias, arthritis, general malaise, visceromegaly	Arthralgia, osteosclerosis in the femur and tibia, then humerus, radius, ulna and fibula, lymphadenopathy, possibly visceromegaly	Fever, myalgia and fatigue, less frequently chest or abdominal pain.	In the hypocomplementemic form arthritis, uveitis, myalgias, serositis.	Usually absent or uncommon	Uncommon, except in serum sickness with urticarial manifestations, arthralgia, fever, and myalgia.	Uncommon	Rare.	Lymphadenopathy, sore throat, pretibial pain, visceromegaly, evening fever.
Angioedema	40–60% of patients	Very rare	Rare	Absent	May be present	Absent	Uncommon, except in serum sickness	Absent.	Rare.	Absent in general.
Residual hyperpigmentation/desquamation	No	It may occur eventually	Possible	Absent	May be present along with purpura	Fine, light desquamation may occur.	Rare.	It may occur	It may occur	It may occur

Table 5 (*Continued*)

	CSU	AIS	Schnitzler	NUD/NUSI	UV	UD	Drug	AIBD	Wells	AOSD
Associated symptoms	Intense pruritus	No or minimal pruritus. Burning sensation may occur.	Pruritus is almost absent, or absent.	Absent or minimal pruritus.	Burning sensation and pain prevail over pruritus.	Intense pruritus	Pruritus	Intense pruritus	Burning sensation and pruritus.	Minimal or absent pruritus.
Distribution of lesions	Bilateral and asymmetric, in any area	Bilateral, usually symmetrical, in the trunk and extremities.	Asymmetrical, especially trunk and limbs.	Asymmetrical, trunk and limbs in particular.	Asymmetrical and all skin.	Bilateral, somewhat symmetrical, especially in the trunk and proximal limbs.	Bilateral and symmetrical, possibly in large folds	Generally symmetrical, varying with the bullous autoimmune disease in question.	Trunk and limbs.	Face, trunk and limbs.
Types of lesions	Hives and/or angioedema.	Nearly flat hives to infiltrated plaque lesions.	Urticated plaques and nearly flat urticarial lesions.	Macular erythema and/or palpable rash that resolves without sequelae and may be urticarial in nature.	Urticarial lesions that persist for more than 24 hours in the same location. Purpura and hyperpigmentation may be observed.	Pink, erythematous hives, slightly elevated, some with signs of mild lichenification. Excoriations are common.	Urticarial lesions sometimes associated with eczematous eruptions.	Urticarial lesions, possibly vesicles and/or erosions.	Hives with an arcuate or annular appearance. Occasional edematous-vesicular, papular lesions, and infiltrated plaques.	Urticarial lesions, slightly raised and persistent linear lesions, resembling dermographism.
Duration of lesions	Minutes or up to 24 hours	12 hours or a few days	>24 hours in the same place.	<24 hours	Two days to weeks in the same place	>24 hours and sometimes several days in the same place.	>24 hours	Several days or weeks in the same places.	>24 hours and sometimes several days in the same place.	>24 hours.

Table 5 (*Continued*)

	CSU	AIS	Schnitzler	NUD/NUSI	UV	UD	Drug	AIBD	Wells	AOSD
Histopathology	Nonspecific. Edema with Perivascular infiltrate of lymphocytes and polymorphonuclear cells. No epidermal changes.	There may be neutrophilic perivascular infiltrate and neutrophilic epidermotropism	There may be neutrophilic perivascular infiltrate and neutrophilic epidermotropism (epidermis, hair follicles, and eccrine glands)	Neutrophilic infiltration in the interstitium, between the collagen fibers, sometimes with a ''single-file'' appearance; without leukocytoclasis or vasculitis. No edema, and neutrophilic epidermotropism may be present.	Angiocentric infiltrate with or without interstitial spread. Leukocytoclasis and transmural polymorphonuclear cell infiltrate. Fibrin deposits in the blood vessel, red blood cell extravasation, and foci of thrombosis.	Mild spongiosis, perivascular infiltrate of lymphocytes and eosinophils, which may be in the superficial and middle dermis, is often mistaken for a drug reaction	Variable, with spongiosis, parakeratosis, vacuolar degeneration of the basal layer in the epidermis, keratinocyte apoptosis, perivascular inflammatory infiltrate of lymphocytes, eosinophils and/or neutrophils.	In lesions that are macroscopically free of vesicles or blisters in bullous pemphigoid, there may be eosinophilic spongiosis and eosinophils in the superficial dermis; in dermatitis herpetiformis, there may be neutrophils in the papillary dermis.	Discreet edema in the dermis with abundant eosinophils and ''flame or blaze'' figures, which are not pathognomonic of the disease.	Perivascular lymphomononuclear infiltrate with neutrophils and fewer eosinophils. Neutrophilic epidermotropism may be present.

CSU, Chronic Spontaneous Urticaria; AIS, Autoinflammatory Syndromes (monogenic ones include cryopyrinopathies related to NLRP3 mutations such as CINCA/NOMID, Mückle-Wells Syndrome, familial cold urticaria autoinflammatory syndrome, NLRP-12 mutations, possibly hyper-IgD syndrome and familial Mediterranean fever); NUD, Neutrophilic Urticated Dermatosis; NUSI, Neutrophilic Urticaria with Systemic Symptoms; UV, Urticarial Vasculitis; UD, Urticated Dermatitis; Drug, urticated drug reactions; AIBD, Autoimmune Bullous Diseases with Atypical Presentation (especially bullous pemphigoid and dermatitis herpetiformis); AOSD; Adult-Onset Still's Disease; COBPD, Chronic Obstructive Bronchopulmonary Disease; ANA, Antinuclear Factor; CRP, C-Reactive Protein; ESR, Erythrocyte Sedimentation Rate.

their disease without complete control, notably patients who have severe disease, concomitant CSU, and induced CU, together with elevated levels of d-dimers and serum CRP.[93–97] Although H1sg antihistamines constitute the first line of treatment for CSU, a 2016 systematic review found that standard doses (from the ''on-label'' package insert) controlled 38.3% of patients, and 63.2% of patients required doses increased up to 4× the standard dose.[94] There is evidence of effectiveness and, especially, safety in the use of up to four doses of H1s inhibitors as bilastine, cetirizine, levocetirizine, ebastine, fexofenadine, loratadine, desloratadine, mizolastine, and rupatadine[96]; approximately 32% of patients who did not respond to H1s inhibitors are also partial responders or non-responders to omalizumab, reflecting the heterogeneity of CSU pathogenesis among different patients.[93–96]

H1sg inhibitors act on histamine receptors as inverse agonists, rendering them inactive when bound to them, reversing histamine-induced vasodilation and increased capillary permeability, reducing the edema that constitutes urticaria/angioedema.[96] Furthermore, blocking the action of histamine on receptors in blood vessels and sensory nerve endings indirectly reduces allergic inflammation by decreasing the accumulation of inflammatory cells that migrate to the skin and suppress the immune response to antigens through its action on NFκB, as well as on calcium channels, endothelial cells, dendritic cells, and lymphocytes, also preventing the recruitment of eosinophils, basophils, neutrophils, and other immune cells from the blood to the skin.[96]

It should be noted that first-generation H1 antihistamines (H1fg – chlorpheniramine, diphenhydramine, hydroxyzine, promethazine, clemastine, doxepin, and cyproheptadine) were banned from the treatment of CSU due to their lower selectivity for H1 receptors, while also having affinity for muscarinic, serotonergic, and alpha-adrenergic receptors and cardiac potassium channels. These can cause side effects such as constipation, dry mouth, blurred vision, and can be potentially fatal. H1pg antihistamines are lipophilic drugs that cross the blood-cerebrospinal fluid barrier and, acting on the central nervous system, cause psychomotor changes, drowsiness, a comatose state, and decreased sleep quality (altering the REM sleep phase). These effects include side effects the day after nighttime use, decreased school and work performance, and an increased risk of drowsiness when driving.[96]

Due to their reduced passage through the blood-cerebrospinal fluid barrier, H1sg inhibitors are indicated for the treatment of CSU. However, elderly patients (≥65 years) may be particularly susceptible to some H1sg inhibitors, such as cetirizine and loratadine, when the label-recommended doses are exceeded.[11,74,96]

Omalizumab is indicated in addition to H1sg inhibitors when CSU is not controlled, as a second-line treatment, initially at the label-recommended doses of 300 mg subcutaneously every four weeks for at least six months.[74] Its use is safe in pregnant women and is FDA category B in responding patients. A meta-analysis included randomized studies on the treatment of CSU/CIU, among patients older than 12 years of age, published between January 1, 2000, and July 31, 2021, recovering 854 articles, of which 14 met the inclusion criteria, comprising 577 participants using a placebo and H1 antihistamine and 1,209 participants with an active medication and an H1 antihistamine.[97] It was observed that the effectiveness of omalizumab was dose-dependent, so that patients who are partial responders (to the on-label doses of 300 mg every four weeks) may benefit from increasing doses (450 mg or 600 mg every four weeks) or decreasing the interval to every two or three weeks between doses, which may be due to (i) the presence of higher serum levels of total IgE in these patients, since the most relevant pharmacological effect of omalizumab is to suppress the expression of IgE receptors. This action is due to the neutralization of free IgE in the blood, reducing it to almost zero, (ii) or the greater body weight of these patients.[97]

Compared to the immunosuppressants analyzed in this meta-analysis (including cyclosporine, methotrexate, azathioprine, and hydroxychloroquine), omalizumab was generally associated with greater reductions in DLQI and UAS7 values, while also demonstrating a lower incidence of adverse events.[97] Cyclosporine, in turn, was effective in many patients and can be used in omalizumab-refractory patients or in clinical settings where economic conditions do not allow access to omalizumab. However, it has greater adverse effects when compared to omalizumab.[97] Another meta-analysis involving 67 real-life studies with CSU patients treated with omalizumab demonstrated complete and partial response rates of 72% and 18%, respectively, with an average adverse event rate of 4%, such as headache, fatigue, and injection-site reactions.[98]

In patients with a complete response to omalizumab, anti-H1sg and omalizumab may be tapered every three months, discontinued after 6 to 12 months to determine if CSU remission has occurred.[77] Alternative approaches to partial responses with omalizumab include using it in combination with immunosuppressive/immunomodulatory medications such as cyclosporine, dapsone, and colchicine, although the evidence for this use is very limited, or completely replacing it with cyclosporine, the third-line medication in the international urticaria guidelines.[11,74]

Cyclosporine is a T-cell immunosuppressive agent (inhibiting the production of IL-2, IL-3, IL-4, and TNF-α), which also inhibits the release of mediators from mast cells and basophils, and has been used for over three decades in the treatment of CU.[11,99] Kulthanan et al.[99] conducted a meta-analysis on the efficacy of cyclosporine in the treatment of CSU, involving 909 patients receiving doses between 1 and 5 mg/kg/day, having obtained a response rate to treatment after four weeks, at low doses (2-5 mg/kg/day) of 54% of patients, at eight weeks in 66% of them and at 12 weeks in 73% of patients, with patients presenting one or more adverse events with low doses (2-4 mg/kg/day) in 23% of them and 57% of those receiving moderate doses (4-5 mg/kg/day). Adverse events with the use of cyclosporine were dose-dependent, but the main ones were arterial hypertension and elevated serum creatinine in 6.2% with the use of low doses and 10.3% with moderate doses.[99] Other events included gastrointestinal symptoms (nausea, vomiting, abdominal pain), headache, hirsutism, infections, and paresthesia, observed in 13.9% of patients with low doses and 46.2% of those with moderate doses, with studies with these doses conducted in less than 24 weeks and less than 16 weeks of cyclosporine use, respectively.[99] It should be

noted that prolonged use of cyclosporine, even at very low doses (< 2 mg/kg/day), has been shown over five to ten years to be associated with abnormal glomerular filtration rates and a higher incidence of infections and malignancies among patients.[99]

Within the current therapeutic approach proposed by the international urticaria guide published in 2022,[74] there are, therefore, four medications with consensus regarding their effectiveness[53]: (i) Second-generation antihistamines, which target promoting inverse agonism of H1 receptors and blocking the undesirable effects of histamine; (ii) Omalizumab, which targets IgE sequestration and thus allows the suppression of its receptors on mast cells and basophils, dissociating the IgE bound to these cells in its receptor (FcεRI) and blocking the activation of these cells; (iii) Cyclosporine, which generally inhibits T-cell activation and the release of histamine from mast cells and basophils, and (iv) Glucocorticoids, whose continuous use is contraindicated due to their adverse effects. However, they are useful in exacerbations of CSU when used in 7-day cycles per month, as they do not act directly on mast cells, but inhibit the recruitment of eosinophils from the bone marrow to the peripheral blood and tissues, in addition to blocking the influx of all blood cells into the interstitium of the dermis.[53]

New knowledge about the pathogenesis of CSU has led to the discovery of molecules (biological or small molecules) that can act not only on mast cells and basophils, but also on the predominantly Th2 inflammatory cell infiltrate, which depends on alarmins (TSLP, IL-33, IL-25) produced by epithelial and endothelial cells, which lead Innate Immune Lymphoid Cells type 2 (ILC2) to stimulate, with IL-13 and IL-5, the activation of LTh2, as well as on prostaglandin D2 receptors (CRTH2) that activate lymphocytes, mast cells and basophils.[53] Receptors that stimulate the activation, differentiation, and survival of mast cells, such as c-Kit (CD117), are targeted by monoclonal antibodies such as barzolvolimab, blocking the action of its ligand, Stem Cell Factor (SCF). Other receptors that silence the mast cell and basophilic response, such as Siglec-8 (Sialic acid-binding immunoglobulin-like lectin-8) and Siglec-6, have been targeted by drugs with agonist function (anti-Siglec) to inhibit the function of these cells.[53]

There is a window of opportunity to act on this cascade of immune and inflammatory events, which also, to a lesser extent, involves LTh17 (for now, there are case reports with the use of secukinumab, an anti-IL-17, and tildrakizumab, an anti-IL-23).[100,101] Other biological medications undergoing phase II and III clinical trials, anti-IgEs, anti-TSLP, anti-IL-5 will soon have results published, in addition to dupilumab,[102] which is awaiting registration by regulatory agencies such as the EMA (European Union) and FDA (USA) for the treatment of CSU, but are already approved in Japan, the United Arab Emirates and Brazil for the treatment of the disease. Small molecules for oral use, such as Bruton's tyrosine kinase inhibitors (an intracellular pathway that activates degranulation and cytokine synthesis in mast cells and basophils, as well as a pathway that stimulates antibody synthesis in B cells), such as remibrutinib, fenibrutinib, and risalbrutinib, have been studied in phase II and III studies with promising results.[53]

Interleukin/cytokine receptor inhibitors or blockers

1) Dupilumab

Recent advances in understanding TH2 inflammation in CSU have opened new therapeutic horizons. Dupilumab is a human IgG4 monoclonal antibody that binds to IL-4Ra. This antibody inhibits IL-4 and IL-13-induced IL-4R signaling, reducing TH2 inflammation and potentially inhibiting IgE production in IL-4-treated B cells.[103,104] In a study that analyzed biopsies from patients with Chronic Spontaneous Urticaria (CSU), IL-4+ and IL-5+ cells were found in the lesional skin, with significant elevations compared to controls (patients without CSU). Furthermore, a marked increase in the number of IL-33+, IL-25+, and TSLP+ cells was observed in the dermis of lesional skin, compared to both non-lesional skin and the control group.[57] The increased expression of Th2-initiating cytokines in the lesional skin of patients with CSU suggests that innate pathways may play a role in the mechanism of hives formation.[57] Since Th2-initiating cytokines play a role in mast cell activation, inflammation, and vascular leakage, these findings may also have therapeutic implications for the use of dupilumab, for example.[57]

LIBERTY-CSU CUPID was a phase 3, multicenter, randomized, placebo-controlled, double-blind, 24-week trial.[105] This trial included two independent studies, CUPID A and CUPID B, with different populations and inadequate response to different prior therapies of the same duration. Study CUPID A included patients who had never used omalizumab, and CUPID B included patients intolerant to omalizumab or with an incomplete response.[105] In CUPID A, the combination of dupilumab with second-generation antihistamines provided significant and clinically relevant improvements at week 24, including pruritus, urticaria, and urticaria activity, compared to antihistamines alone.[105] In CUPID B, patients were defined as incomplete responders after three months of treatment with omalizumab, and in this group, there was a statistically significant improvement in pruritus and urticaria assessments after the use of dupilumab.[105,106] In December 2024, dupilumab was approved by ANVISA in Brazil for the treatment of CSU unresponsive to antihistamines in adolescents over 12 years of age and adults.

2) Anti-IL-5

In CSU, IL-5 is responsible for attracting eosinophils to the skin, in addition to promoting their survival and proliferation.[107] One study demonstrated that patients with CSU have higher serum levels of IL-5 receptors than controls.[108] Another study detected higher concentrations of eosinophils in both lesional and non-lesional skin of individuals with CSU compared to controls.[109]

There are some case reports in which mepolizumab, an anti-IL5 monoclonal antibody, was successfully used for the treatment of CSU.[110] An open-label, exploratory, phase 1 study is currently being conducted to evaluate mepolizumab for the treatment of CSU.[111]

Benralizumab, an IL-5 receptor inhibitor (anti-IL-5Rα), underwent a phase 1 study with promising results in CSU.[112] However, these results were not corroborated in the randomized, placebo-controlled clinical trial. Therefore, its development program for CSU was discontinued.[113]

3) Anti-IL-17 – Secukinumab and Anti-IL-23 – Tildrakizumab

In a study of patients with CU, the levels of circulating inflammatory cytokines such as IL-6, TNF-α, and IL-12 were evaluated.[114] These were found at elevated levels in patients with chronic urticaria, in association with increased secretion of IL-2 and IL-17 after T-cell stimulation.[60,114] In another study, serum levels of IL-17, TNF-α, and IL-23 were evaluated in patients with CSU, in relation to the values of the urticaria activity scale, positive autoserum test in patients, and prick test results.[115] The concentration of these cytokines was significantly higher in patients with CSU compared to controls in all of these studies.[60,114,115]

In a recent study, patients with severe CSU resistant to conventional treatment were treated off-label with anti-IL-17A (secukinumab – 150 mg weekly for four weeks and then every two weeks).[116] The improvement in disease activity (UAS7) was 55% at 30 days and 82% at three months. Discontinuation of treatment after six to eight months resulted in CSU relapse, indicating that anti-IL-17 would be necessary for a longer period.[116]

A case series reported the use of tildrakizumab, an anti-IL-23 agent, in three patients with high disease activity refractory to treatment with quadrupled doses of second-generation H1 antihistamines and omalizumab.[117] These patients received three doses of tildrakizumab 100 mg (at weeks 0, 4, and 12, the dose and interval used as licensed for psoriasis) as an off-label treatment, while maintaining antihistamines at quadruple doses. The treatment was well tolerated and led to significant improvements in disease activity and control in all patients after 12 weeks, with reductions in UAS7 and UCT scores and improvements in quality of life.[117] One patient achieved remission, another maintained adequate control with antihistamines, and one relapsed after stopping the drug.[117]

4) Anti-thymic stromal lymphopoietin (TSLP): Tezepelumab

Thymic stromal lymphopoietin (TSLP) is an epithelial-derived cytokine (alarmin) produced in response to environmental and pro-inflammatory stimuli. It is associated with the regulation of type 2 immunity, acting on dendritic cells, T and B cells, and innate immune lymphoid cells (ILC2).[10] TSLP expression is higher in the airways of patients with asthma, and its levels correlate with the expression of Th2 cytokines and chemokines and disease severity.[10,118]

Tezepelumab (AMG 157/MEDI9929) is a human IgG1 monoclonal antibody undergoing investigation that binds to TSLP, preventing its interaction with the TSLP receptor complex.[118] In a phase 2b study registered in Clinical Trials (INCEPTION study) with a 32-week observation period, comparing the effect of Tezepelumab (210 mg every four weeks or 420 mg every two weeks) versus omalizumab (300 mg every four weeks) or placebo, in patients refractory to optimized treatment with quadrupled doses of H1 antihistamines, a sustained treatment effect was observed in the Tezepelumab arms, not achieved with omalizumab or placebo.[119] Improvements in UAS7 values with the drug occurred with continued reductions in IL-5 and IL-13, regardless of changes in IgE levels.[119] In patients who never used anti-IgE, Tezepelumab treatment led to reductions in CSU activity and biomarkers after treatment discontinuation, suggesting a sustained effect of TSLP blocking after treatment cessation.[10,119]

Bruton's Tyrosine Kinase Inhibitors (BTK Inhibitors)

1) Remibrutinib

Remibrutinib (LOU064), an oral, covalent (stable-binding) BTK inhibitor, exhibits high selectivity and potency for this intracellular signaling pathway molecule in mast cells, basophils, and B cells. The high selectivity and tolerability of remibrutinib are likely due to its ability to bind to an inactive conformation of BTK.[120]

In a phase I study, remibrutinib was also effective in inhibiting basophil activation.[121] In a phase 2b clinical trial, the efficacy and safety of oral remibrutinib at various doses were demonstrated in patients with CSU inadequately controlled with second-generation antihistamines.[122] All doses of remibrutinib (10 mg/day, 35 mg/day, 100 mg/day, 10 mg twice daily, 25 mg twice daily, and 100 mg twice daily) significantly improved the signs and symptoms of CSU compared to placebo, with rapid clinical improvement observed in the first week (improvement of pruritus and hives) and maintained until week 12.[122] Greater overall efficacy was observed with remibrutinib 25 mg twice daily compared with placebo.[122]

Prior treatment with anti-IgE therapy did not affect the change in UAS7 score from baseline to week 12, as no relevant difference was observed between anti-IgE-experienced and naive patients in either the remibrutinib (any dose) or placebo arms.[122] Remibrutinib demonstrated a favorable safety profile at all tested doses.[122] Most Adverse Events (AEs) were mild or moderate, and the proportion of patients with at least one AE was similar across remibrutinib doses, indicating no dose-dependent pattern.[122] Similarly, the extension study of remibrutinib, observing patients who had UAS7 $\geq$ 16 in the previous 16-week study, remained in this study with remibrutinib at a dose of 100 mg twice daily for 52 weeks, in order to evaluate adverse events, the three most common of which were infections (30.9%) in the skin and subcutaneous tissue (26.8%) and gastrointestinal disorders (16.5%). UAS7 = 0 was achieved by 28.2% at week 4 and 55.8% at week 52, and UAS7 $\leq$ 6 by 52.5% at week 4 and 68.0% at week 52, demonstrating the efficacy and safety of this medication.[123]

2) Fenebrutinib

Fenebrutinib is an oral, highly selective, and reversible BTK inhibitor that blocks IgE-mediated histamine release from mast cells *in vitro*. In a phase 1 study, fenebrutinib inhibited IgE-mediated basophil activation in healthy volunteers. Thus, BTK inhibition by fenebrutinib may also interrupt the production of autoantibodies that activate FcεRI in CSU. A phase 2b, multicenter, randomized, double-

blind, placebo-controlled study involving 134 participants in 57 days of treatment, distributed in a pilot cohort (cohort 1, dose of 200 mg, twice a day) and a variable-dose cohort (cohort 2, subdivided into doses of 50 mg daily, 150 mg daily and 200 mg twice a day), observed the efficacy and safety of fenebrutinib, compared to placebo, in adult patients with CSU for more than six months, symptomatic despite treatment with H1 antihistamines at an optimized dose (up to four times the approved dose in the package insert).[124] The rapid onset of efficacy suggests that the main mechanism of action of the drug in CSU is inhibition of the FcεRI signal via inhibition of BTK in mast cells and basophils.[125] Fenebrutinib controlled CSU in patients with type IIb autoimmunity at all tested doses.[124,125]

However, at lower doses, patients with type IIb autoimmunity experienced greater benefit than patients without type IIb-associated markers.[125] Patients with type IIb autoimmunity may be more sensitive to BTK inhibition, while patients with type I autoallergy may derive additional clinical benefit from higher levels of pathway inhibition to achieve maximal efficacy.[125] The primary endpoint of achieving a UAS7 ≤ 7 was achieved with the 200 mg twice daily and 150 mg daily doses, but not with the 50 mg daily dose of fenebrutinibe. Asymptomatic and reversible grade 2 and 3 transaminase elevations occurred with the 150 mg daily and 200 mg twice daily doses (two participants in each group).[125]

MGPRX2 Receptor Inhibitor

In addition to the high-affinity IgE receptor (FcεRI), mast cells express numerous G-protein-coupled receptors (GPCRs), which can be activated by neuropeptides, major basic protein (MBP), and eosinophil peroxidase (EPO), among others, culminating in mast cell degranulation.[126] Mas-related G-protein-coupled receptor X2 (MRGPRX2) is a GPCR expressed with some selectivity by mast cells and can be present both in the plasma membrane and intracellularly.[126] MRGPRX2 expression is increased in the skin of individuals with CSU when compared with healthy controls.[127] Fujisawa et al. [127] also observed eosinophil infiltration in the lesional skin in seven out of nine individuals with CSU. The authors also demonstrated that proteins originating from eosinophils (MBP and EP) are capable of inducing histamine release; this effect is inhibited in cells in which MRGPRX2 is silenced.[127] An oral MRGPRX2 inhibitor (EP262) is currently recruiting for a phase 2 clinical trial for CSU, a study called CALM-CSU.[128]

Tyrosine kinase receptor (KIT) inhibitors (c-KIT ligand inhibitors)

KITs (CD117) are transmembrane receptors for Stem Cell Factor (SCF) and are present on progenitor cell lines.[129] In the case of mast cells, even mature cells continue to express KIT at high levels.[129] When activated by SCF, KIT promotes cell survival, migration, and the secretion of several inflammatory mediators.[129] In mast cells, KIT activation by SCF induces degranulation.[129]

Barzolvolimab is a humanized monoclonal antibody that binds to the KIT extracellular domain on mast cells, preventing SCF binding and subsequent mast cell activation.[130] In a randomized phase 2 clinical trial for the treatment of CSU, barzolvolimab demonstrated a significant improvement in the UAS7 score compared to the placebo group, over a 12-week follow-up.[131] No major adverse effects were observed in this same study.[131] In Chronic inducible urticaria (CIndU), specifically symptomatic dermographism and cold urticaria, there was complete resolution of the condition in 95% of patients after a single infusion of barzolvolimab, over a 12-week follow-up.[132] Furthermore, there was a significant reduction in the number of mast cells in the patients' skin, as well as a reduction in tryptase levels and an increase in soluble SCF after treatment.[132] Barzolvolimab is currently being investigated in phase 3 clinical trials for CSU and is considered a promising treatment for CSU (EMBARQ-CSU2 study).[133]

Briquilimab is another anti-KIT monoclonal antibody that is being evaluated for the treatment of CSU, but is still recruiting participants.[134]

Anti-Siglecs Medications

Siglecs, short for sialic-acid-binding immunoglobulin-like lectins, are a family of receptors expressed on mast cells, eosinophils, and basophils.[135] They have an inhibitory function, acting as immune system checkpoints.[135] Siglec-6 and -8 have been explored as therapeutic targets in allergic diseases.[135] Siglec-8 induces eosinophil apoptosis and inhibits mast cell activation; siglec-6 appears to promote even more potent inhibitory signals in mast cells.[135,136]

Lirentelimab (AK002), an anti-Siglec-8 monoclonal antibody, has been evaluated for the treatment of CSU. Despite showing promising results in an initial proof-of-concept study, the subsequent phase 2 clinical trial did not meet the primary endpoint and was terminated early by the manufacturer.[137] A humanized IgG1 anti-Siglec-6 monoclonal antibody (AK006) is currently being investigated in clinical trials for the treatment of CSU.[138]

Conclusions

Urticaria, and CSU in particular, is a disease with rapidly expanding knowledge regarding its pathophysiological aspects, which are the basis for the development of new drugs for its management.

Many genetic aspects that may predispose individuals to the disease, the exogenous factors that play a variable and individual role, the recognition of specific endotypes (autoallergic and autoimmune), the central role of mast cell degranulation, the important role of different cells and mediators, comprising diverse mechanisms in the pathogenesis, and biomarkers have been established; however, there are still gaps to be addressed.

Studies on new drugs for the treatment of CSU reflect the multiplicity of pathogenic pathways. Once clinical trials demonstrate efficacy and safety, as has already been the case with omalizumab and others, regimens with immunobiologicals and/or small molecules will likely be considered alternatives to current treatments, especially in cases of resistance to conventional management.

The fight for a better quality of life for patients with CSU is constant, and science is on our side, reminding us that

promising therapies must be accompanied by concerns about accessibility, correct indication, and clinical monitoring.

Editor

Ana Maria Roselino.

Financial support

None declared.

Research data availability

The entire dataset supporting the results of this study was published in this article.

Authors' contributions

Hélio Amante Miot: Study design, drafting and editing of the manuscript, and approval of the final version of the manuscript.

Roberta Fachini Jardim Criado: Study design, drafting and editing of the manuscript, and approval of the final version of the manuscript.

Paulo Ricardo Criado: Study design, drafting and editing of the manuscript, and approval of the final version of the manuscript.

Helena Zenedin Marchioro: Study design, drafting and editing of the manuscript, and approval of the final version of the manuscript.

Renan Rangel Bonamigo: Study design, drafting and editing of the manuscript, and approval of the final version of the manuscript.

Beatrice Martinez Zugaib Abdalla: Study design, drafting and editing of the manuscript, and approval of the final version of the manuscript.

Conflicts of interest

Paulo Criado: Advisory board – Pfizer, Galderma, Takeda, Hypera, Novartis, Sanofi; Clinical research - Pfizer, Novartis, Sanofi, Amgen and Lilly; Lecturer: Pfizer, Abbvie, Sanofi-Genzyme, Hypera, Takeda, Novartis.

Roberta Fachini Jardim Criado: Advisory board – Pfizer, Takeda, Hypera, Novartis, Sanofi; Clinical research - Pfizer, Novartis, Sanofi and Lilly; Lecturer: Pfizer, Abbvie, Sanofi-Genzyme, Hypera, Takeda, Novartis.

Hélio Miot: Advisory Board – Johnson & Johnson, L'Oréal, Theraskin, Sanofi e Pfizer; clinical research Abbvie, Galderma and Merz.

Beatrice Martinez Zugaib Abdalla – No conflicts of interest declared.

Helena Marchioro – Advisory Board – Novartis and UCB Pharm; Lecturer: Johnson & Johnson, Novartis and UCB Pharma.

Renan Bonamigo – No conflicts of interest declared.

Acknowledgement

In memory of the legacy of Prof. Marcus Mauer (1966–2024) regarding the study of urticaria and mast cell diseases.

References

1. Armstrong AW, Soong W, Bernstein JA. Chronic Spontaneous Urticaria: how to measure it and the need to define treatment success. Dermatol Ther (Heidelb). 2023;13:1629–46.
2. Elieh-Ali-Komi D, Metz M, Kolkhir P, Kocatürk E, Scheffel J, Frischbutter S, et al. Chronic urticaria and the pathogenic role of mast cells. Allergol Int. 2023;72:359–68.
3. Fricke J, Ávila G, Keller T, Weller K, Lau S, Maurer M, et al. Prevalence of chronic urticaria in children and adults across the globe: systematic review with meta-analysis. Allergy. 2020;75:423–32.
4. Criado RFJ, Criado PR, Baldavira N, Cardial D, Gimenez-Arnau AM, Machado Filho CD. What lessons can we learn? Clinical and epidemiological retrospective analysis of 267 patients with urticaria in a Brazilian tertiary center. An Bras Dermatol. 2021;96:436–41.
5. Balp MM, Lopes da Silva N, Vietri J, Tian H, Ensina LF. The burden of chronic urticaria from brazilian patients' perspective. Dermatol Ther (Heidelb). 2017;7:535–45.
6. Silvares MR, Fortes MR, Miot HA. Quality of life in chronic urticaria: a survey at a public university outpatient clinic, Botucatu (Brazil). Rev Assoc Med Bras (1992). 2011;57:577–82.
7. Eun SJ, Lee JY, Kim DY, Yoon HS. Natural course of new-onset urticaria: results of a 10-year follow-up, nationwide, population-based study. Allergol Int. 2019;68:52–8.
8. Balp MM, Halliday AC, Severin T, Leonard SA, Partha G, Kalra M, et al. Clinical remission of chronic spontaneous urticaria (CSU): a targeted literature review. Dermatol Ther (Heidelb). 2022;12:15–27.
9. Sánchez J, Álvarez L, Cardona R. Prospective analysis of clinical evolution in chronic urticaria: persistence, remission, recurrence, and pruritus alone. World Allergy Organ J. 2022;15:100705.
10. Maurer M, Kolkhir P, Pereira MP, Siebenhaar F, Witte-Händel E, Bergmann KC, et al. Disease modification in chronic spontaneous urticaria. Allergy. 2024;79:2396–413.
11. Kolkhir P, Giménez-Arnau AM, Kulthanan K, Peter J, Metz M, Maurer M. Urticaria. Nat Rev Dis Primers. 2022;8:61.
12. van Neste D, Bouillenne C. HLA antigens and urticaria. Arch Dermatol Res. 1978;261:213–5.
13. Mekori YA, Giorno RC, Anderson P, Kohler PF. Lymphocyte subpopulations in the skin of patients with chronic urticaria. J Allergy Clin Immunol. 1983;72:681–4.
14. Haas N, Iwen W, Grabbe J, Uchanska-Ziegler B, Czarnetzki BM. MHC class II antigen expression is increased in different forms of urticaria. Int Arch Allergy Immunol. 1996;109:177–82.
15. Leung DY, Bhan AK, Schneeberger EE, Geha RS. Characterization of the mononuclear cell infiltrate in atopic dermatitis using monoclonal antibodies. J Allergy Clin Immunol. 1983;71:47–56.
16. O'Donnell BF, O'Neill CM, Francis DM, Niimi N, Barr RM, Barlow RJ, et al. Human leucocyte antigen class II associations in chronic idiopathic urticaria. Br J Dermatol. 1999;140:853–8.
17. Qi Y, Zhang L, Yang X, Tang B, Xiao T. Genome-wide DNA methylation profile in whole blood of patients with chronic spontaneous urticaria. Front Immunol. 2021;12:681714.
18. Kolkhir P, Borzova E, Grattan C, Asero R, Pogorelov D, Maurer M. Autoimmune comorbidity in chronic spontaneous urticaria: a systematic review. Autoimmun Rev. 2017;16:1196–208.

19. Kulinski JM, Muñoz-Cano R, Olivera A. Sphingosine-1-phosphate and other lipid mediators generated by mast cells as critical players in allergy and mast cell function. Eur J Pharmacol. 2016;778:56–67.
20. Zhang L, Qiu L, Wu J, Qi Y, Gao X, He C, et al. GWAS of chronic spontaneous urticaria reveals genetic overlap with autoimmune diseases, not atopic diseases. J Invest Dermatol. 2023;143:67–77.
21. Criado RFJ, Criado PR, Pagliari C, Sotto MN, Machado Filho CD, Bianco B. M2 macrophage polarization in chronic spontaneous urticaria refractory to antihistamine treatment. Allergol Int. 2021;70:504–6.
22. Zhang DM, Bao YL, Yu CL, Wang YM, Song ZB. Cripto-1 modulates macrophage cytokine secretion and phagocytic activity via NF-κB signaling. Immunol Res. 2016;64:104–14.
23. Ciprandi G, Corsico A, Pisati P. Serum-soluble HLA-G is associated with specific IgE in patients with allergic rhinitis and asthma. Inflammation. 2014;37:1630–4.
24. Palikhe NS, Kim SH, Ye YM, Hur GY, Cho BY, Park HS. Association of CRTH2 gene polymorphisms with the required dose of antihistamines in patients with chronic urticaria. Pharmacogenomics. 2009;10:375–83.
25. Li J, Guo A, Chen W, Bin L, He Y, Zhu W, et al. Association of ORAI1 gene polymorphisms with chronic spontaneous urticaria and the efficacy of the nonsedating H1 antihistamine desloratadine. J Allergy Clin Immunol. 2017;139:1386–8.
26. Hosseini Farahabadi S, Tavakkol-Afshari J, Ganjali R, Rafatpanah H, Ghaffari J, Farid-Hosseini R. Association between the polymorphism of TGF-beta1 gene promoter (-509C&T) and idiopathic chronic urticaria. Iran J Allergy Asthma Immunol. 2006;5:109–13.
27. Bozek A, Krajewska J, Filipowska B, Polanska J, Rachowska R, Grzanka A, et al. HLA status in patients with chronic spontaneous urticaria. Int Arch Allergy Immunol. 2010;153:419–23.
28. Coban M, Erdem T, Ozdemir S, Pirim I, Atasoy M, Ikbal M. HLA class I and class II genotyping in patients with chronic urticaria. Int Arch Allergy Immunol. 2008;147:135–9.
29. Chang D, Hammer C, Holweg CTJ, Selvaraj S, Rathore N, McCarthy MI, et al. A genome-wide association study of chronic spontaneous urticaria risk and heterogeneity. J Allergy Clin Immunol. 2023;151:1351–6.
30. Movahedi M, Tavakol M, Rahmani F, Amirzargar AA, Bidoki AZ, Heidari K, et al. Single nucleotide polymorphisms of IL-2, but not IL-12 and IFN-γ, are associated with increased susceptibility to chronic spontaneous urticaria. Allergol Immunopathol (Madr). 2017;45:333–8.
31. Fang X, Weng Y, Zheng X. Involvement of *CCL2* and *CH25H* Genes and TNF signaling pathways in mast cell activation and pathogenesis of chronic spontaneous urticaria. Front Immunol. 2023;14:1247432.
32. de Montjoye L, Herman A, Hendrickx E, Chéou P, Blanchetot C, Hofman E, et al. Increased expression of IL-24 in chronic spontaneous urticaria. Allergy. 2019;74:1811–3.
33. Malmros H. Autoserum test (AST). Nordisk Med. 1946;29:150–1.
34. Asero R, Pinter E, Tedeschi A. 35 years of autologous serum skin test in chronic spontaneous urticaria: what we know and what we do not know. Eur Ann Allergy Clin Immunol. 2023;55:4–8.
35. Grattan CE, Wallington TB, Warin RP, Kennedy CT, Bradfield JW. A serological mediator in chronic idiopathic urticaria – a clinical, immunological and histological evaluation. Br J Dermatol. 1986;114:583–90.
36. Puxeddu I, Pistone F, Pisani F, Levi-Schaffer F. Mast cell signaling and its role in urticaria. Ann Allergy Asthma Immunol. 2024;133:374–9.
37. Gruber BL, Baeza ML, Marchese MJ, Agnello V, Kaplan AP. Prevalence and functional role of anti-IgE autoantibodies in urticarial syndromes. J Invest Dermatol. 1988;90:213–7.
38. Grattan CE, Francis DM, Hide M, Greaves MW. Detection of circulating histamine releasing autoantibodies with functional properties of anti-IgE in chronic urticaria. Clin Exp Allergy. 1991;21:695–704.
39. Niimi N, Francis DM, Kermani F, O'Donnell BF, Hide M, Kobza-Black A, et al. Dermal mast cell activation by autoantibodies against the high affinity IgE receptor in chronic urticaria. J Invest Dermatol. 1996;106:1001–6.
40. Fiebiger E, Maurer D, Holub H, Reininger B, Hartmann G, Woisetschläger M, et al. Serum IgG autoantibodies directed against the alpha chain of Fc epsilon RI: a selective marker and pathogenetic factor for a distinct subset of chronic urticaria patients? J Clin Invest. 1995;96:2606–12.
41. Altrichter S, Peter HJ, Pisarevskaja D, Metz M, Martus P, Maurer M. IgE mediated autoallergy against thyroid peroxidase–a novel pathomechanism of chronic spontaneous urticarial? PLoS One. 2011;6:e14794.
42. Giménez-Arnau AM, Podder I. Current perspectives and future directions in the management of chronic spontaneous urticaria and their link to disease pathogenesis and biomarkers. Ital J Dermatol Venerol. 2023;158:302–15.
43. Asero R, Marzano AV, Ferrucci S, Lorini M, Carbonelli V, Cugno M. Co-occurrence of IgE and IgG autoantibodies in patients with chronic spontaneous urticaria. Clin Exp Immunol. 2020;200:242–9.
44. Schmetzer O, Lakin E, Topal FA, Preusse P, Freier D, Church MK, et al. IL-24 is a common and specific autoantigen of IgE in patients with chronic spontaneous urticaria. J Allergy Clin Immunol. 2018;142:876–82.
45. Sánchez J, Sánchez A, Cardona R. Causal relationship between anti-TPO IgE and chronic urticaria by *in vitro* and *in vivo* tests. Allergy Asthma Immunol Res. 2019;11:29–42.
46. Yu L, Buttgereit T, Stahl Skov P, Schmetzer O, Scheffel J, Kocatürk E, et al. Immunological effects and potential mechanisms of action of autologous serum therapy in chronic spontaneous urticaria. J Eur Acad Dermatol Venereol. 2019;33:1747–54.
47. Kolkhir P, Muñoz M, Asero R, Ferrer M, Kocatürk E, Metz M, et al. Autoimmune chronic spontaneous urticaria. J Allergy Clin Immunol. 2022;149:1819–31.
48. Kolkhir P, Church MK, Altrichter S, Skov PS, Hawro T, Frischbutter S, et al. Eosinopenia, in chronic spontaneous urticaria, is associated with high disease activity, autoimmunity, and poor response to treatment. J Allergy Clin Immunol Pract. 2020;8:318–25.
49. Altrichter S, Zampeli V, Ellrich A, Zhang K, Church MK, Maurer M. IgM and IgA in addition to IgG autoantibodies against FcεRIα are frequent and associated with disease markers of chronic spontaneous urticaria. Allergy. 2020;75:3208–15.
50. Schoepke N, Asero R, Ellrich A, Ferrer M, Gimenez-Arnau A, Grattan CEH, et al. Biomarkers and clinical characteristics of autoimmune chronic spontaneous urticaria: results of the PURIST Study. Allergy. 2019;74:2427–36.
51. Sella JA, Ferriani MPL, Melo JML, Trevisan Neto O, Zanetti MET, Cordeiro DL, et al. Type I and type IIb autoimmune chronic spontaneous urticaria: using common clinical tools for endotyping patients with CSU. J Allergy Clin Immunol Glob. 2023;2:100159.
52. Xiang YK, Kolkhir P, Scheffel J, Sauer M, Vera C, Frischbutter S, et al. Most patients with autoimmune chronic spontaneous urticaria also have autoallergic urticaria, but not viceversa. J Allergy Clin Immunol Pract. 2023;11:2417–25.
53. Maurer M, Khan DA, Elieh Ali Komi D, Kaplan AP. Biologics for the use in chronic spontaneous urticaria: when and which. J Allergy Clin Immunol Pract. 2021;9:1067–78.
54. Church MK, Kolkhir P, Metz M, Maurer M. The role and relevance of mast cells in urticaria. Immunol Rev. 2018;282:232–47.

55. Elias J, Boss E, Kaplan AP. Studies of the cellular infiltrate of chronic idiopathic urticaria: prominence of T-lymphocytes, monocytes, and mast cells. J Allergy Clin Immunol. 1986;78:914–8.
56. Dobrican-Băruța CT, Deleanu DM, Muntean IA, Nedelea I, Bălan RG, Filip GA, et al. The alarmin Triad-IL-25, IL-33, and TSLP-serum levels and their clinical implications in chronic spontaneous urticaria. Int J Mol Sci. 2024;25:2026.
57. Kay AB, Clark P, Maurer M, Ying S. Elevations in T-helper-2-initiating cytokines (interleukin-33, interleukin-25 and thymic stromal lymphopoietin) in lesional skin from chronic spontaneous ('idiopathic') urticaria. Br J Dermatol. 2015;172:1294–302.
58. Mubariki R, Samara R, Gimenez-Arnua AM, Maurer M, Bejar J, Toubi E, et al. $CD4^{+}CCR5^{+}$ T-cells and CCL3+ mast cells are increased in the skin of patients with chronic spontaneous urticaria. Front Immunol. 2024;15:1327040.
59. Auyeung P, Mittag D, Hodgkin PD, Harrison LC. Autoreactive T cells in chronic spontaneous urticaria target the IgE Fc receptor Iα subunit. J Allergy Clin Immunol. 2016;138:761–8.
60. Toubi E, Vadasz Z. The emerging role of IL-17 in the immune-pathogenesis of chronic spontaneous urticaria. Immunotargets Ther. 2020;9:217–23.
61. Asero R, Tedeschi A, Riboldi P, Cugno M. Plasma of patients with chronic urticaria shows signs of thrombin generation, and its intradermal injection causes wheal-and-flare reactions much more frequently than autologous serum. J Allergy Clin Immunol. 2006;117:1113–7.
62. Takahagi S, Mihara S, Iwamoto K, Morioke S, Okabe T, Kameyoshi Y, et al. Coagulation/fibrinolysis and inflammation markers are associated with disease activity in patients with chronic urticaria. Allergy. 2010;65:649–56.
63. Criado PR, Antinori LC, Maruta CW, Reis VM. Evaluation of D-dimer serum levels among patients with chronic urticaria, psoriasis and urticarial vasculitis. An Bras Dermatol. 2013;88:355–60.
64. Criado RF, Bensi CG, Criado PR, Henriques MT, de Espindola BAR, Machado Filho CD. Evaluation of serum levels of C-reactive protein, D-Dimer and autologous serum skin test in patients with chronic spontaneous urticaria in a brazilian tertiary center: a cross-sectional study. An Bras Dermatol. 2021;96:148–54.
65. Yanase Y, Takahagi S, Ozawa K, Hide M. The role of coagulation and complement factors for mast cell activation in the pathogenesis of chronic spontaneous urticaria. Cells. 2021;10:1759.
66. Tedeschi A, Kolkhir P, Asero R, Pogorelov D, Olisova O, Kochergin N, et al. Chronic urticaria and coagulation: pathophysiological and clinical aspects. Allergy. 2014;69:683–91.
67. Zhu L, Jian X, Zhou B, Liu R, Muñoz M, Sun W, et al. Gut microbiota facilitate chronic spontaneous urticaria. Nat Commun. 2024;15:112.
68. Cai R, Zhou C, Tang R, Meng Y, Zeng J, Li Y, et al. Current insights on gut microbiome and chronic urticaria: progress in the pathogenesis and opportunities for novel therapeutic approaches. Gut Microbes. 2024;16:2382774.
69. Labib A, Yap QV, Smith P, Yosipovitch G. Scratch pleasurability is high in chronic spontaneous urticaria. J Allergy Clin Immunol Pract. 2022;10:3337–8.
70. Garcovich S, Maurelli M, Gisondi P, Peris K, Yosipovitch G, Girolomoni G. Pruritus as a distinctive feature of type 2 inflammation. Vaccines (Basel). 2021;9:303.
71. Zhang Y, Zhang H, Du S, Yan S, Zeng J. Advanced Biomarkers: therapeutic and diagnostic targets in urticaria. Int Arch Allergy Immunol. 2021;182:917–31.
72. Strimbu K, Tavel JA. What are biomarkers? Curr Opin HIV AIDS. 2010;5:463–6.
73. Asero R, Cugno M. Biomarkers of chronic spontaneous urticaria and their clinical implications. Expert Rev Clin Immunol. 2021;17:247–54.
74. Zuberbier T, Abdul Latiff AH, Abuzakouk M, Aquilina S, Asero R, Baker D, et al. The international EAACI/GA^{2}LEN/EuroGuiDerm/APAAACI guideline for the definition, classification, diagnosis, and management of urticaria. Allergy. 2022;77:734–66.
75. Pedersen NH, Sørensen JA, Ghazanfar MN, Zhang DG, Vestergaard C, Thomsen SF. Biomarkers for monitoring treatment response of omalizumab in patients with chronic urticaria. Int J Mol Sci. 2023;24:11328.
76. Kolkhir P, Bonnekoh H, Metz M, Maurer M. Chronic spontaneous urticaria: a review. JAMA. 2024;332:1464–77, http://dx.doi.org/10.1001/jama.2024.15568. Epub ahead of print.
77. Xiang YK, Türk M, Ojeda IC, Elieh-Ali-Komi D, Salman Andac, Kocartürk Emek. Psychological stress and urticaria: pathophysiologic and therapeutic updates. Curr Treat Options Allergy. 2024;11:194–210.
78. Wallace D, Cooper NR, Sel A, Russo R. The social readjustment rating scale: updated and modernised. PLoS One. 2023;18:e0295943.
79. Papapostolou N, Xepapadaki P, Katoulis A, Makris M. Comorbidities of chronic urticaria: a glimpse into a complex relationship. Front Allergy. 2022;3:1008145.
80. Cornillier H, Giraudeau B, Munck S, Hacard F, Jonville-Bera AP, d'Acremont G, et al. Chronic spontaneous urticaria in children – a systematic review on interventions and comorbidities. Pediatr Allergy Immunol. 2018;29:303–10.
81. Thomsen SF, Pritzier EC, Anderson CD, Vaugelade-Baust N, Dodge R, Dahlborn AK, et al. Chronic urticaria in the real-life clinical practice setting in Sweden, Norway and Denmark: baseline results from the non-interventional multicentre AWARE study. J Eur Acad Dermatol Venereol. 2017;31:1048–55.
82. Lachover-Roth I, Rabie A, Cohen-Engler A, Rosman Y, Meir-Shafrir K, Confino-Cohen R. Chronic urticaria in children – new insights from a large cohort. Pediatr Allergy Immunol. 2021;32:999–1005.
83. Friedman A, Kwatra SG, Yosipovitch G. A practical approach to diagnosing and managing chronic spontaneous urticaria. Dermatol Ther (Heidelb). 2024;14:1371–87.
84. Gooderham MJ, Kwatra SG, Geng B. From research to practice: the latest data on evolving treatments for chronic spontaneous urticaria. J Drugs Dermatol. 2024;23:795–806.
85. Krause K, Bonnekoh H, Jelden-Thurm J, Asero R, Gimenez-Arnau AM, Cardoso JC, et al. Differential diagnosis between urticarial vasculitis and chronic spontaneous urticaria: an international Delphi survey. Clin Transl Allergy. 2023;13:e12305.
86. Bernstein JA, Ziaie N, Criado R, Criado PR, Rea S, Davis M. Chronic urticaria and angioedema: masqueraders and misdiagnoses. J Allergy Clin Immunol Pract. 2023;11:2251–63.
87. López Mateos A, Sánchez Pujol MJ, Silvestre Salvador JF. Skin biopsy in chronic urticaria: when and where and what to look for? Actas Dermosifiliogr (Engl Ed). 2021;112:406–13.
88. Suh KS, Kang DY, Lee KH, Han SH, Park JB, Kim ST, et al. Evolution of urticarial vasculitis: a clinical, dermoscopic and histopathological study. J Eur Acad Dermatol Venereol. 2014;28:674–5.
89. Buttgereit T, Vera C, Aulenbacher F, Church MK, Hawro T, Asero R, et al. Patients with chronic spontaneous urticaria who have hives, angioedema, or both, differ demographically, clinically, and in response to treatment-results from CURE. J Allergy Clin Immunol Pract. 2023;11:3515–25.
90. Criado PR, Ianhez M, Silva de Castro CC, Talhari C, Ramos PM, Miot HA. COVID-19 and skin diseases: results from a survey of 843 patients with atopic dermatitis, psoriasis,

vitiligo and chronic urticaria. J Eur Acad Dermatol Venereol. 2022;36:e1–3.
91. Kocatürk E, Salman A, Cherrez-Ojeda I, Criado PR, Peter J, Comert-Ozer E, et al. The global impact of the COVID-19 pandemic on the management and course of chronic urticaria. Allergy. 2021;76:816–30.
92. Kocatürk E, Salameh P, Sarac E, Vera Ayala CE, Thomsen SF, Zuberbier T, et al. Urticaria exacerbations and adverse reactions in patients with chronic urticaria receiving COVID-19 vaccination: results of the UCARE COVAC-CU study. J Allergy Clin Immunol. 2023;152:1095–106.
93. Zuberbier T, Ensina LF, Giménez-Arnau A, Grattan C, Kocatürk E, Kulthanan K, et al. Chronic urticaria: unmet needs, emerging drugs, and new perspectives on personalised treatment. Lancet. 2024;404:393–404.
94. Guillén-Aguinaga S, Jáuregui Presa I, Aguinaga-Ontoso E, Guillén-Grima F, Ferrer M. Updosing nonsedating antihistamines in patients with chronic spontaneous urticaria: a systematic review and meta-analysis. Br J Dermatol. 2016;175:1153–65.
95. Bernstein JA, Kavati A, Tharp MD, Ortiz B, MacDonald K, Denhaerynck K, et al. Effectiveness of omalizumab in adolescent and adult patients with chronic idiopathic/spontaneous urticaria: a systematic review of' real-world' evidence. Expert Opin Biol Ther. 2018;18:425–48.
96. Xiang YK, Fok JS, Podder I, Yücel MB, Özkoca D, Thomsen SF, et al. An update on the use of antihistamines in managing chronic urticaria. Expert Opin Pharmacother. 2024;25:551–69.
97. Lin WK, Lin SJ, Lee WR, Lin CC, Lin WC, Chang HC, et al. Effectiveness and safety of immunosuppressants and biological therapy for chronic spontaneous urticaria: a network meta-analysis. Biomedicines. 2022;10:2152.
98. Tharp MD, Bernstein JA, Kavati A, Ortiz B, MacDonald K, Denhaerynck K, et al. Benefits and harms of omalizumab treatment in adolescent and adult patients with chronic idiopathic (spontaneous) urticaria: a meta-analysis of ''real-world'' evidence. JAMA Dermatol. 2019;155:29–38.
99. Kulthanan K, Chaweekulrat P, Komoltri C, Hunnangkul S, Tuchinda P, Chularojanamontri L, et al. Cyclosporine for chronic spontaneous urticaria: a meta-analysis and systematic review. J Allergy Clin Immunol Pract. 2018;6:586–99.
100. Bonnekoh H, Kiefer L, Buttgereit T, Kolkhir P, Lütke-Eversloh M, Scheffel J, et al. Anti-IL-23 treatment with tildrakizumab can be effective in omalizumab-refractory chronic spontaneous urticaria: a case series. J Allergy Clin Immunol Pract. 2023;11:2578–80.
101. Sabag DA, Matanes L, Bejar J, Sheffer H, Barzilai A, Church MK, et al. Interleukin-17 is a potential player and treatment target in severe chronic spontaneous urticaria. Clin Exp Allergy. 2020;50:799–804.
102. Maurer M, Casale TB, Saini SS, Ben-Shoshan M, Laws E, Maloney J, et al. Dupilumab reduces urticaria activity, itch, and hives in patients with chronic spontaneous urticaria regardless of baseline serum immunoglobulin E levels. Dermatol Ther (Heidelb). 2024;14:2427–41.
103. Harb H, Chatila TA. Mechanisms of dupilumab. Clin Exp Allergy. 2020;50:5–14.
104. Muñoz-Bellido FJ, Moreno E, Dávila I. Dupilumab: a review of present indications and off-label uses. J Investig Allergol Clin Immunol. 2022;32:97–115.
105. Maurer M, Casale TB, Saini SS, Ben-Shoshan M, Giménez-Arnau AM, Bernstein JA, et al. Dupilumab in patients with chronic spontaneous urticaria (LIBERTY-CSU CUPID): two randomized, double-blind, placebo-controlled, phase 3 trials. J Allergy Clin Immunol. 2024;154:184–94.
106. Olbrich H, Sadik CD, Ludwig RJ, Thaçi D, Boch K. Dupilumab in inflammatory skin diseases: a systematic review. Biomolecules. 2023;13:634.
107. Eggel A, Pennington LF, Jardetzky TS. Therapeutic monoclonal antibodies in allergy: targeting IgE, cytokine, and alarmin pathways. Immunol Rev. 2024, http://dx.doi.org/10.1111/imr.13380. Epub ahead of print.
108. Gomułka K, Tota M, Laska J, Gojny K, Sędek Ł. Serum concentration of Il-5 receptor (Il-5r) and associations with disease severity in patients with chronic spontaneous urticaria (CSU) and atopic dermatitis (AD). Int J Mol Sci. 2024;25:7598.
109. Kay AB, Ying S, Ardelean E, Mlynek A, Kita H, Clark P, et al. Elevations in vascular markers and eosinophils in chronic spontaneous urticarial weals with low-level persistence in uninvolved skin. Br J Dermatol. 2014;171:505–11.
110. Antonicelli L, Tontini C, Garritani MS, Piga MA, Bilò MB. Efficacy of mepolizumab in patients with severe eosinophilic asthma and concomitant severe chronic urticaria: an example of personalized medicine? J Investig Allergol Clin Immunol. 2023;33:54–6.
111. Sluzevich J. Mepolizumab for the treatment of chronic spontaneous urticaria [Internet]. Jacksonville (FL): Mayo Clinic; 2019 [updated 2025 Feb 27; cited 2024 Oct 19]. Available from: https://clinicaltrials.gov/study/NCT03494881?cond=chronic spontaneous urticaria&intr=Mepolizumab&rank=1#study-overview.
112. Bernstein JA, Singh U, Rao MB, Berendts K, Zhang X, Mutasim D. Benralizumab for chronic spontaneous urticaria. N Engl J Med. 2020;383:1389–91.
113. Altrichter S [updated 2024 Mar 13; cited 2024 Oct 19]. Available from: https://clinicaltrials.gov/study/NCT04612725?tab=r, 2020.
114. Dos Santos JC, Azor MH, Nojima VY, Lourenço FD, Prearo E, Maruta CW, et al. Increased circulating pro-inflammatory cytokines and imbalanced regulatory T-cell cytokines production in chronic idiopathic urticaria. Int Immunopharmacol. 2008;8:1433–40.
115. Atwa MA, Emara AS, Youssef N, Bayoumy NM. Serum concentration of IL-17, IL-23 and TNF-α among patients with chronic spontaneous urticaria: association with disease activity and autologous serum skin test. J Eur Acad Dermatol Venereol. 2014;28:469–74.
116. Sabag DA, Matanes L, Bejar J, Sheffer H, Barzilai A, Church MK, et al. Interleukin-17 is a potential player and treatment target in severe chronic spontaneous urticaria. Clin Exp Allergy. 2020;50:799–804, http://dx.doi.org/10.1111/cea.13616.
117. Bonnekoh H, Kiefer L, Buttgereit T, Kolkhir P, Lütke-Eversloh M, Scheffel J, et al. Anti-IL-23 treatment with tildrakizumab can be effective in omalizumab-refractory chronic spontaneous urticaria: a case series. J Allergy Clin Immunol Pract. 2023;11:2578–80.e1.
118. Menzies-Gow A, Corren J, Bourdin A, Chupp G, Israel E, Wechsler ME, et al. Tezepelumab in adults and adolescents with severe, uncontrolled asthma. N Engl J Med. 2021;384:1800–9.
119. INCEPTION STUDY. In: Study to evaluate tezepelumab in adults with chronic spontaneous.s urticaria [Internet]. Thousand Oaks (CA): Amgen; 2021 [updated 2025 Apr 9; cited 2024 Oct 26]. Available from: https://clinicaltrials.gov/study/NCT04833855?cond=Chronic%20Spontaneous%20Urticaria&intr=Tezepelumab&rank=1
120. Mendes-Bastos P, Brasileiro A, Kolkhir P, Frischbutter S, Scheffel J, Moñino-Romero S, et al. Bruton's tyrosine kinase inhibition–an emerging therapeutic strategy in immune-mediated dermatological conditions. Allergy. 2022;77:2355–66.
121. Kaul M, End P, Cabanski M, Schuhler C, Jakab A, Kistowska M, et al. Remibrutinib (LOU064): a selective potent oral BTK inhibitor with promising clinical safety and pharmacodynamics in a randomized phase I trial. Clin Transl Sci. 2021;14:1756–68.
122. Maurer M, Berger W, Giménez-Arnau A, Hayama K, Jain V, Reich A, et al. Remibrutinib, a novel BTK inhibitor, demonstrates

promising efficacy and safety in chronic spontaneous urticaria. J Allergy Clin Immunol. 2022;150:1498–506.
123. Jain V, Giménez-Arnau A, Hayama K, Reich A, Carr W, Tillinghast J, et al. Remibrutinib demonstrates favorable safety profile and sustained efficacy in chronic spontaneous urticaria over 52 weeks. J Allergy Clin Immunol. 2024;153:479–86.
124. La Roche H [cited 2024 Oct 26]. Available from: https://clinicaltrials.gov/study/NCT03137069?tab=results, 2020.
125. Metz M, Sussman G, Gagnon R, Staubach P, Tanus T, Yang WH, et al. Fenebrutinib in H_1 antihistamine-refractory chronic spontaneous urticaria: a randomized phase 2 trial. Nat Med. 2021;27:1961–9.
126. Wollam J, Solomon M, Villescaz C, Lanier M, Evans S, Bacon C, et al. Inhibition of mast cell degranulation by novel small molecule MRGPRX2 antagonists. J Allergy Clin Immunol. 2024;154:1033–43.
127. Fujisawa D, Kashiwakura J, Kita H, Kikukawa Y, Fujitani Y, Sasaki-Sakamoto T, et al. Expression of Mas-related gene X2 on mast cells is upregulated in the skin of patients with severe chronic urticaria. J Allergy Clin Immunol. 2014;134:622–33.
128. ESCIENT PHARMACEUTICALS. In: Phase 2, multicenter, randomized, double-blind, placebo-controlled study to evaluate the effects of EP262 in subjects with chronic spontaneous urticaria (CALM-CSU) [Internet]. San Diego (CA): Escient Pharmaceuticals, Inc; 2023 [updated 2025 Mar 28; cited 2024 Oct 26]. Available from: https://clinicaltrials.gov/study/NCT06077773
129. Wedi B. Inhibition of KIT for chronic urticaria: a status update on drugs in early clinical development. Expert Opin Investig Drugs. 2023;32:1043–54.
130. Muñoz M, Kocatürk E, Maurer M, Kolkhir P. Emerging therapeutics in chronic urticaria. Immunol Allergy Clin North Am. 2024;44:517–28.
131. Maurer M, Kobielusz-Gembala I, Mitha E, Leflein J, Gotua M, Kwiek B, et al. Barzolvolimab significantly decreases chronic spontaneous urticaria disease activity and is well tolerated: top line results from a phase 2 trial. J Allergy Clin Immunol. 2024;153:AB366, http://dx.doi.org/10.1016/j.jaci.2023.11.873.
132. Terhorst-Molawi D, Hawro T, Grekowitz E, Kiefer L, Merchant K, Alvarado D, et al. Anti-KIT antibody, barzolvolimab, reduces skin mast cells and disease activity in chronic inducible urticaria. Allergy. 2023;78:1269–79.
133. CELLDEX THERAPEUTICS. In: A phase 3 study of barzolvolimab in participants with chronic spontaneous urticaria (SCSU) [Internet]. Phillipsburg (NJ): Celldex Therapeutics; 2024 [updated 2025 Apr 11; cited 2024 Oct 16]. Available from: https://clinicaltrials.gov/search?cond=Chronic%20Spontaneous%20Urticaria&intr=barzolvolimab
134. JASPER THERAPEUTICS. In: Dose escalation trial of safety, pharmacokinetic/pharmacodynamic and preliminary clinical activity of briquilimab in adult patients with chronic spontaneous urticaria (CSU) (BEACON) [Internet]. Redwood City (CA): Jasper Therapeutics; 2023 [updated 2025 Feb 04; cited 2024 Oct 26]. Available from: https://clinicaltrials.gov/study/NCT06162728?cond=Chronic%20Spontaneous%20Urticaria&intr=Briquilimab&rank=1
135. Metz M, Kolkhir P, Altrichter S, Siebenhaar F, Levi-Schaffer F, Youngblood BA, et al. Mast cell silencing: a novel therapeutic approach for urticaria and other mast cell-mediated diseases. Allergy. 2024;79:37–51.
136. Schanin J, Korver W, Brock EC, Leung J, Benet Z, Luu T, et al. Discovery of an agonistic Siglec-6 antibody that inhibits and reduces human mast cells. Commun Biol. 2022;5:1226.
137. Lee C [updated 2024 Sep 27; cited 2024 Oct 26]. https://clinicaltrials.gov/search?intr=NCT05528861, 2022.
138. ALLAKOS. In: Study to assess the safety, tolerability, pharmacokinetics and immunogenicity of AK006 in healthy subjects and subjects with chronic spontaneous urticaria [Internet]. Redwood City (CA): Allakos; 2023 [updated 2025 Jan 29; cited 2024 Oct 26]. Available from: https://clinicaltrials.gov/search?intr=NCT06072157

SOCIEDADE BRASILEIRA DE DERMATOLOGIA

Anais Brasileiros de Dermatologia

www.anaisdedermatologia.org.br

REVIEW

Phenol in dermatology: updated evidence on efficacy and safety

Carolina Reato Marçon

Service of Dermatology, Santa Casa de São Paulo, São Paulo, SP, Brazil

Received 9 December 2024; accepted 12 May 2025
Available online 25 August 2025

KEYWORDS
Chemical face peeling;
Croton oil;
Phenol;
Rejuvenation;
Substance-related disorders

Abstract Phenol, or carbolic acid, is an organic compound with caustic and antiseptic properties widely used in dermatology. Since its introduction as an antiseptic in the 19th century, its use has expanded to various areas of medicine, including the treatment of dermatological conditions such as vitiligo, warts, guttate leukoderma, hidradenitis suppurativa, angiosarcoma, acne scars, alopecia areata, onychocryptosis, and actinic keratoses. In deep peels, phenol stands out for its effectiveness in skin rejuvenation, promoting intense and sustained neocollagenesis, with unparalleled results. Its ability to alter dermal structure makes it an essential therapeutic tool in various dermatological approaches. However, its use requires extreme caution due to its rapid cutaneous absorption and unique toxicokinetic profile. The substance can induce serious complications, such as cardiac arrhythmias, renal failure, neurotoxicity, and multiple organ failure, especially when applied to large areas or with inadequate techniques and formulations. Historical and contemporary studies report cases of fatal poisoning due to cutaneous exposure to phenol, highlighting the need for strict precautions in its use. To minimize these risks, it is essential that procedures be performed by highly trained physicians, with constant monitoring and controlled application, to ensure safety and maximize the therapeutic benefits of this substance, whose efficacy is widely recognized.

Introduction

Phenol, or carbolic acid, is an organic compound derived from benzene, known for its caustic and antiseptic properties. Discovered in 1834 by Friedrich Ferdinand Runge through its isolation from coal tar, its clinical use began to gain prominence in the 19th century, when British surgeon Joseph Lister introduced it as an antiseptic in 1865. Based on Louis Pasteur's discoveries about the germ theory of disease, Lister applied phenol to clean wounds and surgical

Note: In Brazil, the use of phenol in aesthetic procedures is temporarily prohibited by Resolution RE No. 2,384 of June 25, 2024, published by the National Health Surveillance Agency (Anvisa), following the report of a death resulting from a phenol peel performed by a layperson. The case was the subject of detailed forensic analysis, recently published: (Marçon CR et al. J Am Acad Dermatol. 2025; https://doi.org/10.1016/j.jaad.2025.05.1461). The revocation of the ban is currently under review by the regulatory agency.

E-mail: carolrmarcon@hotmail.com

https://doi.org/10.1016/j.abd.2025.501200

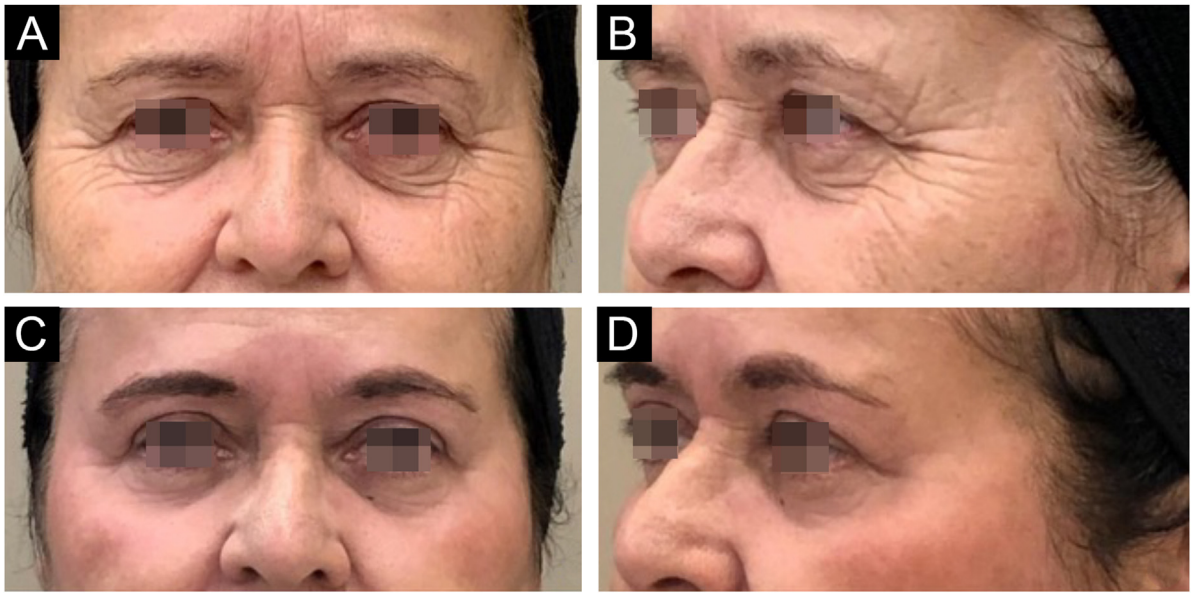

Figure 1 59-year-old patient, before (A and B) and after (C and D) 6 months of phenol-croton 35%/1.2% peeling for rejuvenation of the periocular region.

instruments, revolutionizing medical practice by substantially reducing postoperative infection rates.[1]

Since its introduction into medicine, phenol has established itself as a versatile therapeutic agent with wide-ranging applications, especially in dermatology. In deep peels, it stands out for its effectiveness in skin rejuvenation and the treatment of acne scars,[2,3] offering significant clinical results (Figs. 1 and 2). Furthermore, phenol has therapeutic indications in a variety of dermatological conditions, including vitiligo,[4] guttate leukoderma,[5] common warts,[6] melasma,[7] actinic cheilitis,[8] actinic keratoses, and Bowen's disease.[9] With the advancement of medical practices, its use has expanded to other areas, such as in the treatment of onychocryptosis, where it acts as a sclerotizing agent, promoting the selective destruction of the nail matrix,[10] in the management of pilonidal cysts[11] and minor dermatological surgical procedures.[12] Phenol has also demonstrated efficacy in inflammatory and proliferative conditions, such as hidradenitis suppurativa[13] and keloids.[14] The extent of its applications, combined with consistent therapeutic results, makes phenol a valuable resource in dermatology, meeting a diversity of clinical demands with high efficacy.

Despite the remarkable results achieved with phenol, both in aesthetic treatments and in other areas of dermatology, its use carries significant risks. Phenol systemic toxicity can lead to serious complications, such as cardiac arrhythmias and renal failure.[15–17] Therefore, it is imperative that procedures involving this substance be performed exclusively by trained physicians and in controlled environments.

The objective of this review is to explore the main indications for phenol in dermatology, critically analyzing its therapeutic applications, efficacy, and potential risks. Furthermore, it seeks to emphasize the importance of a careful and safe approach to the use of this substance, highlighting the need for technical training and rigorous monitoring to ensure clinical efficacy and patient safety.

Mechanism of Action, Toxicokinetics, and Metabolism

Mechanism of Action

Phenol is a flammable and highly corrosive organic acid that is readily absorbed and widely distributed through all routes of exposure, including inhalation, cutaneous, and oral exposure. The substance has hydrophilic and lipophilic properties, which facilitate its penetration through cell membranes. Phenols denature and precipitate cell proteins, resulting in coagulation necrosis.[17]

On the skin, the substance has an immediate caustic effect, promoting the denaturation and coagulation of epidermal keratin proteins and the superficial layers of the dermis, clinically translated as rapid, uniform whitening (Fig. 3). Its caustic effect results in deep dermal remodeling, stimulating the production of collagen and elastin. This mechanism is widely explored in aesthetic procedures, such as facial rejuvenation, due to its ability to promote structural skin renewal with long-lasting results.[18]

Absorption and Toxicokinetics

Phenol absorption into the bloodstream after cutaneous application is intense and rapid, with urinary recovery of 70% within 30 minutes and 85%–95% within 24 hours.[17,19] Even small amounts can reach significant serum levels, making strict dose control and the use of targeted application techniques essential.[16]

Studies indicate that cutaneous absorption is little influenced by the concentration of the applied solution but depends largely on the area of exposed skin.[20] In 1971, Piotrowski studied solutions containing phenol at concentrations of 5, 10, and 25 mg/m^3 and found that, regardless

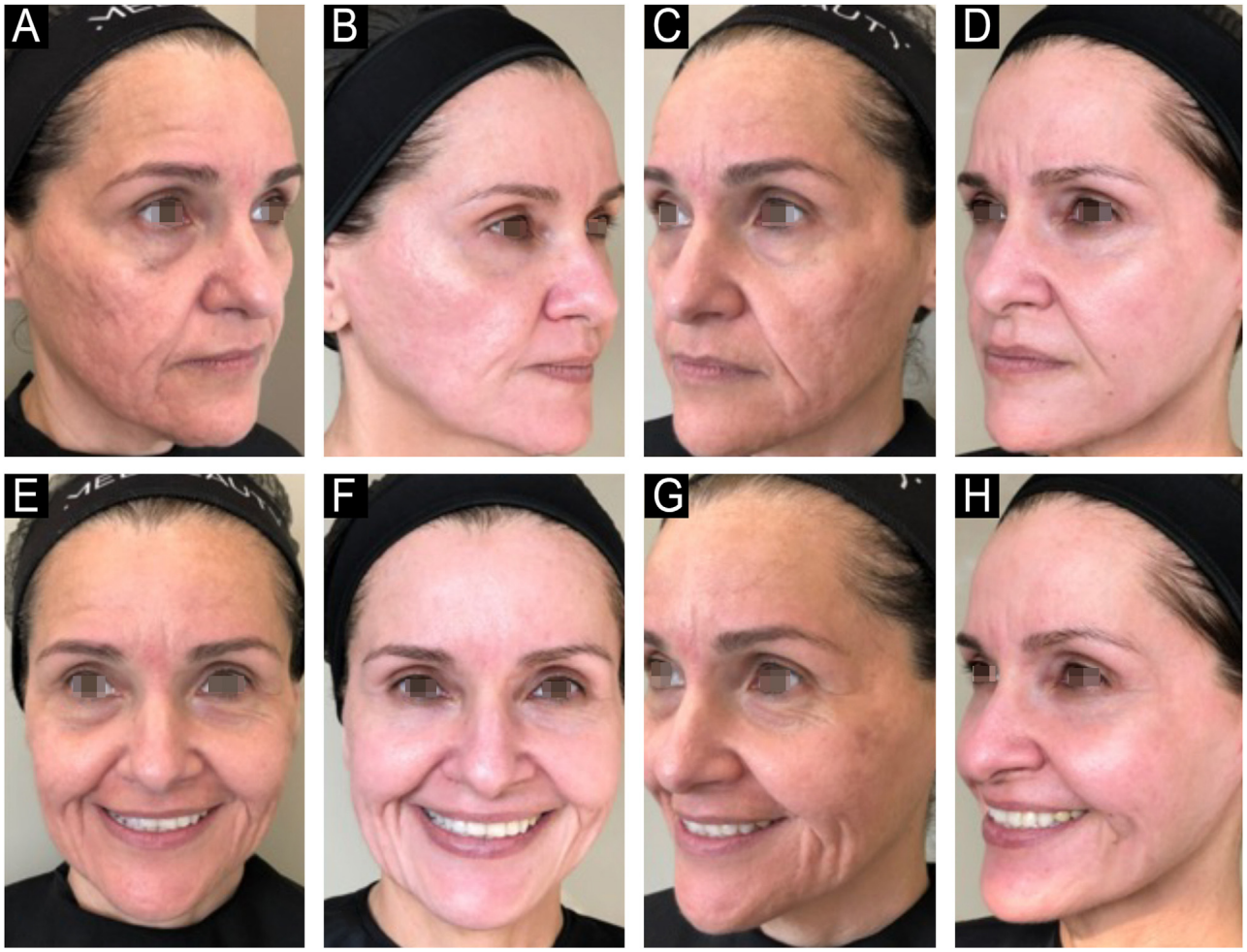

Figure 2 50-year-old patient, before and after one year: A and B (right hemiface); C and D (left hemiface); E and F (frontal face); G and H (right hemiface smiling), phenol-croton peeling 35%/1.6% for the treatment of acne scars and photoaging.

of concentration, the compound is rapidly absorbed through both the skin and the lungs.[21]

Metabolism and Elimination

When applied to the skin, phenol is rapidly absorbed due to its lipophilic nature and low molecular weight, penetrating the stratum corneum and reaching the systemic circulation. Once absorbed, it undergoes hepatic detoxification, where approximately 75% is metabolized primarily by glucuronidation, sulfonation, and oxidation via CYP2E1. Elimination occurs predominantly through the kidneys, being excreted in the urine mainly in the form of glucuronides and sulfates. Approximately 25% of the phenol undergoes further metabolism, being converted to carbon dioxide (CO_2) and water, while a small fraction may be excreted unchanged in the urine. Furthermore, in the first few minutes after absorption, some of the phenol may be eliminated through the lungs, which may be associated with the characteristic odor exhaled by patients. A smaller fraction of the phenol is eliminated in the feces, resulting from the biliary excretion of metabolites, although this pathway plays a secondary role in the total elimination of the compound. The half-life of phenol varies depending on the dose and route of exposure, but its efficient renal elimination generally prevents accumulation in healthy individuals. Therefore, adequate hydration and stimulating diuresis are interesting strategies to optimize its elimination. Furthermore, because respiratory, urinary, and biliary excretion occur relatively quickly, it is essential to maintain adequate intervals between successive applications in cosmetic units, ensuring complete elimination before further exposure.[19,20]

Dermatological Applications of Phenol

Vitiligo

Studies report the use of 88% phenol for depigmentation of residual skin in advanced cases of vitiligo.[4,22] When applied topically in high concentrations, the substance has melanotoxic action, causing chemical necrosis of melanocytes. This toxic action on melanocytes compromises melanin synthesis in the treated areas, leading to permanent depigmentation and color uniformity. This effect is particularly useful in patients with generalized vitiligo, in whom repigmentation is unfeasible or unsatisfactory.[4]

Figure 3 Uniform frosting that sets in quickly after applying phenol to the skin, resulting from the denaturation and coagulation of the proteins in the epidermal keratin and the superficial layers of the dermis.

A study published in the *Anais Brasileiros de Dermatologia* in 2005 reported the case of a 62-year-old patient with generalized vitiligo and residual normal-colored areas on the neck who was treated with 88% phenol. After two applications, 45 days apart, the pigmented areas were completely eliminated, with no signs of repigmentation after 18 months.[22]

Guttate Hypomelanosis

A study by Ravikiran et al.[5] evaluated the use of 88% phenol in the treatment of idiopathic guttate hypomelanosis. The compound promoted controlled chemical necrosis in the hypopigmented areas, triggering a local regenerative response that led to progressive repigmentation of the lesions. Twenty patients with 139 macules were treated with two monthly applications of 88% phenol. After three months, 64% of the macules showed repigmentation, with 45% showing greater than 75% improvement.

Vulgar Wart

A study compared the efficacy of cryotherapy with liquid nitrogen to 80% phenol in the treatment of hand warts. Sixty patients were randomly divided into two groups and treated weekly for up to six weeks. At the end, 70% of the patients treated with cryotherapy and 82.6% of those treated with phenol achieved complete healing, with no statistically significant difference between the methods.[6]

Another study compared the efficacy of curettage and electrocoagulation with the application of 80% phenol in the treatment of warts. The treatments were performed simultaneously on different lesions of the same patient, in 17 patients. After six weeks, the cure rate was significantly higher in the curettage and electrocoagulation group (100%) compared to the phenol group (65%). The study concluded that curettage and electrocoagulation were more effective, but the application of phenol may be a less invasive alternative for pain-sensitive patients.[23]

Hidradenitis Suppurativa

A study evaluated the use of crystallized phenol in the treatment of sacral hidradenitis suppurativa (HS). Twenty-five patients were treated with phenol, with a mean follow-up of 36.8 months. The oozing openings were dilated with forceps after local anesthesia, the hairs were removed, and phenol was applied. The cure rate was achieved in 60% of cases, with recurrence in 40%, most of which resolved with reapplications. The treatment showed a significant reduction in Hurley severity scores and Physician's Global Assessment of

HS after therapy, with no reported side effects. Crystallized phenol has proven to be an effective, minimally invasive option with little impact on patients' daily lives.[13]

A recently published pilot study (2024) evaluated the efficacy and safety of phenolization in the treatment of hidradenitis suppurativa (HS). After local anesthesia and individualization of the fistulas, 88% phenol was applied (three passes with a soaked cotton swab) to 22 fistulas in 12 patients, resulting in significant improvement in more than half of the cases after one month, with healing within two weeks. The technique proved particularly useful in anatomical areas that are difficult to manage surgically and in small, non-draining fistulas. Tolerance was good, with mild and transient side effects.[24]

Pilonidal Cyst

Phenol has been used in the treatment of pilonidal cysts due to its sclerotizing and antimicrobial properties. The application aims to destroy the cyst epithelium, promoting obliteration of the tract and reducing disease recurrence. Numerous studies indicate that the use of phenol, in crystallized or 80% liquid form, is an effective alternative for the treatment of pilonidal cysts.[25]

Dogru et al.[25] evaluated the impact of crystallized phenol on the outpatient treatment of pilonidal disease in 41 patients. The substance was applied 107 times, with most patients (70%) requiring two to three applications. The average recovery time was 42.7 days, with a 95% success rate, and only two recurrences were observed after five and eight months.

A literature review on the use of phenol as a minimally invasive method for the treatment of pilonidal disease revealed a mean time to return to work of 2.3 days and a healing time of 20 days. The overall success rate was 87%, with a mean follow-up of two years. The most common complications were abscess and cellulitis, with a mean incidence of 8.9%.[26]

A meta-analysis published (2024) compared phenolization with surgical excision in the treatment of pilonidal cysts. The analysis included 14 studies, including five randomized controlled trials and nine non-randomized trials. Phenol treatment showed fewer complications, shorter surgical time (mean 22.76 minutes), faster return to daily activities (mean 10.11 days), and shorter healing time (mean 17.11 days) compared to surgical treatment.[27]

Mucocele

Sacchidanand et al.[12] evaluated the use of 88% phenol in the treatment of mucous cysts. Four patients were treated with intralesional phenol injection, without the need for local anesthesia. After application, ulceration of the lesions was observed, followed by complete healing within two weeks. The absence of intraoperative or postoperative bleeding, minimal surgical defects, and discreet healing offered an advantage to phenol over surgery.[12]

Premalignant Lesions and Cutaneous Neoplasms

A prospective study evaluated the efficacy and prognostic relevance of 100% phenol peels in patients with actinic keratoses (AK) and Bowen's disease (BD) using clinical, histological, and immunohistochemical criteria. Forty-six patients (32 with AK and 14 with BD), aged 31 to 91 years, were included. Applications were performed monthly for up to eight sessions, and patients were monitored for at least one year after treatment. There was a complete response in 84.8% of cases. Success rates correlated with factors such as tumor thickness and expression of molecular markers (PCNA and cyclin A).[9]

A recent study (2024) compared the efficacy of phenol-croton peeling (Hetter 35%/1.6%) versus imiquimod 5% in the treatment of actinic cheilitis. Thirty-six patients were randomized into two groups: one received imiquimod 5% three times a week for 30 days, and the other received a single phenol-croton peeling session. At 56 days, 94% of patients treated with phenol-croton showed complete clearing of the lesions, compared to none in the imiquimod group ($p < 0.01$). Histological and clinical improvements were more significant in the phenol-croton group. Despite more intense initial adverse effects, the peeling proved to be superior in efficacy and recovery.[8]

A study by Kaminaka et al.[28] evaluated the use of 100% phenol in the treatment of cutaneous angiosarcoma (AS) in three cases. After treatment, biopsies revealed severe degeneration of the tumor and endothelial cells in the dermis, with positive staining using the TUNEL (Terminal Deoxynucleotidyl Transferase dUTP Nick-End Labeling) method, a technique that detects DNA fragmentation associated with apoptosis. Phenol peeling demonstrated advantages such as simplicity, speed, low cost, manageable pain, and sustained efficacy, suggesting its use as a complementary therapy for AS.

Alopecia Areata

Studies have explored the use of phenol as a therapeutic option for alopecia areata. The proposed mechanism of action involves stimulating hair follicles through growth factors and cytokines released in response to necrosis and inflammation. Furthermore, it is suggested that phenol may act directly on the germinal centers of follicles, promoting hair growth.[29,30]

A study evaluated the efficacy of 88% phenol in 50 patients with stable alopecia areata, applying it every three weeks. Approximately 78% of patients showed a good to excellent response. There was a significant improvement in hair texture and pigmentation within nine weeks, with a progressive increase in hair density.[29]

A report by Kar and Singh[30] described a 13-year-old patient with diffuse alopecia areata involving more than 50% of the scalp who was treated with five biweekly sessions of 88% phenol and four biweekly pulses of intravenous dexamethasone. The phenol induced controlled inflammation and hair regeneration, while the dexamethasone modulated immunity. After 4 months, there was significant terminal hair growth, with no recurrence within 6 months.[30]

Keloid

Mseddi et al.[14] investigated the use of 40% phenol in the treatment of keloids in 25 patients. The mean age of parti-

cipants was 37.7 years, with a predominance of phototype IV (64%) and lesions located on the trunk (48%). After an average of 14.2 sessions, a 75.5% reduction in lesion size was observed, with 72% of patients reporting satisfaction with the treatment and 81% adhering to the protocol. There were no recurrences during the average follow-up of 12.8 months. The authors highlighted that the induction of controlled tissue necrosis promoted scar remodeling, improving skin texture and color.[14]

Dark Circles

Platsidaki et al.[31] evaluated the combination of 10% phenol and 20% trichloroacetic acid in the treatment of dark circles in 31 women. The peeling was applied with a cotton swab in three layers to the upper and lower eyelids until a homogeneous frosting endpoint was reached. The treatment showed significant improvement, especially in younger patients. The authors suggested that the combination of the two substances offers complementary mechanisms of action, providing effective cosmetic benefits without the potential adverse effects associated with the use of higher concentrations of each compound alone.[31]

A retrospective study analyzed the efficacy and safety of deep chemical peels in the treatment of constitutional dark circles. Fifty-five procedures were performed on 52 patients, mostly women (92%), with a mean age of 46 years and Fitzpatrick phototypes III–IV (89%). In most cases, a phenol formula (60%–65%) combined with croton oil (0.6–0.7%) was used. The results showed that 89% of patients experienced clinical improvement greater than 50%, with an average duration of benefits of 24 months. Furthermore, 69% maintained satisfactory results until the last follow-up. Complications were rare, with only 4% of cases presenting persistent erythema, without the development of scars.[32]

Melasma

A recent (2024) retrospective cohort study[7] compared phenol peeling with moderate concentrations of Croton Oil (CO; 0.7–0.9%) versus higher concentrations (1.1–1.6%) in the treatment of recalcitrant melasma. Both groups showed significant improvement in mMASI after treatment and high scores on the Global Aesthetic Improvement Scale. However, the reduction was more pronounced in the group with CO < 1% compared to the group with CO > 1%. Remission was maintained for more than a year in 85% of cases, with no relevant differences between concentrations. The sustained improvement in melasma was attributed to the long-lasting treatment of elastosis, considered an important etiopathogenic substrate of melasma (Fig. 4). However, additional studies with larger sample sizes and longer follow-up are needed to confirm the stability of these results across different phototypes and clinical conditions.

Onychocryptosis

Originally developed in 1945 by Boll,[33] phenolization is one of the best-documented techniques in the medical literature for the treatment of onychocryptosis. Hundreds of studies, including extensive case series, demonstrate its safety and efficacy. Phenol acts as a sclerotizing agent, selectively destroying the nail matrix. Its benefits include a low recurrence rate, its antiseptic and analgesic properties, and the low risk of infection associated with the procedure.

A study published in 2024 analyzed the recurrence rate after partial matricectomy with 88% phenol, using a contact time of 45 seconds. A total of 1,460 surgeries were performed, with 802 patients followed for a six-month period. The recurrence rate was 0.75% at three months and 1.87% at six months.[10]

A retrospective study by Andreassi et al.[34] analyzed 948 phenol cauterizations in 764 patients. There was no significant morbidity, and the procedure was well tolerated by all patients. The overall recurrence rate was 4.3% after 18 months. All recurrences were successfully treated with repeat application of the substance.

Other studies[35,36] corroborate these low recurrence rates, indicating consistency in the results. Furthermore, Cochrane reviews[37,38] and a recently published meta-analysis by Vinay et al. (2022)[39] confirmed the efficacy and safety of phenolization, with minimal side effects.

Acne Scars

The efficacy of phenol in the treatment of acne scars, with particularly notable benefits in deeper scars resistant to other procedures (Fig. 5), has been demonstrated in several studies. Mackee and Karp[40] pioneered the use of phenol for acne scars, documenting its effectiveness in softening atrophic scars, a finding that supported the use of phenol decades later. Leheta et al.[41] conducted a randomized clinical trial comparing a 60% phenol peel with croton (Skintech Inc., Spain) to Percutaneous Collagen Induction (PCI) combined with 20% Trichloroacetic Acid (TCA) treatment for post-acne atrophic scars. Twenty-four patients were divided into two groups, with Group 1 receiving one session of phenol peel and Group 2 four sessions of PCI with TCA. Both treatments resulted in significant improvement in scars, with the phenol peel showing slightly superior results, with an average improvement of 75.12% in Group 1 and 69.43% in Group 2.

Recent studies by Rullan and Rullan (2024)[3,42] explored the use of phenol in CROSS procedures (a technique of applying acids to individual scars) and in ring paint for boxcar and polymorphic scars. They observed that localized application of 89% phenol was effective, providing satisfactory results in improving scar texture and depth.

Photoaging

Several studies have analyzed the efficacy of phenol peels in the rejuvenation of photoaged skin, especially in combination with croton oil[2,43,44] (Fig. 6). Butler et al.[45] and Giese et al.[46] showed that these peels significantly improve skin quality by stimulating the remodeling of elastic tissue. Hetter[47] investigated phenol and croton oil formulas at various concentrations, highlighting the safety and efficacy of the procedure. Han et al.[48] confirmed the rejuvenating effects in animal studies, while Kligman et al.[18] performed

Figure 4 63-year-old patient with refractory melasma, before and after 6 months: A and B (frontal face); C and D (left hemiface), phenol-croton peeling 35%/1.2%.

histopathological analysis on skin biopsies from patients who had undergone peeling up to 20 years earlier, revealing the long-lasting effects of the procedure.

A recent study by Cardoso et al. (2022)[44] evaluated 30 women with Glogau III–IV photoaging, showing that 87% achieved significant rejuvenation (Glogau I–II) three months after the peeling with 35% phenol and 1.2% croton oil. Another split-face study, conducted by Neitzke et al.[43] compared the hemifaces of 48 patients. After six months, 79% showed rejuvenation of two or more points on an eight-point photonumeric scale, with a median improvement of three points ($p < 0.0001$). Another split-face study, which compared the classic Baker-Gordon peel (2.1% croton oil/50%

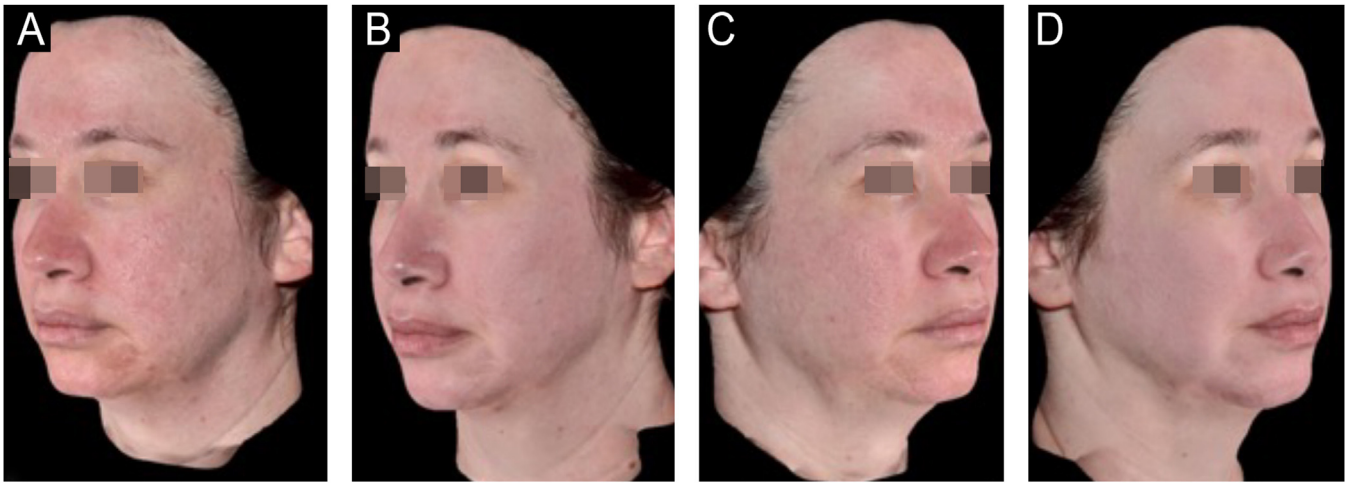

Figure 5 38-year-old patient with acne scars unresponsive to previous treatments (dermabrasion/CO2 laser), before and after 1 year: A and B (left hemiface); C and D (right hemiface), phenol-croton peeling 35%/1.2%.

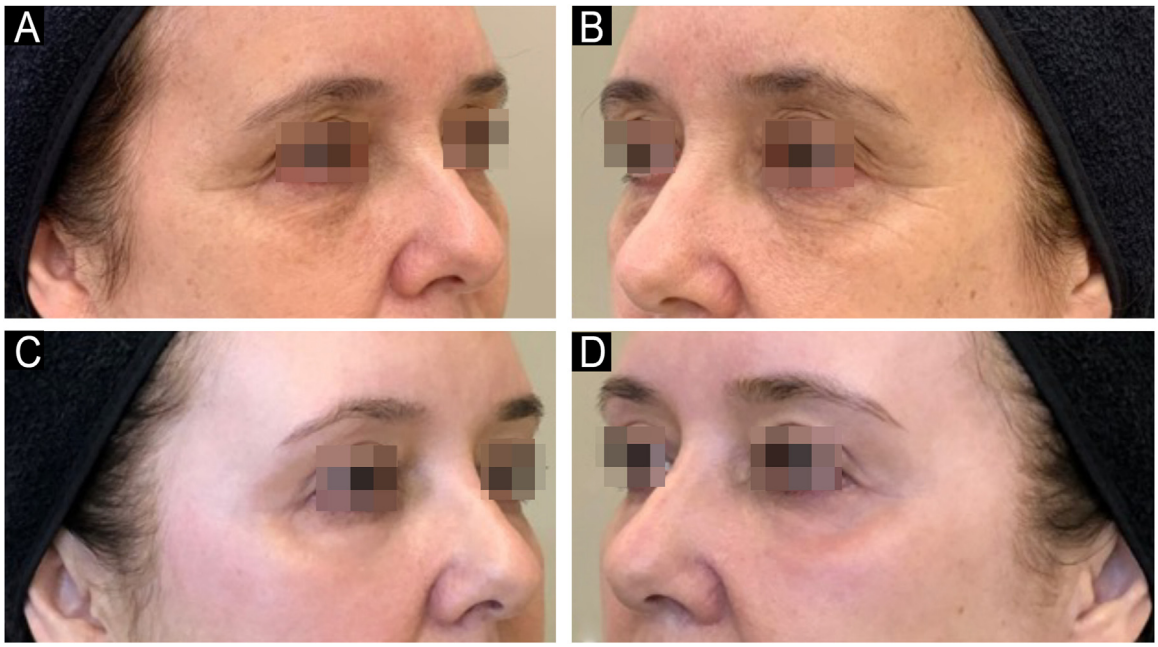

Figure 6 Rejuvenation of the periocular region with phenol-croton peeling 35%/1.2% in a 58-year-old patient. Before (A and B) and after (C and D) 6 months: A and C (right hemiface); B and D (left hemiface).

phenol) and a modified Hetter formula (0.7% croton oil/33% phenol), showed similar efficacy, but with fewer side effects in the Hetter formula.[49]

Other dermatological indications

Other therapeutic proposals include the treatment of oral leukoplakia, in which topical application of phenol prevented progression to malignancy,[50] the treatment of hyperhidrosis, in which phenol is used for sympathectomy by chemical neurolysis,[51] or as an alternative to the treatment of pyogenic granuloma.[52]

A literature review demonstrated that, outside the aesthetic context of deep peels, the use of phenol in other dermatological indications did not produce significant systemic adverse events. Reported complications were predominantly local, such as persistent erythema, burning sensation, scarring, and dyschromia. Phenol treatment has emerged as a simple, accessible, safe, and effective approach, with applications in a variety of dermatological conditions. Its use in small quantities reduces the risk of excessive systemic absorption and potential serious adverse effects, reinforcing its viability in well-conducted clinical practices.

Phenol-Croton Peel

Before its formal adoption by physicians for cosmetic purposes, phenol-croton peeling was used empirically by laypeople in the early 20th century. In the United States, aes-

Figure 7 Day-by-day evolution (A-H), PO 1 to 8, from left to right horizontally, of the post-phenol-croton peel. Edema, intense neutrophilic inflammation, and removal of the outermost layers of the skin, replaced by rejuvenated and supple skin. Combined with phenol, croton oil enhances the penetration of the compound and acts synergistically on the production of collagen and elastin, providing more effective results. Post-procedure erythema may persist for up to 6 months.

theticians applied phenol solutions to remove wrinkles and facial blemishes, believing in its potential to ''rejuvenate'' the skin. However, this unregulated and unsupervised use often resulted in serious complications, infections, and permanent scarring.[53]

This scenario persisted for several decades, and the excellent but inconsistent results, in addition to the severe risks, caught the attention of physicians, who became interested in studying and controlling the use of the substance. Dr. Thomas Baker was one of the pioneers in formalizing the use of the substance in the aesthetic context. Along with his collaborator Howard Gordon, Baker dedicated himself to transforming the empirical use of phenol into a safe and scientifically based technique. The pair developed rigorous protocols to control peel depth and reduce complications, which resulted in the establishment of phenol peels as a medical procedure. The first scientific publication detailing the use of a combination of phenol and croton oil for cosmetic purposes appeared in 1961, laying the foundation for the understanding and refinement of the technique.[54]

Baker published his first formula with 47.5% phenol combined with 1.2% croton oil, adjusting it the following year to 2.1% croton oil.[54,55] In the 2000s, Hetter introduced variations on Baker's original formula, proving that the main agent in deepening the peel was croton oil and proposing fixing the phenol concentration at 35% and reducing and titrating the croton oil concentrations, ranging from 0.4% to 1.6%, in order to control the intensity of the peel and improve the safety profile of the procedure.[47]

Croton oil, extracted from the seeds of *Croton tiglium*, is rich in phorbol esters, which have intense pro-inflammatory activity, triggered by the activation of protein kinase C, which generates regenerative responses in the skin, stimulating neocollagenesis. The initial inflammatory response is triggered by the irritant activity of croton oil but is sustained and intensified by the pharmacological action of the plant's secondary metabolites (Fig. 7). These compounds, such as phorbol 12-myristate 13-acetate, induce the formation of a subcoagulative neutrophil band, assumed to be NETosis (programmed neutrophil cell death with release of extra-

cellular DNA structures – Neutrophil Extracellular Traps). Phorbol esters also stimulate the secretion of cytokines by inflammatory cells in the dermis, promoting an increase in TGF-β (transforming growth factor beta) and, consequently, collagen production.[2,56] In combination with phenol, croton oil enhances the penetration of the compound, in addition to acting synergistically on the production of collagen and elastin, providing more effective results.[55] Studies have shown that the combination of phenol with croton oil in the treatment of perioral wrinkles promoted an increase in the expression of SIRT-6 and SIRT-7 sirtuins, responsible for regulating collagen synthesis and protecting the skin against photodamage.[44] Studies in animal models have shown a significant increase in type III collagen within 21 days after the procedure.[56]

Phenol-croton deep chemical peels are widely recognized as a leading technique in skin rejuvenation, offering long-lasting results unmatched by other methods. Robust studies support its efficacy, establishing it as an evidence-based recommendation for the treatment of photoaging. However, along with the evidence of effectiveness, concerns have arisen about the potential systemic risks associated with the procedure. Unlike other phenol applications, which have demonstrated safety under appropriate medical supervision, phenol-croton peeling is widely documented in the literature for its toxicity and potential risks.[57–60]

Systemic Risks and Evidence on Phenol Toxicity

Overview of Systemic Toxicity

Records of phenol toxicity have been reported in the literature since the 19th century. Numerous publications have highlighted the fatal potential of phenol formulations, whether through accidental or therapeutic exposure, via cutaneous, intravenous, oral, or inhalation routes. From the 1940s-61 to the present day, the authors have found publications that address the two antagonistic characteristics of the substance: the excellent effects of cutaneous applications and the serious risks resulting from systemic absorption and toxicity.

Early reports in animal models, such as those by Deichmann et al.[63] point to the serious toxic effects of phenol when absorbed in large quantities, including everything from cardiac alterations to multiple organ failure. Historical reports, such as that by Lucas and Lane[64] described cases of coma after dermal absorption of phenol. In 1922, Turtle and Dolan[65] reported a fatal case in which a bottle containing phenol broke in a young man's pocket on his train ride home. Another case published by Miller in 1942[66] reported an 18-year-old man with ringworm whose housekeeper applied a mixture of phenol and camphor to his shoulders and trunk, resulting in death within 15 minutes. In 2016, Giri et al.,[67] published a report of four cases of acute phenol poisoning in children in India. The cases highlighted the multiple routes of absorption of the substance, as well as its complications in multiple organs. The severity of poisoning was more correlated with dermal exposure than with oral ingestion. The authors concluded that dermal exposure can rapidly progress to multiple organ failure, and that severity appeared to vary according to the degree of dermal exposure and the time interval to intervention.

Cases of dermal exposure to phenol resulting in lethargy and coma, nausea and vomiting, hypotension, cardiac arrhythmias, seizures, intravascular hemolysis, pulmonary edema, tracheal and bronchial inflammation, acidosis, methemoglobinemia, renal dysfunction, and coma have been reported. The reason for the predilection of some organs over others in different patients is unclear.[15,68–70]

Systemic Risks

Central Nervous System. Neurological toxicity from phenol ranges from mild symptoms, such as lethargy, to seizures and coma. Phenol can exert a central narcotic effect, affecting the spinal cord and higher brain centers, producing rapid loss of consciousness and profound collapse.[71]

Griffiths[72] reported a fatal case involving a 23-year-old man accidentally exposed to phenol, who died minutes after dermal contact, highlighting the risk of severe neurological toxicity. A 1900 publication by Abrahams[73] described the case of a 7-day-old baby who was touched in the right groin by a nursemaid with phenol on her fingers. The child died 10 hours later, developing convulsions and a coma.

Cardiovascular System. Phenol can exert direct toxicity on the myocardium, causing cardiac arrhythmias, and on blood vessels, causing hypotension.[58,74] Studies in rats have shown decreased myocardial contraction and electrical activity after systemic exposure to the compound.[75] The most common symptoms of phenol cardiotoxicity are tachycardia, bradycardia, bigeminy, and premature contractions, which can progress to ventricular tachycardia and atrial fibrillation.[58,76]

Sex, age, previous cardiac history, and blood phenol levels were not accurate predictors of susceptibility to cardiac arrhythmia during phenol peeling.[76,77] Several authors agree[58,61,74,78,79] that absorption and cardiac toxicity are primarily influenced by the extent of skin exposed at a given time—and not by the concentration of the phenol solution—and recommend cardiac monitoring, slow and spaced applications, and forced diuresis as safety measures. However, some studies have shown that cardiac alterations were observed even with slow applications.[16]

A study by Truppman and Ellenby[76] investigated the factors associated with the development of cardiac arrhythmias during facial phenol peels, focusing on variables such as procedure duration, size of the treated area, and formulation used. The study demonstrated that peels performed in less than 30 minutes, with 50% or more of the facial area treated, were highly correlated with the occurrence of arrhythmias. The saponified versus non-saponified formulation did not significantly influence the incidence of arrhythmic events, suggesting that the response is more dependent on the rate of phenol absorption than on individual characteristics or the formulation.[76]

Gross[77] reported that 30% of 54 patients treated briefly with phenol peels developed some form of cardiac arrhythmia. Gross further noted that there were no predictable results regarding serum phenol levels and the occurrence of cardiac arrhythmia. However, there appeared to be suggestive evidence that segmented facial peeling, at intervals

that allowed for metabolism and excretion of absorbed phenol, would reduce the risk.[77]

Beeson[80] evaluated 43 consecutive patients who underwent deep peels with phenolic formulations. Ten developed cardiac arrhythmias, including premature ventricular contractions, bigeminy, paroxysmal atrial tachycardia, and ventricular tachycardia, highlighting the need for monitoring to identify and manage these potentially serious complications.[80]

A retrospective study evaluated 181 patients undergoing phenol peels. Patients were monitored multiparametrically throughout the procedure, received potent analgesics, conscious sedation, and intravenous hydration, and the room was adequately ventilated. Cardiac arrhythmia was recorded in 6.6% of patients, being more prevalent in those with diabetes mellitus, hypertension, and depression.[59]

Kadunc and Vanti[16] investigated the systemic toxicity of phenol in facial peels, analyzing 60 women monitored via Holter monitoring and urinary gas chromatography (UGC), in addition to assessments of renal and hepatic function. The study revealed rapid elimination of phenol, with a half-life of 6 to 8 hours, and no significant changes in renal or hepatic function after 30 days. However, four patients experienced sustained ventricular tachycardia, highlighting the risk of cardiac complications. The authors concluded that, although phenol is effective, its use requires strict precautions and continuous monitoring to ensure patient safety.

A recent study by Rullan et al. (2024)[62] evaluated the safety of phenol facial peels in 196 patients undergoing multiparametric monitoring during the procedure. Of the participants, ten (5%) experienced benign and transient arrhythmias: four had premature atrial contractions, two had premature ventricular contractions (one of whom also developed supraventricular tachycardia), and one had sinus tachycardia. One patient with initial sinus bradycardia experienced a temporary reduction in oxygen saturation, and three patients developed hypertension during the procedure. The results highlight the importance of intraoperative monitoring to mitigate cardiac and systemic risks associated with phenol use.[62]

Li et al.[81] reported a fatal case of phenol toxicity in a 21-year-old man after attempting tattoo removal using an idiosyncratic method of subcutaneous injection of a ''tattoo-eliminating solution'' containing phenol at an unknown concentration. The session lasted three hours, after which he suddenly collapsed and died within minutes. There were no signs of underlying organic disease that could have contributed to the death. Toxicology revealed the presence of phenol in cardiac blood and liver tissue. Internal examination revealed pulmonary congestion and edema. Death was attributed to acute phenol-induced cardiotoxicity.

Urinary Tract. The mechanism by which phenol induces kidney damage is not clearly understood. Damage to renal tubular epithelial cells by free radical phenol intermediates, the inability of epithelial cells to form sufficient reduced glutathione to clear these intermediates, damage to the glomeruli by excretion of unconjugated phenol, renal ischemia, cast formation due to hemoglobin precipitation, extensive rhabdomyolysis, and/or hemoglobinuria due to intravascular hemolysis have all been proposed as possible mechanisms.[15,19,82,83] Seak et al.,[82] Foxall et al.[83] and Cohen et al.,[68] have documented cases of renal failure in individuals with dermal exposure to phenol.

Respiratory System. Inhalation of phenol vapors can cause damage to the upper and lower respiratory tract. In more severe cases, inhalation of high concentrations can lead to glottis edema and acute pulmonary edema, serious and potentially fatal conditions. These effects are attributed to the corrosive nature of phenol, which damages the epithelial tissue of the airways and can induce an intense inflammatory response.[19,84]

Although pulmonary toxicity through inhalation is most frequently discussed, dermal absorption of high concentrations can also cause respiratory impairment. The systemic distribution of phenol and its inflammatory action in target tissues, such as the lungs, is primarily responsible for these complications.[19,21,84] Reports have documented cases of dermal and oral exposure to phenol associated with acute pulmonary edema and tracheobronchial inflammation.[68,85] Studies by Fu et al.[86] and Gupta et al.[87] described fibrosing alveolitis and Acute Respiratory Distress Syndrome (ARDS) after phenol exposure, reinforcing the severity of pulmonary impairment, particularly in the absence of adequate ventilatory support.

Liver. Phenol can induce acute hepatotoxicity due to the accumulation of toxic metabolites in the liver, which generate oxidative stress and mitochondrial dysfunction, leading to cell necrosis. Manifestations such as elevated liver enzymes, jaundice, and, in severe cases, liver failure may occur, requiring cautious use in therapeutic settings.[67]

Hematopoietic System. Cases of methemoglobinemia and intravascular hemolysis due to phenol exposure, in which oxygen transport was compromised, resulting in hypoxia and acidosis, have been described.[69,88] These are serious conditions that require immediate identification and intervention.

What is the safe dose of phenol for dermatological use?. Although the literature lacks precise data on safe doses for cutaneous absorption of phenol, several studies demonstrate that its toxicity is considerable at the concentrations and volumes commonly used in dermatological procedures such as phenol-croton peels. The toxicological literature offers a range for the Median Lethal Dose (LD50) of phenol in humans, which ranges from 50 to 500 mg/kg of body weight, resulting in an estimated dose of 3.5 to 35 g for a 70 kg person.[19,84]

In validated preparations for deep peels, such as the Hetter formula, 10 mL contains approximately 3.5 g of phenol, while the Baker formula contains approximately 4.9 g of phenol in 10 mL, and an 88% phenol solution contains 8.8 g in 10 mL. Considering that 70% of topically applied phenol can be absorbed within 30 minutes, the authors would have an absorbed amount approaching lethal doses: 2.45 g, 3.4 g, and 6.6 g, in 10 mL, respectively.[19,84]

The presence of ingredients such as croton oil and other additives common in irregularly marketed ready-to-use formulas, such as olive oil, cresol, sodium salicylate, camphor, glycerin, and soaps, among others, can potentially increase phenol's skin penetration, exacerbating the risk of systemic toxicity. The total volume of phenol, application methods, and dressing types are not standardized, posing an additional risk, especially when the procedure is performed by non-medical professionals.

Safety in Phenol Procedures. Safe handling of phenol requires rigorous protocols, including multiparameter monitoring, adequate room ventilation, and targeted application techniques. Recent studies, such as that by Rullan et al. (2024),[62] indicate that complications are rare in settings with continuous monitoring and careful application. Other studies, such as that of Landau,[59] demonstrate that factors such as pauses between applications and intravenous hydration are crucial to minimizing the risk of adverse events, especially in patients with comorbidities.

Toxicity is closely related to the excretion rate, area of application, and duration of application of the phenol solution.[79,80] Various organs in the body, including the heart, apparently can tolerate very low levels of phenol in the blood for short periods of time. It therefore seems essential to prevent phenol from being absorbed into the blood faster than natural processes can remove it.[16,76,79]

Recommendations for the Safe Use of Phenol in Dermatology

Pre-Procedure Evaluation

Rigorous and Holistic Screening

A complete medical evaluation of the patient prior to the procedure, including clinical and laboratory evaluations (renal and liver function, complete blood count, and complete metabolic profile), electrocardiography (24-h Holter monitoring), as well as analysis of current medications and skin diagnosis, is essential to minimize risks and ensure good results.[58,59,79]

Patients with a history of QT interval prolongation or use of medications that interfere with this interval are potentially more predisposed to more serious cardiac events.[57,62]

Recommended Maximum Body Surface Area and Safety Criteria by Treated Area

The risk of systemic toxicity from phenol is directly related to the amount of skin surface area treated in a given time period. It is recommended to limit the procedure to a maximum of 5% of the Body Surface Area (BSA), which corresponds approximately to the face and anterior neck (Fig. 8). In cases where the treated BSA exceeds 1.5%, multiparametric monitoring of the patient is essential throughout the procedure. Furthermore, safety pauses must be strictly enforced, and intravenous hydration must be instituted.[89–91] Therefore, a practical categorization of dermatological indications is proposed according to the exposed area (Fig. 8).

1 Procedures with application to up to 0.5% of the BSA:

These include the treatment of conditions such as mucoceles, warts, guttate leukoderma, localized alopecia areata, onychocryptosis, small pilonidal cysts, and isolated scars.

In this context, systemic absorption is minimal, and there is no need for continuous monitoring or intravenous access. The following are sufficient: Oral hydration; Pain control with topical and/or oral analgesia; Clinical attention to alertness.

2 Procedures with application between 0.75% and 1.5% of BSA:

It covers medium-sized areas such as the upper third of the face, perioral region, or periorbital region, with feathering for the cheeks. These procedures require additional care: Intermittent monitoring and peripheral venous access; Intravenous hydration (optional); Safety breaks of 10 to 15 minutes after every 0.5% BSA; Strict control of the time and area treated; Continuous clinical attention.

3 Procedures with application to >1.5% of BSA (maximum 5%):

It includes facial peels (such as phenol-croton) in full-face or Zorro mask applications (Fig. 8) and extensive dermatoses. In these cases, mandatory safety measures include: Continuous multiparametric monitoring (ECG, BP, HR, SpO2); Mandatory intravenous hydration; Safety breaks of 10 to 15 minutes per 0.5% ASC; Strict control of analgesia with regional blocks or potent oral analgesics (avoid deep sedation); Immediate interruption of the procedure: at any sign of organic toxicity; Well-ventilated environment.

The BSA classification offers an objective model for clinical decision-making, reinforcing the safety of phenol procedures and allowing their responsible use according to risk.[90]

Analgesia and Sedation

To minimize the risk of arrhythmias and allow monitoring for signs of intoxication, oral analgesia (avoiding medications that prolong the QT interval) and potent topical analgesia or regional blockade are recommended, rather than deep sedation. Sedation can mask important symptoms, such as changes in speech and alertness, that indicate intoxication. It is recommended that the procedure be stopped immediately if there is any evidence of organ toxicity.[57,91,92]

Safety Breaks

Breaks of 10–15 minutes should be instituted after each 0.5% of BSA treated, allowing partial elimination of phenol between sessions and the return of the QTc interval to baseline.[57,62,90]

Continuous Cardiac Monitoring

Multiparametric monitoring (ECG/BP, HR, and O_2 saturation) should be performed for early detection of arrhythmias or other adverse cardiac events whenever the treated area is greater than 1.5% of BSA or the procedure time is longer than 30 minutes.[58,91,92]

Intravenous Hydration

Intravenous hydration before and during the procedure helps minimize renal toxicity and facilitates the excretion of phenol through the urinary system, reducing its systemic concentration. This support can be provided in an outpatient setting, provided the office is adequately equipped

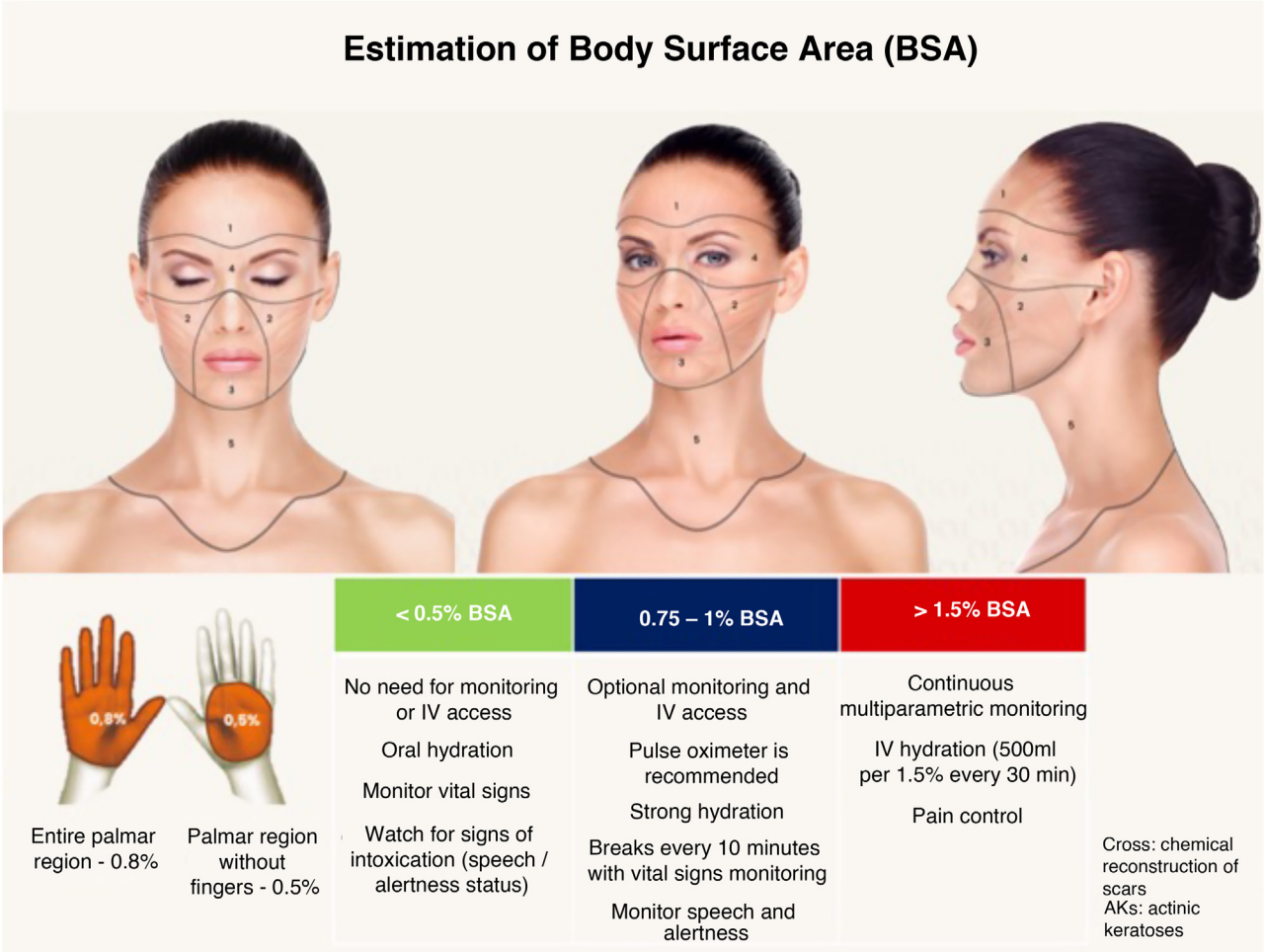

Figure 8 Division of the face into 5 cosmetic units for segmented and spaced application of the phenol-croton peel, ensuring procedure safety. Each unit represents 0.5%–1.5% of the Body Surface Area (BSA). The entire face plus the anterior neck represents 5% of the BSA. The perioral region with cheek feathering represents 1% of the BSA, and the periocular region (''Zorro Mask'') represents 1.5% of the BSA. In procedures with BSA greater than 1.5%, the patient must be monitored multiparametrically, safety breaks must be strictly enforced, and intravenous hydration must be instituted. Photos: Valua Vitaly. Editing and illustration: Ednei Ramos.

and complies with current health regulations for intravenous fluid administration and emergency support. It is recommended to administer 500 mL of Ringer's Lactate before the procedure begins, adding 500 mL for each 1.5% of treated BSA, or 30 minutes into the procedure.[90,91] Intravenous hydration with Ringer's Lactate is preferred in procedures involving phenol due to its balanced composition, which contributes to electrolyte and acid-base stability during the procedure. Unlike saline solution, which contains only sodium and chloride in high concentrations, Ringer's Lactate contains additional electrolytes such as potassium and calcium—important for cardiac stability—and lactate, which is metabolized to bicarbonate, helping to prevent metabolic acidosis often associated with systemic phenol absorption. Furthermore, it has a lower risk of hypernatremia and hyperchloremic acidosis. Although there are no specific studies directly comparing these solutions to phenol peels, the choice of Ringer's Lactate reflects a well-established and physiologically sound clinical practice for maintaining homeostasis in situations of increased metabolic stress.[93]

Environmental Control and Staff Protection

It is essential that the room be well-ventilated to dissipate phenol vapors, reducing the risk of toxic inhalation. Measures such as keeping windows open, keeping fans and/or air conditioning on, and positioning a portable fan near the patient's nostrils to divert vapors from the airway are highly recommended.[94]

Personal protective equipment is mandatory for all professionals involved, including a waterproof apron, thick nitrile gloves, an N95 mask, and protective eyewear.[94]

All materials used in the procedure must be disposed of in rigid containers for hazardous waste, ensuring safe collection and minimizing the risks of environmental exposure.[90]

Figure 9 Hypertrophic scars after phenol-croton peeling in the eyelid region (A and B) and preauricular region (C). Photo: Dr. Felipe Ribeiro.

Formulations, Quality Control, and Safe Preparation

It is essential that the physician performing deep peels with phenol-croton oil prepare the formulation immediately before use, following scientifically validated formulas, such as those proposed by Hetter or Baker, with a known, standardized, and reproducible composition.[19,84] However, it is important to emphasize that the active ingredients are purchased from compounding pharmacies, whose quality certification, traceability, and compliance with current health regulations must be rigorously verified.

The current indiscriminate marketing of phenol and *Croton tiglium* oil, including online and to non-medical professionals, poses a serious health risk. Phenol must have a pharmaceutical-grade purity certification seal and be diluted in absolute alcohol (100%) in a controlled manner.[95] Croton oil, in turn, has high phytochemical variability between different batches and suppliers. Studies using liquid chromatography, mass spectrometry, and HPTLC (High-Performance Thin Layer Chromatography) have shown that many commercial products do not contain the same profile of phorbol esters, compounds directly responsible for the depth of action and the inflammatory pattern of peels.[56,96,97]

Furthermore, stability analyses have shown that the oil composition changes with storage, resulting in the degradation of fatty acids and the possible loss of expected clinical action.[98] Therefore, choosing reliable suppliers with up-to-date analytical reports and rigorous purity control is essential.

The formulation should be prepared in a screw-top glass bottle, mixed continuously to prevent separation of components, and applied immediately after preparation. For staff protection, appropriate PPE is required, including a waterproof apron, thick nitrile gloves, goggles, and an N95 mask. Handling should be done in a well-ventilated environment to minimize the risk of inhalation of toxic vapors.[90]

Regarding the emulsifier, scientific literature recommends the preferred use of Novisol®, due to its safety, compatibility with phenol, and role in emulsion stability, as demonstrated in stability studies of the Hetter formula.[99,100]

Finally, to reduce the risk of systemic toxicity, it is recommended that the total volume of phenol used in a single session does not exceed 10 mL, regardless of the concentration used.[19,84]

Emergency Interventions

The presence of cardiopulmonary resuscitation equipment is mandatory for the management of serious adverse events, such as Acute Respiratory Distress Syndrome (ARDS) or cardiopulmonary arrest. Furthermore, it is essential that physicians performing phenol procedures be highly qualified and have up-to-date training in Advanced Cardiac Life Support (ACLS), ensuring adequate response capacity to critical complications.[76,84,90]

Cutaneous Risks

In addition to the recognized systemic risks of phenol, the use of this agent in dermatology is also associated with significant local complications. These include infections, permanent scarring (Fig. 9), pigmentary changes, ocular damage, and impaired healing, particularly in patients with frontal fibrosing alopecia (FFA).[92,101] (Fig. 10).

FFA compromises skin regeneration due to the loss of follicular stem cells, which play a fundamental role in healing. Recent studies, such as that by Landau et al. (2024),[101] highlight that patients with AFF have a significantly higher risk of scarring complications, making phenol-croton peeling a contraindication in these cases. These findings support the need for phenol procedures to be performed exclusively by trained physicians capable of assessing and managing individual risks. A detailed analysis of local complications would

Figure 10 Abnormal healing one month after phenol-croton 35%/1.2% peeling in a patient with frontal fibrosing alopecia. Photo: Dr. Felipe Ribeiro.

warrant a separate article, given its relevance and complexity.

Conclusions

The use of phenol in dermatology, widely used in procedures such as chemical peels and onychocryptosis treatment, offers effective and unparalleled results. However, its use requires extreme caution due to the risk of systemic toxicity, such as cardiac arrhythmias and organ failure. This reinforces the need for rigorous protocols, especially when applying to larger areas such as the face, including cardiac monitoring, intravenous hydration, safety pauses, and segmented application, always in a controlled environment and under the supervision of specialist physicians.

Careful patient selection is essential to minimize local complications, such as impaired healing in specific conditions, such as FFA. Therefore, not only prior risk assessment but also expertise in conducting the procedure are of fundamental importance, making phenol procedures suitable only for physicians.

Additional studies are needed to determine safe doses and explore the long-term systemic effects of phenol, as well as reinforce the need for strict regulation and public awareness to ensure the safe, ethical, and responsible use of this substance. The lack of standardization in ready-made formulas and the widespread use by non-physicians pose serious risks to public safety.

Financial support

None declared.

Authors' contributions

Carolina Reato Marçon: Design and planning of the study; collection, analysis, and interpretation of data; drafting and editing of the manuscript; critical review of the content; effective participation in research orientation.

Conflicts of interest

None declared.

Research data availability

The entire dataset supporting the results of this study was published in this article.

Editor

Luciana P. Fernandes Abbade

References

1. Lister J. On the antiseptic principle in the practice of surgery. Br Med J. 1867;2:246–8.
2. Wambier CG, Lin E, da Costa Filha ARC, Beltrame FL, Döll-Boscardin PM, Celidonio TC, et al. Updates on level of evidence of clinical efficacy of facial phenol-croton oil peels and comments on history and mechanisms of action. Int J Dermatol. 2023;62:e383–6.
3. Rullan PP, Rullan JM. How we do it: carbolic acid (liquid phenol) 89% ring paint for boxcar and polymorphic acne scars. Dermatol Surg. 2024;50:785–7.
4. Mahmood F, Beach RA. Can it make me white again? A case report of 88% phenol as a depigmenting agent in vitiligo. SAGE Open Med Case Rep. 2021;9, 2050313X21993307.
5. Ravikiran SP, Sacchidanand S, Leelavathy B. Therapeutic wounding - 88% phenol in idiopathic guttate hypomelanosis. Indian Dermatol Online J. 2014;5:14–8.
6. Banihashemi M, Pezeshkpoor F, Yazdanpanah MJ, Family S. Efficacy of 80% phenol solution in comparison with cryotherapy in the treatment of common warts of hands. Singapore Med J. 2008;49:1035–7.
7. Maymone MBC, Mirza FN, Steiner D, Ribeiro F, Landau M, Marçon C, et al. Comparative long-term efficacy of phenol-croton oil chemical peels for persistent melasma at varied croton tiglium oil concentrations. J Am Acad Dermatol. 2024;91:336–8.
8. Garbers LEFM, Miola AC, de Souza V, Brommonschenkel CC, Lima FO, Minicucci EM, et al. Efficacy and tolerability of 1.6% phenol-croton peeling versus topical 5% imiquimod in the treatment of actinic cheilitis: a randomized clinical trial. Clin Exp Dermatol. 2024:llae520.
9. Kaminaka C, Yamamoto Y, Yonei N, Kishioka A, Kondo T, Furukawa F. Phenol peels as a novel therapeutic approach for actinic keratosis and Bowen disease: prospective pilot trial with assessment of clinical, histologic, and immunohistochemical correlations. J Am Acad Dermatol. 2009;60:615–25.
10. Silva NCS, Matter A, Di Chiacchio N, Di Chiacchio NG. Evaluation of the recurrence rate of ingrown toenail after a 45-second matrix cauterization with phenol. Dermatol Surg. 2024;50:1050–5.
11. de Kort J, Pronk A, Vriens MR, Smakman N, Furnee EJB. Phenolization of the sinus tract in recurrent sacrococcygeal pilonidal sinus disease: long-term results of a prospective cohort study. Int J Colorectal Dis. 2024;39:168.
12. Sacchidanand S, Sujaya SN, Purohit V. Phenolisation as a mode of treatment of mucosal cysts. J Cutan Aesthet Surg. 2012;5:210–1.
13. Turan E, Dogru O, Kargin S, Kerimoglu RS, Nazik EE. Crystallized phenol for sacral hidradenitis suppurativa. J Dermatolog Treat. 2021;32:193–6.

14. Mseddi M, Mesrati H, Ktaari S, Amouri M, Chaaben H, Boudaya S, et al. La phénolisation: un nouveau traitement des chéloïdes [Treatment of keloid with phenol: a new therapy]. Ann Dermatol Venereol. 2014;141:493–9. French.
15. Bruce RM, Santodonato J, Neal MW. Summary review of the health effects associated with phenol. Toxicol Ind Health. 1987;3:535–68.
16. Kadunc BV, Vanti AA. Evalution of the systemic toxicity of phenol on facial peelings. Surg Cosmet Dermatol. 2009;1:10–4.
17. Downs JW, Wills BK. Phenol toxicity. StatPearls Publishing; 2023.
18. Kligman AM, Baker TJ, Gordon HL. Long-term histologic follow-up of phenol face peels. Plast Reconstr Surg. 1985;75:652–9.
19. Agency for Toxic Substances and Disease Registry (US). Relevance to public health. In: Toxicological profile for phenol [Internet]. Atlanta: Agency for Toxic Substances and Disease Registry (US); 2008 [cited 2024 Oct 15]. Available from: https://www.ncbi.nlm.nih.gov/books/NBK599443/
20. Ruedemann R, Deichmann WB. Blood phenol level after topical application of phenol-containing preparations. J Am Med Assoc. 1953;152:506–9.
21. Piotrowski JK. Evaluation of exposure to phenol: absorption of phenol vapour in the lungs and through the skin and excretion of phenol in urine. Br J Ind Med. 1971;28:172–8.
22. Zanini M, Machado Filho CAS. Depigmentation therapy for generalized vitiligo with topical 88 percent phenol solution. An Bras Dermatol. 2005;80:415–6.
23. Dalimunthe DA, Siregar R, Tanjung C. Comparative clinical efficacy between electrodesiccation with curettage and application of 80% phenol solution in treatment of common warts. Open Access Maced J Med Sci. 2018;6:326–9.
24. Eldani C, Cirotteau P, Beylot-Barry M, Cogrel O. Phenolization as a treatment option for sinus tracts in hidradenitis suppurativa: a pilot study. J Eur Acad Dermatol Venereol. 2024, http://dx.doi.org/10.1111/jdv.20363. Online ahead of print.
25. Dogru O, Camci C, Aygen E, Girgin M, Topuz O. Pilonidal sinus treated with crystallized phenol: an eight-year experience. Dis Colon Rectum. 2004;47:1934–8.
26. Kayaalp C, Aydin C. Review of phenol treatment in sacrococcygeal pilonidal disease. Tech Coloproctol. 2009;13:189–93.
27. Gan XX, Liu P, Chen SH, Li J, Zhao X, Chen W, et al. A meta-analysis comparing phenol treatment with surgical excision for pilonidal sinus. Asian J Surg. 2024;47:8–15.
28. Kaminaka C, Yamamoto Y, Yonei N, Furukawa F. Phenol application to angiosarcomas: implications and histologic studies. Int J Dermatol. 2009;48:470–5.
29. Chikhalkar S, Jerajani H, Madke B. Evaluation of utility of phenol in alopecia areata. Int J Trichol. 2013;5:179–84.
30. Kar S, Singh N. Alopecia areata treated with phenolisation and intravenous dexamethasone pulses. Int J Trichol. 2013;5:47–9.
31. Platsidaki E, Stravodimou A, Kouris A, Markantoni V, Kontochristopoulos G. Efficacy and safety of phenol and trichloroacetic acid combination peel for the management of dark circles. Actas Dermosifiliogr. 2022;113:988–90.
32. Soon SL, Wambier CG, Rullan PR, Sterling JB, Brody HJ, Lee KC, et al. Phenol-croton oil chemical peeling induces durable improvement of constitutional periorbital dark circles. Dermatol Surg. 2023;49:368–73.
33. Boll OF. Surgical correction of ingrowing nails. J Nat Assoc Chir. 1945;35:8–9.
34. Andreassi A, Grimaldi L, D'Aniello C, Pianigiani E, Bilenchi R. Segmental phenolization for the treatment of ingrowing toenails: a review of 6-years experience. J Dermatolog Treat. 2004;15:179–81.
35. Di Chiacchio N, Belda W Jr, Di Chiacchio NG, Kezam Gabriel FV, de Farias DC. Nail matrix phenolization for treatment of ingrowing nail: technique report and recurrence rate of 267 surgeries. Dermatol Surg. 2010;36:534–7.
36. Zaraa I, Dorbani I, Hawilo A, Mokni M, Ben Osman A. Segmental phenolization for the treatment of ingrown toenails: technique report, follow up of 146 patients, and review of the literature. Dermatol Online J. 2013;19:18560.
37. Rounding C, Hulm S. Surgical treatments for ingrowing toenails. Cochrane Database Syst Rev. 2000:CD001541. Update in: Cochrane Database Syst Rev. 2005:CD001541.
38. Rounding C, Bloomfield S. Surgical treatments for ingrowing toenails. Cochrane Database Syst Rev. 2005:CD001541. Update in: Cochrane Database Syst Rev. 2012:CD001541.
39. Vinay K, Narayan Ravivarma V, Thakur V, Choudhary R, Narang T, Dogra S, et al. Efficacy and safety of phenol-based partial matricectomy in treatment of onychocryptosis: a systematic review and meta-analysis. J Eur Acad Dermatol Venereol. 2022;36:526–35.
40. Mackee GM, Karp FL. The treatment of post-acne scars with phenol. Br J Dermatol. 1952;64:456–9.
41. Leheta TM, Abdel Hay RM, El Garem YF. Deep peeling using phenol versus percutaneous collagen induction combined with trichloroacetic acid 20% in atrophic post-acne scars; a randomized controlled trial. J Dermatolog Treat. 2014;25:130–6.
42. Rullan PP, Rullan JM. Does adding CROSS with carbolic acid add any clinical benefit when doing erbium ablative resurfacing for acne scars? Dermatol Surg. 2024;50:1085–6.
43. Neitzke IC, de Grande Curi D, Lin EM, Lee KC, Soon SL, Lunardelli Bittencourt AC, et al. Translational research on the role of formula stability in Hetter's phenol-croton oil peels: Analysis of chemical studies and clinical outcomes from a randomized, double-blinded, split-face controlled trial. J Am Acad Dermatol. 2021;84:854–6.
44. Cardoso FAMES, Moura RD, Pilar EFS, Moura ICG, Miot HA, da Costa A. Phenol-croton oil peel enhances type-1 and type-3 collagen amounts by stimulating SIRT-6 and SIRT-7. Int J Dermatol. 2022;61:e71–4.
45. Butler PE, Gonzalez S, Randolph MA, Kim J, Kollias N, Yaremchuk MJ. Quantitative and qualitative effects of chemical peeling on photo-aged skin: an experimental study. Plast Reconstr Surg. 2001;107:222–8.
46. Giese SY, McKinney P, Roth SI, Zukowski M. The effect of chemosurgical peels and dermabrasion on dermal elastic tissue. Plast Reconstr Surg. 1997;100:489–98.
47. Hetter GP. An examination of the phenol-croton oil peel: part IV. Face peel results with different concentrations of phenol and croton oil. Plast Reconstr Surg. 2000;105:1061–83.
48. Han SH, Kim HJ, Kim SY, Kim YC, Choi GS, Shin JH. Skin rejuvenating effects of chemical peeling: a study in photoaged hairless mice. Int J Dermatol. 2011;50:1075–82.
49. Wambier CG, Brody HJ, Hetter GP. Comments: Hemiface comparative study of two phenol peels (Baker-Gordon and Hetter formulas) for the correction of facial rhytids. Surg Cosmet Dermatol. 2017;9:190–1.
50. Kaneko H, Onozawa K, Yano H, Abe H. Phenol peel therapy for oral leukoplakia: report of three cases. Oral Med Pathol. 2009;14:59–63.
51. Wang YC, Wei SH, Sun MH, Lin CW. A new mode of percutaneous upper thoracic phenol sympathicolysis: report of 50 cases. Neurosurgery. 2001;49:628–34.
52. Panariello L, Caro G, Bianca D, Fabbrocini G. Phenol 8% solution for the treatment of epidermal growth factor receptor inhibitor-induced periungual pyogenic granulomas. G Ital Dermatol Venereol. 2015;150:755–6.
53. Hetter GP. An examination of the phenol-croton oil peel: Part II. The lay peelers and their croton oil formulas. Plast Reconstr Surg. 2000;105:1083.

54. Baker TJ. The ablation of rhitides by chemical means. A preliminary report. J Fla Med Assoc. 1961;48:451–4.
55. Hetter GP. An examination of the phenol-croton oil peel: Part I. Dissecting the formula. Plast Reconstr Surg. 2000;105:227–39.
56. Justo AS, Lemes BM, Nunes B, Antunes KA, Capote ACMO, Lipinski LC, et al. Characterization of the Activity of Croton tiglium Oil in Hetter's Very Heavy Phenol-Croton Oil Chemical Peels. Dermatol Surg. 2021;47:944–6.
57. Marçon CR, Coppinger AJ, Salomão C, Alves Dos Reis V, Alves Dos Reis VN, de Menezes Gomes JL, et al, International Peeling Society (IPS) and São Paulo's Legal Medical Institute (IML-SP) Fatal Phenol Peel by an Unlicensed Social Media Practitioner: A Forensic Medical Analysis. J Am Acad Dermatol. 2025, http://dx.doi.org/10.1016/j.jaad.2025.05.1461. S0190-9622(25)02555-1. Epub ahead of print. PMID: 40774430.
58. Botta SA, Straith RE, Goodwin HH. Cardiac arrhythmias in phenol face peeling: a suggested protocol for prevention. Aesthetic Plast Surg. 1988;12:115–7.
59. Landau M. Cardiac complications in deep chemical peels. Dermatol Surg. 2007;33:190–3.
60. Stagnone JJ, Stagnone GJ. A second look at chemabrasion. J Dermatol Surg Oncol. 1982;8:701–5.
61. Deichmann WB. Local and systemic effects following skin contact with phenol; a review of the literature. J Ind Hyg Toxicol. 1949;31:146–54.
62. Rullan P, Lin EM, Schaut E, Wambier CG. Cardiac safety in full-face phenol-croton oil peels: a 22-year retrospective study. J Am Acad Dermatol. 2024;91:762–3.
63. Deichmann WB, Miller T, Roberts JB. Local and systemic effects following application of dilute solutions of phenol in water and in camphor-liquid petrolatum on the skin of animals. AMA Arch Ind Hyg Occup Med. 1950;2:454–61.
64. Lucas RC, Lane WA. Two cases of carbolic acid coma induced by the application of carbolic compresses to the skin. Lancet. 1895;145:1362–4.
65. Turtle WRM, Dolan T. A case of rapid and fatal absorption of carbolic acid through the skin. Lancet. 1922;200:1273–4.
66. Miller FG. Poisoning by phenol. Can Med Assoc J. 1942;46:615–6.
67. Giri PP, Sinha R, Sikka S, Meur S. Acute carbolic acid poisoning: a report of four cases. Indian J Crit Care Med. 2016;20:668–70.
68. Cohen N, Modai D, Khahil A, Golik A. Acute resin phenol-formaldehyde intoxication. A life-threatening occupational hazard. Hum Toxicol. 1989;8:247–50.
69. Hassan AB, Seligmann H, Bassan HM. Intravascular haemolysis induced by pentachlorophenol. Br Med J (Clin Res Ed). 1985;291:21–2.
70. Todorović V. Akutna trovanja fenolom [Acute phenol poisoning]. Med Pregl. 2003;56:37–41. Serbian.
71. Lewin JF, Cleary WT. An accidental death caused by the absorption of phenol through skin. A case report. Forensic Sci Int. 1982;19:177–9.
72. Griffiths GJ. Fatal acute poisoning by intradermal absorption of phenol. Med Sci Law. 1973;13:46–8.
73. Abrahams R. A fatal case of carbolic acid poisoning in an infant, due to absorption by the skin. Pediatrics. 1900;9:241–2.
74. Litton C. Observations after chemosurgery of the face. Plast Reconstr Surg. 1963;32:554–6.
75. Stagnone GJ, Orgel MG, Stagnone JJ. Cardiovascular effects of topical 50% trichloroacetic acid and Baker's phenol solution. J Dermatol Surg Oncol. 1987;13:999–1002.
76. Truppman ES, Ellenby JD. Major electrocardiographic changes during chemical face peeling. Plast Reconstr Surg. 1979;63:44–8.
77. Gross BG. Cardiac arrhythmias during phenol face peeling. Plast Reconstr Surg. 1984;73:590–4.
78. Matarasso SL. Phenol chemical peels. In: Wheeland RG, editor. Cutaneous surgery, 39, 1st ed. United States of America: Sauders; 1994. p. 491–508.
79. Wexler MR, Halon DA, Teitelbaum A, Tadjer G, Peled IJ. The prevention of cardiac arrhythmias produced in an animal model by the topical application of a phenol preparation in common use for face peeling. Plast Reconstr Surg. 1984;73:595–8.
80. Beeson WH. The importance of cardiac monitoring in superficial and deep chemical peeling. J Dermatol Surg Oncol. 1987;13:949–50.
81. Li Z, Zhang H, Li SH, Byard RW. Fatal phenol toxicity following attempted tattoo removal. J Forensic Sci. 2016;61:1143–5.
82. Seak CK, Lin CC, Seak CJ, Hsu TY, Chang CC. A case of black urine and dark skin - cresol poisoning. Clin Toxicol (Phila). 2010;48:959–60.
83. Foxall PJ, Bending MR, Gartland KP, Nicholson JK. Acute renal failure following accidental cutaneous absorption of phenol: application of NMR urinalysis to monitor the disease process. Hum Toxicol. 1989;8:491–6.
84. Rodgers GC. Ellenhorn's Medical Toxicology: Diagnosis and Treatment of Human Poisoning. JAMA. 1997;278:1201.
85. Soares ER, Tift JP. Phenol poisoning: three fatal cases. J Forensic Sci. 1982;27:729–31.
86. Fu HS, Chu YK, Liao SQ, Liu RS. Scintigraphic appearance in Lysol-induced lung toxicity. Clin Nucl Med. 2001;26:655–6.
87. Gupta S, Ashrith G, Chandra D, Gupta AK, Finkel KW, Guntupalli JS. Acute phenol poisoning: a life-threatening hazard of chronic pain relief. Clin Toxicol (Phila). 2008;46:250–3.
88. Ghosh S. Self-injection of intravenous carbolic acid and multi-organ failure. Indian J Crit Care Med. 2014;18:43–5.
89. Rendon MI, Berson DS, Cohen JL, Roberts WE, Starker I, Wang B. Evidence and considerations in the application of chemical peels in skin disorders and aesthetic resurfacing. J Clin Aesthet Dermatol. 2010;3:32–43.
90. Wambier C. Brown dermatology phenol-croton oil peeling - standard operating procedure [Internet], 1; 2023 [cited 2024 Oct 15]. Available from: https://www.peelingsociety.com/fileadmin/user_upload/pdf/press/2024/Brown_SOP_Phenol-croton_oil_2023.pdf
91. Wambier CG. Segurança nos peelings profundos. In: Steiner D, Ribeiro F, editors. Peeling químico: manual prático do dia a dia. Rio de Janeiro: Di Livros; 2021. p. 28–38.
92. Wambier CG, Lee KC, Soon SL, Sterling JB, Rullan PP, Landau M, et al. Advanced chemical peels: phenol-croton oil peel. J Am Acad Dermatol. 2019;81:327–36.
93. Kellum JA. Saline-induced hyperchloremic metabolic acidosis. Crit Care Med. 2002;30:259–61.
94. Wambier CG, Beltrame FL. Air safety and personal protective equipment for phenol–croton oil peels. Dermatol Surg. 2018;44:1035–7.
95. United States Pharmacopeial Convention. Phenol monograph. In: United States pharmacopeia 43 – national formulary 38. Rockville (MD): USP; 2020.
96. Capote ACMO, Campos PM, Perera W, Strangman WK, Williamson RT, Beltrame FL. Authentication of commercial Croton tiglium L. oils used as raw material for peeling formulas. Abstracts of the ICSB & ISE 2025 – Joint Meeting. 2025. p. [session PA-7].
97. Capote ACMO, Justo AS, Wambier CG, Beltrame FL. Effects of Croton tiglium oil as deep chemical peeling in skin rejuvenation [poster presentation]. In: XXII Congresso Internacional de Fármacos, Cosméticos e Produtos Naturais – CIFARP 2023. 2023.
98. Capote ACMO, Justo AS, Wambier CG, Beltrame FL. Avaliação da estabilidade de prateleira da solução de óleo de Croton

tiglium L. utilizada na fórmula de Hetter para peeling químico profundo [poster presentation]. In: Congresso Científico da Universidade Estadual de Ponta Grossa – Banner Natal. 2023.
99. Wambier CG, da Costa Filha ARC, Koga AY, Beltrame FL, Döll-Boscardin PM. Emulsifiers maximize the safety and effectiveness of deep chemical peels. J Am Acad Dermatol. 2025;92:e23–4.
100. Justo ADS, Lemes BM, Nunes B, Antunes KA, Carletto B, Koga AY, et al. Depth of injury of Hetter's phenol-croton oil chemical peel formula using 2 different emulsifying agents. J Am Acad Dermatol. 2020;82:1544–6.
101. Landau M, Tosti A, Kroumpouzos G, Eims E, Goldust M. Frontal fibrosing alopecia-A new absolute contraindication for deep chemical peels. Clin Dermatol. 2024;42:696–700.

SOCIEDADE BRASILEIRA DE DERMATOLOGIA

Anais Brasileiros de Dermatologia

www.anaisdedermatologia.org.br

SPECIAL ARTICLE

Artificial intelligence on inflammatory dermatoses: where are we and where are we going?☆

Dimitri Luz F. Silva [a,b,*], **Rafael Rubinho** [a], **Ariany Denofre** [b], **Sandra Avila** [c], **Renata Ferreira Magalhães** [b]

[a] *Department of Dermatology, Universidade de Santo Amaro, São Paulo, SP, Brazil*
[b] *Discipline of Dermatology, Universidade de Campinas, Campinas, SP, Brazil*
[c] *Escola de Engenharia Elétrica e de Computação de Campinas, Universidade de Campinas, Campinas, SP, Brazil*

Received 26 August 2024; accepted 29 December 2024
Available online 18 July 2025

KEYWORDS
Artificial intelligence;
Dermatology;
Convolutional neural networks;
Hidradenitis suppurativa;
Psoriasis

Abstract

Background: Artificial intelligence (AI) is increasingly gaining ground in dermatology, with studies reporting accuracy equal to or greater than dermatologists for the diagnosis of skin lesions from clinical and dermoscopic images.[1] AI has been developed and improved constantly for dermatology, however, the focus has been much more on neoplastic diseases, due to their high prevalence and high morbidity.

Objectives: Describe the possible applications of AI in inflammatory dermatoses.

Methods: Articles published between 2013 and 2023 in Medline and Lilacs were retrieved after applying the inclusion and exclusion criteria 19 articles were selected. From each selected article, the necessary information was extracted and with this data, the present review was written.

Results: The first studies on AI in dermatology focused on the diagnosis of neoplasms, especially melanoma, due to the ease of standardization of images, obtaining accuracy equivalent to that of a dermatologist in clinical and dermoscopic lesions. Actually, there are many studies on artificial intelligence in inflammatory dermatosis, such as psoriasis, helping to calculate the PASI, hidradenitis suppurativa, and atopic dematitis.

Study limitations: The limitation of the study is that it is a literature review and because it is an innovative topic with a limited number of studies published in the literature.

Conclusions: Considerable of what is published in the literature is in computer science journals, but it is possible to perceive that there is an important interest in the area and that artificial intelligence will advance to assist dermatologists.

☆ Study conducted at the Universidade de Campinas, Campinas, SP, Brazil and Universidade de Santo Amaro, São Paulo, SP, Brazil.

* Corresponding author.
E-mail: dimitriluzfs@gmail.com (D. Luz F. Silva).

https://doi.org/10.1016/j.abd.2025.501164

Introduction

Artificial intelligence (AI) is increasingly gaining ground in dermatology, with studies reporting accuracy equal to or greater than dermatologists for diagnosing skin lesions from clinical and dermoscopic images. However, there is currently no clinical validation in the real world, being mainly used in research protocols.[1] In the current scenario, AI has three main applications in dermatology: telemedicine, including triage for referral to dermatologists; screening and clinical evaluation applications prior to consultations; and dermatopathology, in order to accelerate diagnosis and assist the pathologist.[2,3]

Studies on the application of convolutional neural networks in dermoscopy for classification algorithms have demonstrated superior performance in the early detection of melanocytic lesions, particularly melanoma. For this purpose, a dataset of 100 dermoscopic images was analyzed, with participants divided into three groups. The first two groups consisted of dermatologists skilled in dermoscopic techniques: Group 1 had access to images only, while Group 2 had access to both images and clinical data. Group 3 employed AI algorithms developed by the authors. Diagnostic specificity reached 82.5% in the AI group, compared to 71.3% and 75.7% in Groups 1 and 2, respectively.[3,4]

AI has been developed and improved constantly for dermatology. However, it focuses mostly on neoplastic diseases, due to their high prevalence and high morbidity. Inflammatory skin diseases, such as psoriasis, are in initial steps, with applications for triage of lesions, with a sensitivity of up to 20% and specificity of 62% only with AI.[3,4] This review article presents possible applications of AI in inflammatory dermatoses.

Methods

A narrative review of articles published between 2013 and 2023 in Medline and Lilacs search platforms was conducted using the following keywords: ''AI''; ''psoriasis''; ''hidradenitis suppurativa''; ''atopic dermatitis''; ''dermatology'', associated with the boolean operators ''and'' and ''or''.

Inclusion criteria for articles: articles in Portuguese or English; published between 2013 and 2022; prospective or retrospective observational studies; systematic and non-systematic literature reviews; cohort studies; clinical trials; addressing the theme ''AI and dermatology''.

Exclusion criteria: case reports, case series, editorials, expert opinion, reviews, studies without complete original texts with online access, articles not written in English or Portuguese, and articles that, after selection in the inclusion and exclusion criteria, presented themes not related to AI and dermatology.

In the initial search with keywords described above and Boolean terms, 52 articles were found on the MEDLINE platform and 8 on the LILACS platform. After applying the inclusion and exclusion criteria, 43 articles were found. After applying the criteria 19 articles were selected. It is worth mentioning that application of these criteria was carried out independently by the authors of this dissertation, including only those which was consensus for inclusion.

From each selected article, the main data on AI were selected and included in the present review.

AI and psoriasis

Psoriasis is an inflammatory disease that affects 125 million people worldwide. Its evaluation can be performed using the Psoriasis Area and Severity Index (PASI), a validated tool most used in patients with plaque psoriasis. PASI is essential so that the dermatologist has a numerical parameter of the patient's evolution, especially in the era of advances in immunobiologicals.[4]

It is observed that PASI presents significant intra- and inter-rater variation, which is calculated in up to 33% of cases, mainly in university centers where the same dermatologist does not evaluate the patient. AI can help both in the diagnosis and calculation of PASI, as well as in the application of personalized protocols and prediction of clinical evolution.[4–6]

The first AI program for psoriasis was developed in 2014 to predict the risk of psoriasis in two genetic databases with 99% accuracy. Afterward, Deep Learning programs began to be developed to calculate the PASI, aiming to facilitate and standardize the assessment. Programs are developed based on the opinions of specialists in the area, and image banks are used for training. From this, the AI calculates the score from image analysis, and this result is compared with expert opinion. So far, few published studies have focused on part of the PASI score and not on the final value.[7]

The first evaluation was carried out by Shrivastava et al. from the analysis of each pixel of the photos of the body segments, being classified as a skin or area of the lesion, with an accuracy of 99%. However, it used only 670 images for training, which may have generated an unreliable result. Other studies accurately calculated the PASI subcategories, ranging from 93.8% to 48.8%. There is one that only evaluated erythema and desquamation, with accuracies of 78.9% and 88.7% respectively.[6,8]

A recent 2022 publication used 705 trunk photos for Convolutional Neural Network (CNN- an example is demonstrated in Fig. 1) training called Single-Shot PASI. Afterward, the test was validated with 10 images, that were selected as tests sets and were excluded from the training sets. The study also compared the difference in PASI before and after the aid of the AI (the specialist calculated the PASI and then saw the PASI of the AI, being able to redo it), showing that the AI helps a more homogeneous classification among the evaluators. However, it is highlighted that, ideally, training should be performed with more than 10,000 images for deep learning models, but it is possible to perform with less.[9]

Three recent papers obtained positive results with programming for calculating the complete PASI: Huang et al. used 1962 patients for training and 405 to validate the test. The model was compared with the evaluation of 43 experi-

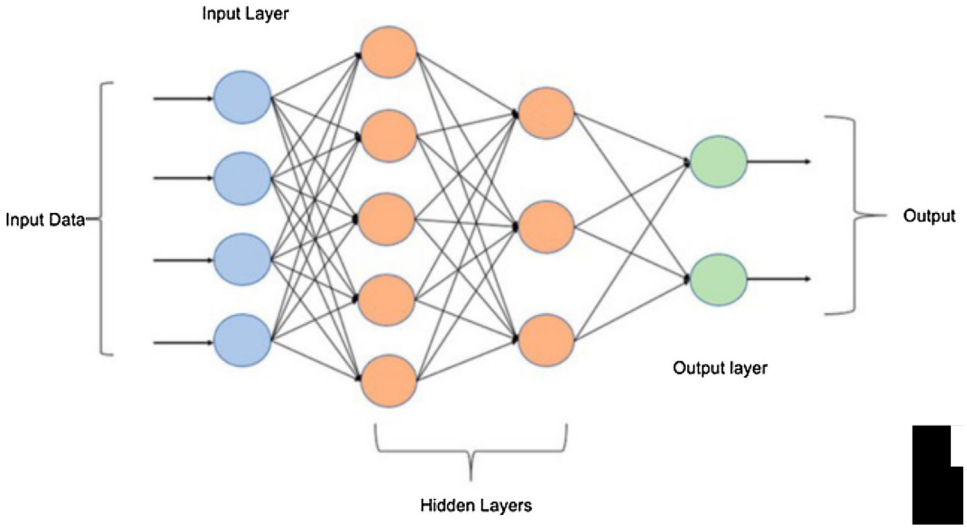

Figure 1 Multilayer perceptron basic architecture.

enced dermatologists. Finally, the model was incorporated into an application in which patients could take a picture of themselves to include the PASI in the medical record.[10]

Another important work was carried out with Schaap et al., training the CNN with 576 images of the back, 614 of the arms, and 541 of the legs, using the classification of specialists as a basis and then compared with the evaluation of only the image of the trunk with 5 physicians with PASI experience. The AI had a similar performance, with a better assessment of the body surface area, reaching an accuracy of 79.4%. However, the comparison of total PASI was not evaluated, and comparisons of more severe scores were excluded due to a lack of sufficient images for training.[11]

Finally, Fink et al. obtained a concordance of 0.86 in evaluating 120 patients, comparing AI and experienced physicians. The agreement remained high when the evaluation was repeated, which did not occur with physicians. A previous study at the institution showed a difference of 27% in the calculation of PASI. When repeating the same patient after 4-weeks, there was a variation of up to 33%. Photos were captured using FotoFinder with 4 predefined poses, standardizing the method.[12]

As previously mentioned, an important limitation of Deep Learning is that a large number of images are required for training and reliable validation of the method. In addition, most of the published studies were carried out with the same ethnic group, which makes them little applicable worldwide so far. There is also a limitation in evaluating curved areas, such as elbows and knees, typically affected by psoriasis.

AI and atopic dermatitis

Atopic dermatitis is the most common chronic inflammatory skin disease in the world, with an essential impact on the quality of life of patients, productivity at work, and health systems, with an approximate worldwide prevalence of 15% to 28%, being of multifactorial origin and complex pathophysiology. Dermatology already benefits from AI in several areas, which has proved to be fundamental as an adjuvant method for diagnosis, classification of severity, and personalization of care, as well as an adjuvant for defining therapy in dermatoses, including, albeit incipient, in atopic dermatitis. However, few publications in the area demonstrate a potential for development and research today.[6]

A study carried out by Guimarães and collaborators in 2021 proposed an AI algorithm for CNN-based analysis of tomographic images of patients with atopic dermatitis (AD). In atopic dermatitis, it is possible to identify changes such as cellular irregularity, intracellular changes, perinuclear accumulation of mitochondria, and various metabolic changes. Despite the low sample size, this study demonstrated high sensitivity and specificity for diagnosing AD according to the imaging characteristics, thus providing a new method with increased diagnostic accuracy.[13,14]

Due to the multifactorial origin of atopic dermatitis and the correlation of genetic mutations and alterations in the intestinal microbiome as predisposing factors for the development of AD, Jiang et al. published a study in 2022 in which they described machine learning to predict the risk of developing AD. AD and the phenotypic profile according to these factors. This controlled study captured 161 patients and evaluated 35 genes and 50 microbial characteristics, and with limitations of the study, they published an algorithm capable of accurately differentiating based only on transcriptome and microbiome data from healthy individuals affected by AD.[15]

Atopic dermatitis currently has consolidated scores in the literature, such as the SCORAD (''SCORing Atopic Dermatitis) and EASI (Eczema Area and Severity Index). However, numerous variables depend on examiners in SCORAD, presenting different classifications in the same patients when applied by different experienced dermatologists. A study carried out by Medela and collaborators created an AI algorithm capable of classifying and calculating the SCORAD through the interpretation of patient images in a fast, objective, and fully automated way. This new model would have an impact both in clinical practice by optimizing the time for calculating the SCORAD, subjectivity in the scores, and allowing classification in virtual consultations, as well as in clinical trials,

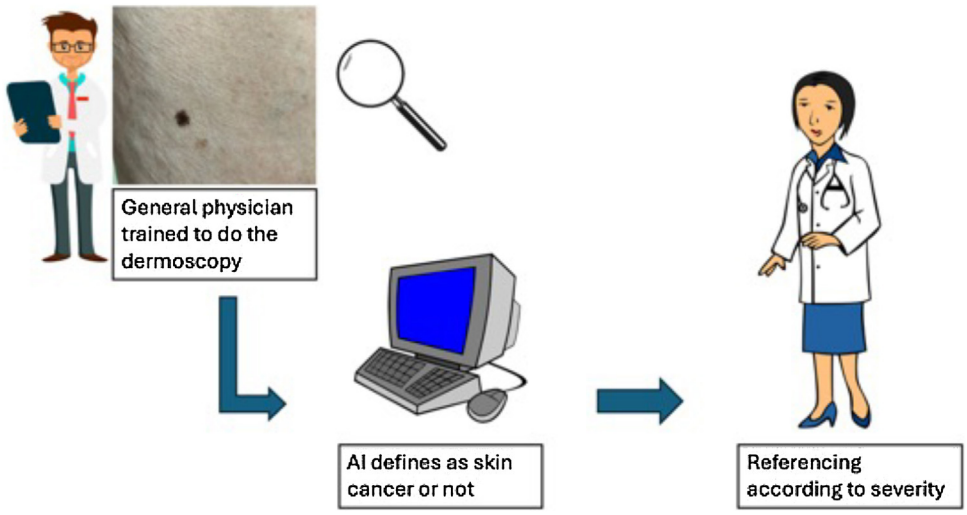

Figure 2 How can AI improve the skin cancer diagnosis? – Naevus on the left leg of a 50 year-old patient (UNICAMP archive).

to the point that it would reduce the SCORAD classification biases by the examiners.[16]

Some studies sought to develop CNN to automate the EASI classification, developing AI capable of measuring the degree of erythema, papules, excoriation, and lichenification by capturing images of patients. A study carried out in 2021 by Bang and collaborators captured 8000 clinical images of atopic dermatitis without photo quality criteria, inserted them into four different CNN platforms to allow automated EASI calculation, and demonstrated classification rates very similar to those attributed by the professional dermatologist demonstrating the effectiveness of AI and the possibility of its clinical applicability.[17]

Finally, it is noted that the role of AI is still incipient in atopic dermatitis; however, published algorithms and prototypes, ranging from methods for diagnosis, classification and, consequently, influence on the therapeutic definition, have shown a promising space for both clinical practice daily, as in clinical trials and other scientific studies.[15,16]

AI and hidradenitis suppurativa

Hidradenitis suppurativa (HS) is a chronic inflammatory skin condition that causes nodules, abscesses, and fistulas in the armpits, groin, and other areas of skin folds. HS is a debilitating disease that can significantly affect patients' quality of life, with cumulative impacts throughout an individual's lifetime.[18]

AI is a technology that can be used to improve the diagnosis, treatment, and prognosis of HS, as well as new diagnostic methods (use of medical images to identify HS lesions), develop new treatments (immunotherapy and gene therapy) or even in the proper screening of patients, as in a work that used a chatbot and patients imputed their symptoms, later being evaluated for a more accurate diagnosis.[18,19]

AI can also be used to improve the prognosis of HS, predict the risk of complications, and develop rehabilitation programs for patients with HS. To standardize the classification of this disease, a Spanish group tested the AI in the evaluation and application of the International Hidradenitis Suppurativa Severity Score System (IHS4), a disease severity score used both in practice and in clinical studies, which may mean, in addition to a better classification of the disease, to better predict prognosis and which best treatment should be instituted at the best stage of the disease. The work even shows that the AI model used had comparable results with the clinical evaluation of experts, according to the consensus and standards already studied in the literature, exemplifying an AI performance model applicable to the routine of dermatologists who treat HS.[20]

AI and other dermatosis

The first studies on AI in dermatology focused on diagnosing neoplasms, especially melanoma, due to the ease of standardization of images, obtaining accuracy equivalent to dermatologists. As a justification, it can be used in teleconsultation to improve patient access to specialized care.

About half of skin-related visits are with non-dermatologists, who lack specialized training. When comparing the AI diagnosis with the primary care doctor, the AI performed better. In 2016, the first program diagnosed melanoma using 170 images of melanoma and 170 of nevi with a sensitivity and specificity of approximately 0.8. It was only in 2017, with the use of CNN, that it was possible to perform the differential diagnosis between melanoma and benign nevus and epithelial tumors and seborrheic keratosis. In studies, CNN's performance is comparable to that of an experienced dermatologist, or even better[3,4] With the use of IA, it is possible to accelerate the diagnosis of skin cancer by a general physician, after training in the use of dermoscopy, so that the referral can be as quick as severity demands (Fig. 2).

The use of AI in histopathology is also possible; there is good performance reported in the diagnoses of BCC, prostate, and breast neoplasms as well. It is possible to increase accuracy up to 78%, mainly if molecular analysis is used for training. The method analyzes each pixel of the image as malignant or not in a binary way. A significant

Table 1 Summary of the main advances in AI in dermatology.

Subtheme	Authors	Key Data
AI and Psoriasis	Shrivastava S, et al.	AI analysis of body segment photos for psoriasis with 99% accuracy. Study used 670 images for training.
	Huang J, et al.	Deep learning model for PASI calculation using 1962 patients for training and 405 for validation. Accuracy achieved.
	Schaap T, et al.	CNN trained with 576 images of the back, 614 of the arms, and 541 of the legs, achieving 79.4% accuracy in body surface area assessment.
	Fink C, et al.	AI concordance of 0.86 in PASI evaluation of 120 patients. High agreement with experienced physicians. Excluded curved body areas and areas covered by hair.
AI and Atopic Dermatitis	Guimarães TA, et al.	AI algorithm for CNN-based analysis of multiphoton tomography images for atopic dermatitis. High sensitivity and specificity for diagnosis.
	Jiang Q, et al.	Machine learning to predict risk of developing atopic dermatitis based on 35 genes and 50 microbial characteristics. Accurate differentiation of AD.
	Medela A, et al.	AI algorithm for automated SCORAD classification from patient images. Optimizes calculation time and reduces subjectivity.
	Bang Y, et al.	Automated EASI calculation using CNN with 8000 clinical images Classification rates similar to professional dermatologists.
AI and Hidradenitis Suppurativa	Hernández I, et al.	AIHS4 uses Legit.Health-IHS4net based on YOLOv5 architecture. Assesses HS severity with performance comparable to expert physicians. Reduces inter-observer variability.
	Wiala A, et al.	Uses CNNs for HS severity classification. Dataset includes 7675 images. Overall prediction accuracy of 78% and IHS4 classification accuracy of 72%. U-NET algorithm localizes lesions with 88.1%-pixel accuracy.
	Crovella S, et al.	Integrates AI for early HS diagnosis using machine learning and deep learning algorithms for image analysis. Recognizes subtle patterns and addresses challenges like data privacy.
AI and Other Dermatoses	Young AT, et al.	Review of AI applications in dermatology, including telemedicine screening, and dermatopathology. Highlights CNNs' performance in diagnosing melanocytic lesions and AI's role in PASI calculations HS management, and onychomycosis diagnosis.

CNN, Convolutional Neural Network; AT, Atopic Dermatitis; EASI, Eczema Area and Severity Index; HS, Hidradenitis Suppurativa; AI, Artificial Intelligence; PASI, Psoriasis Area and Severity Index; SCORAD, SCORing Atopic Dermatitis.

advantage would be access to diagnosis in places with no dermatopathologist.[1,2]

It is essential to highlight that most of the models were created in Europe and East Asia, with essential limitations for use in other populations as well. Another critical factor is that the dermatologist analyzes other factors to consider malignancy in diagnosing melanoma, while AI cannot, leading to more false positives. The use of AI also requires standardization of photos with quality and good lighting, something difficult to obtain on a large scale. In addition, there is no study with real-world experience or with rarer lesions such as amelanotic melanoma. The dermatologist diagnoses more than 2000 skin diseases, while the algorithm was trained for up to 757 diseases, with binary classification as malignant vs. benign. It does not perform well when used to distinguish diagnoses.[1–3]

Conclusion

The integration of AI in dermatology will occur as research advances. With the perspective to enhance the accuracy of diagnosis and follow up besides the availability of specialist diagnosis for skin cancer and inflammatory skin diseases, AI can help to speed patient access to treatment, especially in places where dermatologist is not easily available. The need of a large dataset for algorithm training is still the major difficulty for validation however, good evidence with high accuracy has been shown. Another important highlight is that most algorithms are trained with white and Asian skin, limiting the application for mixed-race populations, like Brazil. Future research will be crucial to overcoming these barriers and realizing the full potential of AI in dermatology (Table 1).

Editor

Sílvio Alencar Marques.

Research data availability

The entire dataset supporting the results of this study was published in this article.

Financial support

None declared.

Authors' contributions

Dimitri Luz Felipe da Silva: Drafting and editing of the manuscript.

Rafael Rubinho: Drafting and editing of the manuscript.

Ariany Denofre: Drafting and editing of the manuscript.

Sandra Avila: Review of the manuscript.

Renata Ferreira Magalhaes: Review and approval of the final version of the manuscript.

Conflicts of interest

None declared.

References

1. Young AT, Xiong M, Pfau J, Keiser MJ, Wei ML. Artificial intelligence in dermatology: a primer. J Invest Dermatol. 2020;140:1504–12.
2. Giavina M, Santos AP, Cordioli E. The majority of skin lesions in pediatric primary care attention could be managed by Teledermatology. PLoS One. 2019;14:e0225479.
3. Haenssle HA, Fink C, Schneiderbauer R, Toberer F, Buhl T, Blum A, et al. Man against machine: diagnostic performance of a deep learning convolutional neural network for dermoscopic melanoma recognition in comparison to 58 dermatologists. Ann Oncol. 2018;29:1836–42.
4. Hogarty DT, Su JC, Phan K, Attia M, Hossny M, Nahavandi S, et al. Artificial intelligence in dermatology – where we are and the way to the future: a review. Am J Clin Dermatol. 2020;21:41–7.
5. Du-Harpur X, Watt FM, Luscombe NM, Lynch MD. What is AI? Applications of artificial intelligence to dermatology. Br J Dermatol. 2020;183:423–30.
6. Patel S, Wang JV, Motaparthi K, Lee JB. Artificial intelligence in dermatology for the clinician. Clin Dermatol. 2021;39:667–72.
7. Rundle CW, Hollingsworth P, Dellavalle RP. Artificial intelligence in dermatology. Clin Dermatol. 2021;39:657–66.
8. Shrivastava VK, Londhe ND, Sonawane RS, Suri JS. A novel and robust Bayesian approach for segmentation of psoriasis lesions and its risk stratification. Comput Methods Programs Biomed. 2017;150:9–22.
9. Schaap MJ, Cardozo NJ, Patel A, de Jong EMGJ, van Ginneken B, Seyger MMB. Image-based automated psoriasis area severity index scoring by Convolutional Neural Networks. J Eur Acad Dermatol Venereol. 2022;36:68–75.
10. Okamoto T, Kawai M, Ogawa Y, Shimada S, Kawamura T. Artificial intelligence for the automated single-shot assessment of psoriasis severity. J Eur Acad Dermatol Venereol. 2022;36:2512–5.
11. Huang K, Wu X, Li Y, Lv C, Yan Y, Wu Z, et al. Artificial intelligence-based psoriasis severity assessment: real-world study and application. J Med Internet Res. 2023;25:e44932.
12. Fink C, Alt C, Uhlmann L, Klose C, Enk A, Haenssle HA. Precision and reproducibility of automated computer-guided psoriasis area and severity index measurements in comparison with trained physicians. Br J Dermatol. 2019;180:390–6.
13. Guo P, Luo Y, Mai G, Zhang M, Wang G, Zhao M, et al. Gene expression profile based classification models of psoriasis. Genomics. 2014;103:48–55.
14. Guimarães P, Batista A, Zieger M, Kaatz M, Koenig K. Artificial intelligence in multiphoton tomography: atopic dermatitis diagnosis. Sci Rep. 2020;10:7968.
15. Jiang Z, Li J, Kong N, Kim JH, Kim BS, Lee MJ, et al. Accurate diagnosis of atopic dermatitis by combining transcriptome and microbiota data with supervised machine learning. Sci Rep. 2022;12:290.
16. Medela A, Mac Carthy T, Aguilar Robles SA, Chiesa-Estomba CM, Grimalt R. Automatic SCOring of atopic dermatitis using deep learning: a pilot study. JID Innov. 2022;2:100107.
17. Hwan Bang C, Yoon JW, Ryu JY, Chun JH, Han JH, Lee YB, et al. Automated severity scoring of atopic dermatitis patients by a deep neural network. Sci Rep. 2021;11:6049.
18. Wiala A, Ranjan R, Schnidar H, Rappersberger K, Posch C. Automated classification of hidradenitis suppurativa disease severity by convolutional neural network analyses using calibrated clinical images. J Eur Acad Dermatol Venereol. 2024;38:576–82.
19. Crovella S, Suleman M, Tricarico PM, Al-Khuzaei S, Moltrasio C, Elomri A, et al. Harnessing artificial intelligence for advancing early diagnosis in hidradenitis suppurativa. Ital J Dermatol Venereol. 2024;159:43–9.
20. Montilla IH, Medela A, Mac Carthy T, Aguilar A, Gómez Tejerina P, Sueiro AV, et al. Automatic International Hidradenitis Suppurativa Severity Score System (AIHS4): a novel tool to assess the severity of hidradenitis suppurativa using artificial intelligence. Skin Res Technol. 2023;29:e13357.

SOCIEDADE BRASILEIRA DE DERMATOLOGIA

Anais Brasileiros de Dermatologia

www.anaisdedermatologia.org.br

LETTER - RESEARCH

Epidemiological profile and main allergens identified in cases of allergic contact cheilitis☆

Dear Editor,

Allergic contact cheilitis (ACC) is an inflammatory reaction on the lips resulting from a type 4 hypersensitivity reaction.[1] They may occur alone or in association with perioral eczema, stomatitis, contact dermatitis, atopic dermatitis, and other diseases.[1,2] The main etiologies described include: musical instruments, hygiene products (such as toothpaste and lip balm), cosmetics (applied to the face or other areas), topical medications, dental materials or food allergens.[3]

Patients from outpatient clinics of a public and a private service with suspected ACC, with exclusive involvement of the lips, treated between January 2018 and August 2024, were selected. The allergens used in the tests were those present in the Brazilian standard batteries (FDA Allergenic/RJ/Brazil), hair series and Latin American series (IPI Asac-SP/Brazil, consisting of the substances present in the standard series plus propyl gallate, disperse blue, dialkyl thiourea, methylisothiazolinone (MI), hydrocortisone butyrate, fragrance mix 2, cocamidopropyl betaine, Methyldibromo glutaronitrile (MDBGN), IPPD, sesquiterpene lactone mix, propolis, budesonide, hydrocortisone acetate, lyral, toluenesulfonamide-formaldehyde resin, Diazolidinyl urea, and imidazolidinyl urea) in addition to allergens selected from the literature that are common for allergic contact dermatitis (ACD) in this location (compounding pharmacy). The readings were performed at 48 and 96 hours, according to previously established criteria.

A total of 736 patch tests were performed in the public service and 250 in the private sector during the analyzed period, totaling 986 tests. Of these, those with lesions exclusively on the lips were selected. Thus, there were 8 cases (1%) in the public service and 13 (5.2%) in the private sector, totaling 21 cases (2.1%). The patients' ages ranged from 18 to 78 years, with a mean of 35 years. There was a higher frequency of female patients (76%). The average time from disease onset to patch testing was 12 months. The most frequent substance in the tests was Fragrance Mix 1 (FM1 14.6%), as shown in Table 1.

Table 1 Distribution of positive substances in patch tests in cases of Allergic Contact Dermatitis (ACD) of the lips.

Substance	Number of reactions	Percentage (%)
Fragrance mix 1	9	14.60%
Galates	5	8.20%
MDBGN	4	6.60%
Fragrance mix 2	3	4.80%
CAPB	3	4.80%
Sodium palladate	3	4.80%
Propolis	3	4.80%
Carba mix	2	3.30%
p-tertiary-butylphenol	2	3.30%
Cinnamaldehyde	2	3.30%
Lanoline	1	1.50%
Balsam of Peru	1	1.50%
Parabens	1	1.50%
Diazolidinyl urea	1	1.50%
Shellac	1	1.50%
Lyral	1	1.50%
Sesquiterpene lactone mix	1	1.50%
Eugenol	1	1.50%
Dimethicone	1	1.50%
Hydrocortisone	1	1.50%
Benzyl alcohol	1	1.50%
Chloroxylenol	1	1.50%
Formaldehyde	1	1.50%
Benzophenone 3	1	1.50%
BHT	1	1.50%
Propylene glycol	1	1.50%
MI	1	1.50%
Benzyl cinnamate	1	1.50%
Citronellol	1	1.50%
Total	62	100%

*Some patients had more than one positive test.
CAPB, Cocamidopropyl betaine; MDBGN, Methyldibromo glutaronitrile; BHT, Butylhidroxytoluiene; MI, Methylisothiazolinone.

☆ Study conducted at the Dermatology Clinic, Irmandade da Santa Casa de Misericórdia de São Paulo, São Paulo, SP, Brazil.

https://doi.org/10.1016/j.abd.2025.501170

Figure 1 Patient with Allergic Contact Cheilitis (ACC) on the lip with sensitivity to CAPB (Cocamidopropyl betaine). Left: patient at the first consultation. Right: patient after stopping contact with CAPB.

A total of 21 suspected cases of ACC were evaluated, with lesions exclusively on the lips (2.1%) among those submitted to patch tests, showing a low frequency of the dermatosis in this location, in agreement with results in the literature, which show a frequency of 1% to 3.4%.[4] The patients' mean age of 35 years, ranging from 18 to 78 years, was similar to that of some studies, which showed ages ranging between 41 and 47 years. The group consisted mostly of women (16/76%), a finding consistent with other studies, possibly due to the greater use of cosmetics by this population.[4,5] The most common allergens observed were fragrances, respectively FM1 (9/14.6%) and FM2 (3/4.8%), present in toothpastes, topical medications, lip cosmetics and perfumes. Their relevance for cases of cheilitis in the literature ranged from 5.4% to 38%, consistent with the findings in this study.[6,7] Balsam of Peru, also considered a marker of fragrance allergy, was positive in one case (1.5%), which was associated with positivity to citronellal (1.5%). CAPB (Cocamidopropyl betaine), positive in three cases (4.8%; Figs. 1 and 2), is a common lip allergen classified as a surfactant, often diluted in peppermint oil, a common ingredient in toothpastes.[8] Gallates are antioxidants present in cosmetics, topical medications, and foods, and is also commonly used in lipsticks; they were positive in five cases (8.2%) in this study, a lower prevalence than the 36% found in the study by Loidi-Pascual et al.[4] MDBGN is a preservative used in liquid soaps, shampoos, moisturizers, vaginal gels, makeup remover wipes, glues, adhesives, sanitary pads and topical medications; it was positive in 6.6% of cases and was related in the present patients to the use of lip balms.[5,7] Propolis is an uncommon allergen for the lips and is generally present as a contaminant in beeswax, a common component in balms and lipsticks, having been observed in one case (1.5%); however, the study by Nyman et al. showed a 19% frequency among 95 patients with suspected contact cheilitis, CD of the face and perioral region.[5] Some preservatives,



Figure 2 Patch test on the back with positivity to CAPB (Cocamidopropyl betaine) for the patient with allergic contact cheilitis (ACC) on the lip.

such as parabens, diazolidinyl urea and BHT (butylhidroxytoluiene), are mainly used in topical medications and are considered the second most common group of allergens in cosmetics after fragrances, with prevalence rates of up to

32%.[7] Among the evaluated cases, they were positive in one case each (1.5%). Shellac is a natural resin from an insect (*Laccifer lacca*), used in the food, pharmaceutical and cosmetic industries for its emollient and film-forming properties and found in hair sprays, lotions, shampoos, eyeliners, mascara, nail polish, lipsticks and fragrances; it was positive in one case (1.5%) and was related to lipstick use.[3] Finally, benzophenone-3 is a component of sunscreens, also present in other cosmetics with the function of protecting the product against deterioration due to ultraviolet radiation action; among the study patients, it was positive in one case (1.5%), related to the use of lip gloss.

Even though the literature describes metals (e.g., nickel sulfate and potassium bichromate) and drugs (e.g., neomycin) as allergens frequently implicated in contact cheilitis, these findings were not evidenced in the present study, probably because of the small sample size.[9]

Although the patch tests in this study were not performed with the products used by the patients, as recommended in some studies, a detailed anamnesis was performed to ensure that the allergens to which the patients were exposed were included in the battery of applied tests.[9] Although patients are instructed to bring the suspected products on the day of the test, there is low adherence to the procedure, often with claims of forgetting or not having the product at the time of the exam.

Although the group studied a small number of patients, the study demonstrates the importance of patch tests in cases of cheilitis, to establish the diagnosis of allergic contact dermatitis, as well as the most prevalent causative agents.[9]

Editor

Luciana P. Fernandes Abbade.

Research data availability

The entire dataset supporting the results of this study was published in this article.

Financial support

None declared.

Authors' contributions

Bruna Cavaleiro de Macedo Souza: Statistical analysis; approval of the final version of the manuscript; design and planning of the study; drafting and editing of the manuscript; collection, analysis and interpretation of data; effective participation in research orientation; intellectual participation in the propaedeutic and/or therapeutic conduct of the studied cases; critical review of the literature; critical review of the manuscript.

Laiza Bertolucci Ferrero: Statistical analysis; approval of the final version of the manuscript; drafting and editing of the manuscript; collection, analysis and interpretation of data; critical review of the literature; critical review of the manuscript.

Mariana de Figueiredo Silva Hafner: Statistical analysis; approval of the final version of the manuscript; design and planning of the study; drafting and editing of the manuscript; collection, analysis and interpretation of data; effective participation in research orientation; intellectual participation in the propaedeutic and/or therapeutic conduct of the studied cases; critical review of the literature; critical review of the manuscript.

Rosana Lazzarini: Statistical analysis; approval of the final version of the manuscript; design and planning of the study; drafting and editing of the manuscript; collection, analysis and interpretation of data; effective participation in research orientation; intellectual participation in the propaedeutic and/or therapeutic conduct of the studied cases; critical review of the literature; critical review of the manuscript.

Conflicts of interest

None declared.

References

1. Tramontana M, Hansel K, Bianchi L, Sensini C, Malatesta N, Stingeni L. Advancing the understanding of allergic contact dermatitis: from pathophysiology to novel therapeutic approaches. Front Med (Lausanne). 2023;10:1184289.
2. Melchers RC, Quint KD, van Zuuren EJ. Contact allergy to a shellac-containing mouthguard. Contact Dermatitis. 2022;86:554–6.
3. Rosmaninho I, Moreira A, da Silva JPM. Contact dermatitis: Literature review. Rev Port Imunoalergologia. 2016;24:197–209.
4. Loidi-Pascual L, Hervella-Garcés M, Larrea-García M, Santesteban-Muruzábal R, Agulló-Pérez A, Yanguas-Bayona I. Lip eczema. Experience in the Contact Dermatitis Unit of a Spanish tertiary hospital. An Sist Sanit Navar. 2015;38:409–16.
5. Nyman GSA, Tang M, Inerot A, Osmancevic A, Malmberg P, Hagvall L. Contact allergy to beeswax and propolis among patients with cheilitis or facial dermatitis. Contact Dermatitis. 2019;81:110–6.
6. Francalanci S, Sertoli A, Giorgini S, Pigatto P, Santucci B, Valsecchi R. Multicentre study of allergic contact cheilitis from toothpastes. Contact Dermatitis. 2000;43:216–22.
7. Rocha VB, Available from: http://hdl.handle.net/1843/BUBD-9VZK3E, 2014.
8. Van Baelen A, Kerre S, Goossens A. Allergic contact cheilitis and hand dermatitis caused by a toothpaste. Contact Dermatitis. 2016;74:187–9.
9. Narayanan D, Rogge M. Cheilitis: A diagnostic algorithm and review of underlying etiologies. Dermatitis. 2024;35:431–42.

Bruna Cavaleiro de Macedo Souza [a,*],
Laiza Bertolucci Ferrero [b],
Mariana de Figueiredo Silva Hafner [a],
Rosana Lazzarini [b]

[a] *Dermatology Clinic, Irmandade da Santa Casa de Misericórdia de São Paulo, São Paulo, SP, Brazil*
[b] *Faculty of Medical Sciences, Santa Casa de São Paulo, São Paulo, SP, Brazil*

* Corresponding author.
E-mail: dr.brunamacedo@gmail.com (B.C. Souza).

Received 11 December 2024; accepted 21 February 2025
Available online 4 August 2025

SOCIEDADE BRASILEIRA DE DERMATOLOGIA

Anais Brasileiros de Dermatologia

www.anaisdedermatologia.org.br

LETTER - RESEARCH

Expression of the aryl hydrocarbon receptor (AhR) in facial melasma skin compared to healthy perilesional skin☆

Dear Editor,

Melasma is a chronic, acquired hypermelanosis, most prevalent in adult women with intermediate skin types (III to V), especially in intertropical countries such as the Middle East, India, and Latin America.[1,2]

In the last decade, its prevalence has increased in Brazil.[3] A study that evaluated the volume of searches on the Google platform demonstrated a 54.4% global increase in interest in the topic since 2000; there is an association with the country's sunlight exposure, oral contraceptive use, and carbon dioxide emissions.[4]

The aryl hydrocarbon receptor (AhR) is a cytoplasmic protein that, when activated, undergoes nuclear translocation and acts as a regulatory transcription factor for the response to environmental stimuli and maintenance of cell homeostasis. It is expressed in various skin cell types, including keratinocytes, melanocytes, fibroblasts, sweat ducts, and hair follicles, participating in processes such as cell proliferation, differentiation, apoptosis, inflammation, and pigmentation.[5,6]

AhR can be activated by polychlorinated biphenyls, dioxins, or other polycyclic aromatic hydrocarbons (PAHs) present in environmental pollution, as well as endogenous metabolites induced by ultraviolet radiation. Activated AhR upregulates enzymes involved in the clearance of xenobiotics (such as CYP1A1, CYP1A2, CYP1B1, and UGT1A6). The activity of these enzymes results in the production of reactive oxygen species (ROS), inducing p38, which increases the activity of MITF (Microphthalmia-Associated Transcription Factor), regulating tyrosinase expression in melanocytes.[5–7]

Air pollution plays an important role in extrinsic aging. Synergistically with sun exposure and genetic factors, it may be a risk factor for the onset and maintenance of melasma pigmentation, due to the cutaneous penetration of PAHs and activation of AhR.[8] Since, to date, no study has evaluated the role of AhR in melasma, an investigation was conducted to compare its differential activation in melasma and adjacent healthy skin.

After approval by the ethics committee of the Botucatu School of Medicine - Unesp (n. 6,590,628), 20 adult women with facial melasma who had not been treated for more than 30 days underwent two skin biopsies (3 mm): one from the skin with facial melasma and the other from clinically healthy, adjacent skin, up to 2 cm from the lesion border.

After being paraffin embedded, the 40 specimens were stained with hematoxylin & eosin and submitted to immunohistochemistry (DAB) for Ki67 (clone MIB1, Dako, M7240, Glostrup, Denmark – 1/50) and for AhR (clone EPR7119(N)(2), ab190797, Abcam, Cambridge, MA – 1/100). All immunohistochemical reactions were performed manually, validated in the tissues indicated by the antibody package inserts, and titrated to the lowest concentration to avoid background staining (Supplementary Material).

The main outcome was the number of stained epidermal nuclei per x400 field, analyzed blindly regarding the topography (melasma or healthy skin). The entire epidermal sample was evaluated and counted for all participants. The staining of pilosebaceous units was also evaluated. The thickness of viable epidermis was assessed using three measurements in interfollicular areas. The epidermal proliferation rate was calculated using the HSCORE score of Ki67 nuclear staining. The HSCORE is a semiquantitative method for evaluating the immunohistochemical expression of proteins in the cell nucleus. It weights the percentage of stained cells and the intensity of staining (0 = absent, 1 = weak, 2 = moderate, 3 = strong).[9]

The variables were compared between topographies using a linear mixed-effects model, and significance was defined as $p < 0.05$. The sample size was based on the expectation of a difference between topographies of more than 10% of expression among the sampled skins (alpha 0.05 and beta 0.2).

The clinical and demographic data of the sample are shown in Table 1, and none of the participants were smokers. Immunohistochemical staining (Figs. 1 and 2) revealed higher nuclear AhR expression in the melasma epidermis compared with the adjacent healthy skin (1.3 vs. 1.1 nuclei/field; $p = 0.03$). There was no cytoplasmic AhR staining in the epidermis. In the pilosebaceous units, both nuclear

☆ Study conducted at the Faculty of Medicine, Universidade Estadual Paulista, Botucatu, SP, Brazil.

https://doi.org/10.1016/j.abd.2025.501181

Table 1 Main clinical and demographic information of female participants (n = 20 women).

Variables	Values
Age (years), mean (SD)	44.9 (9.2)
Phototype, n (%)	
II	8 (40%)
III	5 (25%)
IV-V	7 (35%)
Pregnancy history, n (%)	
Never	3 (15%)
1-2	11 (55%)
3 or more	6 (30%)
Use of oral contraceptives, n (%)	1 (5%)
Daily sun exposure, n (%)	7 (35%)
Family history of melasma, n (%)	15 (75%)
Age of onset of melasma, mean (SD)	33.3 (10.8)
mMASI, mean (SD)	4.0 (2.4)

mMASI, Modified Melasma Area and Severity Index.

and cytoplasmic staining were observed (Fig. 3), being more frequent in melasma than in the adjacent healthy skin (70% vs. 30%; p = 0.03). There was staining in the eccrine sweat gland ducts, in both topographies (p > 0.9).

The epidermis with melasma (Figs. 1 and 2) showed thinner epithelial thickness (187 vs. 207 μm; p < 0.01), but a higher proliferation rate (HSCORE 36 vs. 27; p = 0.02). There was no correlation between HSCORE, mMASI, epidermal thickness, and epithelial AhR expression (p > 0.3).

The higher expression of AhR in the epidermis and pilosebaceous units in melasma may indicate the involvement of environmental stimuli (especially pollution) in its pathogenesis and contribute to the higher prevalence of melasma in urban centers. Furthermore, ultraviolet light, particularly UVB, and exposure to visible light generate formylindole-(3,2-*b*)-carbazole, a high-affinity ligand and endogenous transcriptional activator of AhR, reinforcing the synergistic action of solar radiation on atmospheric pollutants.[10]

Microparticulate pollutants penetrate the skin through intracellular, intercellular pathways, and through hair

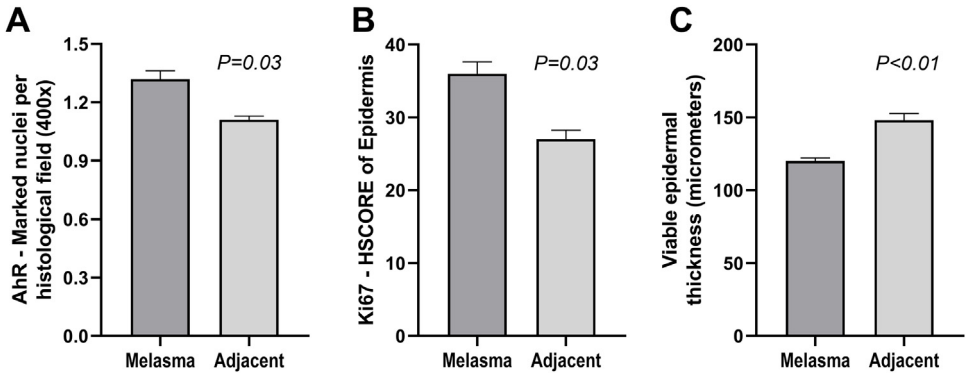

Figure 1 Comparative graphs of AhR nuclear expression in the epidermis (A), Ki67 score (B) and epithelial thickness (C) with melasma and adjacent healthy skin (n = 20).

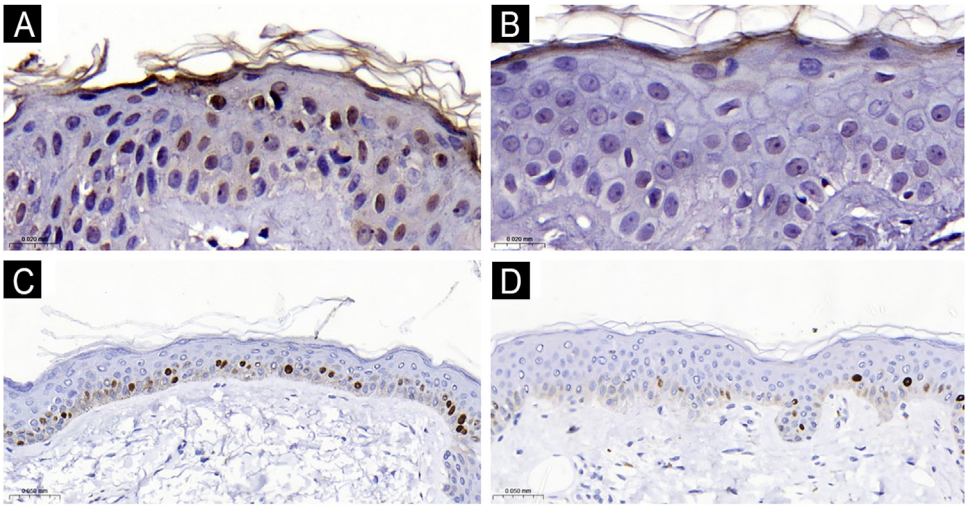

Figure 2 Epidermal nuclear expression of AhR (×1000): A. Melasma. B. Adjacent skin. Epidermal nuclear expression of Ki67 (×400): C. Melasma. D. Adjacent skin.

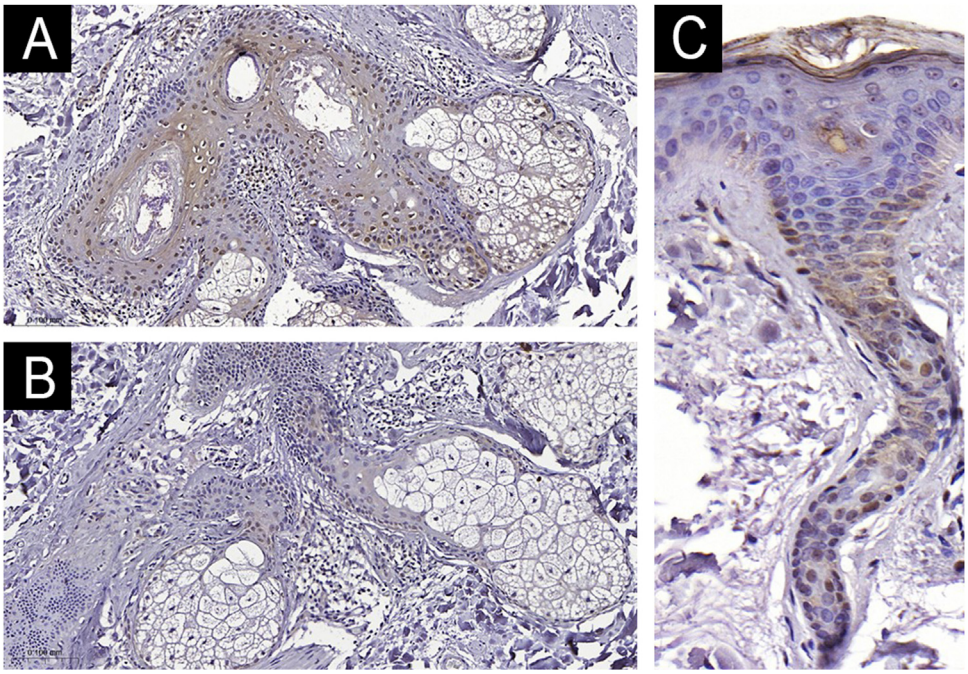

Figure 3 AhR expression in the pilosebaceous follicle (×200). A. Melasma. B. Adjacent skin. C. AhR expression in the eccrine sweat gland ducts (×400).

follicles and sweat glands. In melasma, there is impairment of the skin barrier and a reduction in epithelial thickness compared to the adjacent skin, which may favor the permeation of pollutants.[2] ROS generated by AhR activation contributes to oxidative damage to the epidermis and upper dermis. This inflammatory microenvironment accelerates collagen degradation and the secretion of inflammatory mediators that can induce persistent melanogenesis.[2,5,7]

AhR activation can mediate melanogenesis via the canonical or non-canonical pathway. In the canonical pathway, upon activation, AhR translocates to the nucleus, where it interacts with its heterodimerization partner ARNT (Aryl Hydrocarbon Receptor Nuclear Translocator), forming a complex that binds to specific DNA response elements, such as the xenobiotic response element. This results in the transcription of genes such as *CYP1A1* and *B1*, which influence melanin synthesis. The non-canonical pathway involves direct or indirect interactions of AhR with signaling proteins, independently of ARNT, including activation of intracellular kinases and pathways such as MAPK (Mitogen-Activated Protein Kinase). These pathways can promote the expression of pro-melanogenic factors, such as MITF, which induce melanin synthesis.[5–8,11] However, such melanogenic pathways have been demonstrated in cell cultures and murine models, and the present experiment was based on immunohistochemistry of paraffin-embedded tissue from dermatosis pigmentosa.

In addition to melanocytic hypertrophy, melasma shows structural alterations of the entire epidermis, upper dermis, and barrier function. Increased cell replication rates with thinner epithelial thickness may reflect the intense cell transit induced by growth and inflammatory factors in the upper dermis, which is structurally compromised in the disease. A similar phenomenon occurs in the atrophic epithelium of photoaging.[2,12]

The main limitations of this study are the modest sample size, slight differential staining, the inclusion of women only, and the lack of a functional study of the pathways activated by AhR. Furthermore, the use of manual immunohistochemistry with an experimental antibody can be considered a limitation. Further studies should explore the effect of AhR blockade on the suppression of melanogenesis and skin aging, as well as investigate possible melanogenic stimuli originating from the sebaceous glands in melasma.[13]

In conclusion, greater expression of AhR was observed in the epidermis and pilosebaceous units of melasma skin compared to adjacent skin, suggesting a role in its pathogenesis. The melasma epidermis also showed smaller thickness and a higher replication rate.

Financial support

Research Award - Exposome Grant 2022 Vichy.

Authors' contributions

Carolina Nunhez da Silva: Design and planning of the study; analysis and interpretation of data; drafting and editing of the manuscript; critical review of the literature; critical review of the manuscript; approval of the final version of the manuscript.

Tony Fernando Grassi: Analysis and interpretation of data; drafting and editing of the manuscript; collection of data; approval of the final version of the manuscript.

Hélio Amante Miot: Design and planning of the study; analysis and interpretation of data; statistical analysis;

drafting and editing of the manuscript; critical review of the literature; critical review of the manuscript; approval of the final version of the manuscript.

Ana Cláudia Cavalcante Espósito: Design and planning of the study; analysis and interpretation of data; drafting and editing of the manuscript; critical review of the literature; critical review of the manuscript; approval of the final version of the manuscript.

Conflicts of interest

None declared.

Research data availability

The entire dataset supporting the results of this study was published in this article.

Editor

Luciana P. Fernandes Abbade.

Appendix A Supplementary material.

Supplementary material related to this article can be found, in the online version, at doi:https://doi.org/10.1016/j.abd.2025.501181.

References

1. Dias MO, Minagawa FH, Teixeira de Abreu AF, Barbosa MMC, de Amorim RP, Esposito ACC, et al. Prevalence of facial melasma among adult women in a multiracial population. Int J Dermatol. 2024;63:e89–91.
2. Espósito ACC, Cassiano DP, da Silva CN, Lima PB, Dias JAF, Hassun K, et al. Update on melasma-part I: pathogenesis. Dermatol Ther (Heidelb). 2022;12:1967–88.
3. Miguel LMZ, Jorge MFS, Rocha B, Miot HA. Incidence of skin diseases diagnosed in a public institution: comparison between 2003 and 2014. An Bras Dermatol. 2017;92:423–5.
4. Esposito MCC, Esposito ACC, Lemos FK, Jorge MFS, D'Elia MPB, Miot HA. Melasma: trends in worldwide Internet searches (2000–2019). Indian J Dermatol Venereol Leprol. 2022;88:675–7.
5. Jux B, Kadow S, Luecke S, Rannug A, Krutmann J, Esser C. The aryl hydrocarbon receptor mediates UVB radiation-induced skin tanning. J Invest Dermatol. 2011;131:203–10.
6. Nakamura M, Ueda Y, Hayashi M, Kato H, Furuhashi T, Morita A. Tobacco smoke-induced skin pigmentation is mediated by the aryl hydrocarbon receptor. Exp Dermatol. 2013;22:556–8.
7. Nakamura M, Morita A, Seite S, Haarmann-Stemmann T, Grether-Beck S, Krutmann J. Environment-induced lentigines: formation of solar lentigines beyond ultraviolet radiation. Exp Dermatol. 2015;24:407–11.
8. Chan TK, Bramono D, Bourokba N, Krishna V, Wang ST, Neo BH, et al. Polycyclic aromatic hydrocarbons regulate the pigmentation pathway and induce DNA damage responses in keratinocytes, a process driven by systemic immunity. J Dermatol Sci. 2021;104:83–94.
9. Brianezi G, Minicucci EM, Marques ME, Miot HA. Evaluation epidermal p53 immunostaining by digital image analysis. Skin Res Technol. 2013;19:e108–12.
10. Rannug A, Rannug U. The tryptophan derivative 6-formylindolo[3,2-*b*]carbazole, FICZ, a dynamic mediator of endogenous aryl hydrocarbon receptor signaling, balances cell growth and differentiation. Crit Rev Toxicol. 2018;48:555–74.
11. Vogeley C, Esser C, Tuting T, Krutmann J, Haarmann-Stemmann T. Role of the aryl hydrocarbon receptor in environmentally induced skin aging and skin carcinogenesis. Int J Mol Sci. 2019;20:6005.
12. Esposito ACC, Brianezi G, de Souza NP, Miot LDB, Miot HA. Exploratory study of epidermis, basement membrane zone, upper dermis alterations and WNT pathway activation in melasma compared to adjacent and retroauricular skin. Ann Dermatol. 2020;32:101–8.
13. Flori E, Mastrofrancesco A, Mosca S, Ottaviani M, Briganti S, Cardinali G, et al. Sebocytes contribute to melasma onset. iScience. 2022;25:103871.

Carolina Nunhez da Silva [a], Tony Fernando Grassi [b], Hélio Amante Miot [a,*], Ana Cláudia Cavalcante Espósito [a,c]

[a] *Department of Infectious Diseases, Dermatology, Imaging Diagnosis and Radiotherapy, Faculty of Medicine, Universidade Estadual Paulista, Botucatu, SP, Brazil*
[b] *Laboratório GENOTOX, Faculty of Medicine, Universidade Estadual Paulista, Botucatu, SP, Brazil*
[c] *Faculty of Medicine, Universidade do Oeste Paulista, Presidente Prudente, SP, Brazil*

* Corresponding author.
E-mail: heliomiot@gmail.com (H.A. Miot).

Received 6 January 2025; accepted 26 March 2025
Available online 13 August 2025

SOCIEDADE BRASILEIRA DE DERMATOLOGIA

Anais Brasileiros de Dermatologia

www.anaisdedermatologia.org.br

LETTER – RESEARCH

Revisiting a century of dermatology: an analysis of the themes in the articles of Anais Brasileiros de Dermatologia (1925–2025)☆

Dear Editor,

Anais Brasileiros de Dermatologia (ABD) constitute the main scientific journal of the Brazilian Society of Dermatology (SBD, *Sociedade Brasileira de Dermatologia*). Published since 1925, they play a fundamental role in disseminating knowledge in the field, contributing to professionals' training and updating, in addition to providing a platform for the dissemination of original research, reviews, and relevant clinical cases.[1]

The ABD is indexed in the main international databases, making it the most influential dermatology journal in Latin America, and the only one indexed in the ISI-Web of Science database, which calculates journal impact factors.[2]

Over a century of its publication, the ABD has accumulated more than six thousand articles authored by more than ten thousand researchers. These studies have tracked changes in clinical practice, the emergence of new diseases, and technological innovations, consolidating the journal as an essential reference for dermatologists and researchers.[3] At the same time, the ABD underwent adjustments to its editorial policy to adapt to the demands of a modern, dynamic journal with international reach and high scientific rigor.[4,5]

Analysis of the titles of articles published in the ABD over time allows us to understand changes in dermatological practice and reflect epidemiological and social trends, as well as scientific advances of each period. This study aimed to conduct qualitative bibliometric research on the topics addressed in articles published by the ABD between 1925 and 2025.

The titles of articles published in the ABD between 1925 and April 1, 2025, were extracted from the website http://www.anaisdedermatologia.com.br/edicoes-anteriores. The articles were grouped into four periods: 1925–1950, 1951–1975, 1976–2000, and 2001–2025. The titles were normalized for grammatical uniqueness, and spelling variations (such as "syphilis" and "sífilis") and related terms (such as "leprosy," "*hanseníase*," and "*hansênico*") were manually identified. Generic words (such as "patient," "dermatosis," and "treatment"), prepositions, articles, conjunctions, and adverbs were excluded using ChatGPT 4.0®, which was also used to translate the titles available exclusively in English. The term groups were processed by WordArt (http://www.wordart.com/create) to generate word clouds with the most frequent terms (up to 100), which were identified in more than 1% of the titles.[6]

The frequencies of the 20 most frequently identified diseases in the titles were compared across the four periods using residual analysis corrected by the Holm-Bonferroni procedure.[7] Significance was defined as $p < 0.05$.

The distribution of the 150 most frequent themes in each period is represented in the word clouds in Fig. 1. In the first period (1925–1950), infectious diseases such as treponematoses (syphilis, yaws, and pinta), lymphogranuloma venereum, leprosy, paracoccidioidomycosis, and leishmaniasis stood out. Arsenotherapy was used to treat treponematoses and leishmaniasis. Pemphigus foliaceus was the most important inflammatory disease.

In the second period, infectious diseases continued to predominate, including leprosy, syphilis, leishmaniasis, paracoccidioidomycosis, chromomycosis, sporotrichosis, lobomycosis, and superficial mycoses. The introduction of penicillin changed the treatment of treponematoses, while corticosteroids and sulfones began to be used for inflammatory diseases and leprosy. Diseases such as eczema and psoriasis became more commonly cited.

In the third period, infectious diseases such as leprosy, leishmaniasis, and paracoccidioidomycosis still predominated. Psoriasis gained prominence, as did melanoma, carcinomas, and scabies. The HIV epidemic at the end of the last century stands out.

In the last period, psoriasis and neoplasms gained prominence over infectious diseases. Articles appeared on dermatoscopy, micrographic surgery, alopecia areata, and immunobiologicals. Articles involving COVID-19 in the last five years stand out.

Table 1 depicts the frequencies of the 20 diseases most frequently mentioned in article titles over time, highlighting

☆ Study conducted at the Department of Infectology, Dermatology, Imaging Diagnosis and Radiotherapy, Faculty of Medicina, Universidade Estadual Paulista, Botucatu, SP, Brazil.

https://doi.org/10.1016/j.abd.2025.501197

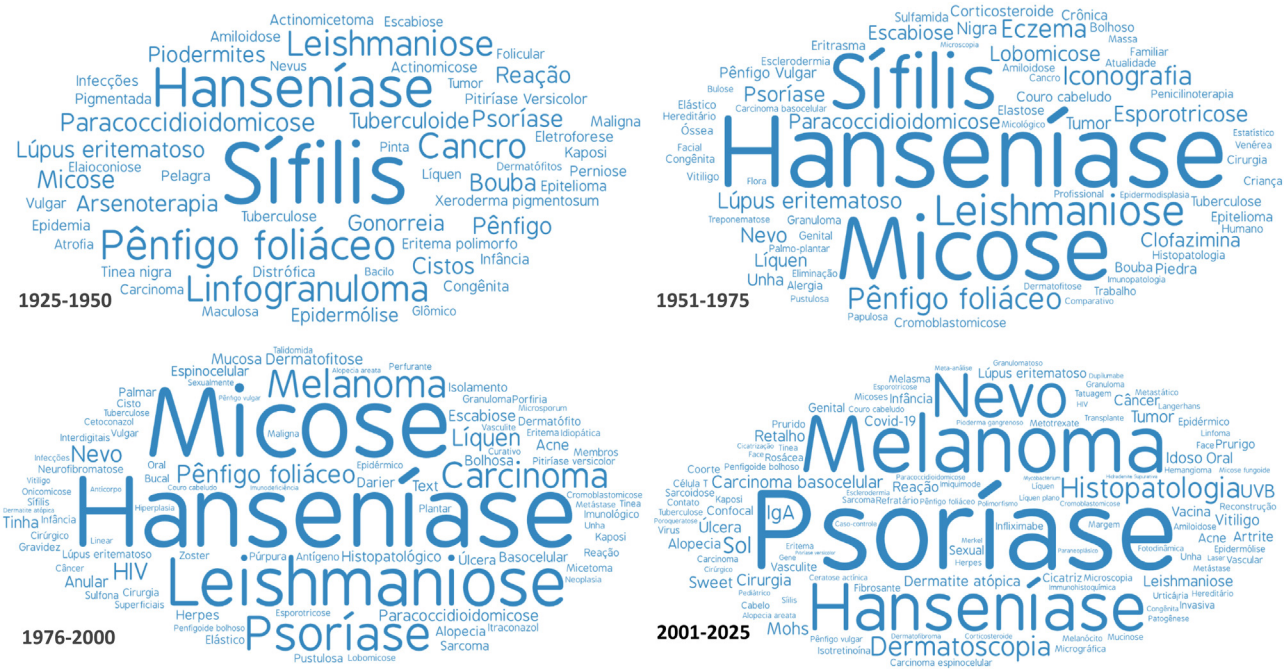

Fig. 1 Word clouds representing the most frequently used terms in the titles of articles published in the *Anais Brasileiros de Dermatologia* in the four periods: 1925–1950, 1951–1975, 1976–2000, 2000–2025. The size of the words is proportional to their frequency of occurrence.

Table 1 Frequency of the 20 most commonly identified groups of dermatoses among the titles of articles in the *Anais Brasileiros de Dermatologia* (1925–2025).

Disease	1925 to 1950 (n = 250)	1951 to 1975 (n = 468)	1975 to 2000 (n = 1.444)	2001 to 2025[a] (n = 3.867)
Acne	1 (0.4%)	2 (0.4%)	18 (1.2%)	60 (1.6%)
Alopecia areata	0 (-)	0 (-)	6 (0.4%)	32 (0.8%)
Atopic dermatitis	0 (-)	3 (0.6%)	7 (0.5%)	61 (1.6%)
Basal cell carcinoma	0 (-)	3 (0.6%)	15 (1.0%)	81 (2.1%)
Scabies	2 (0.8%)	7 (1.5%)	18 (1.2%)	11 (0.3%)
Sporotrichosis	1 (0.4%)	9 (1.9%)	11 (0.8%)	27 (0.7%)
Leprosy	21 (8.4%)	28 (6.0%)	64 (4.4%)	125 (3.2%)
Herpes simplex	0 (-)	0 (-)	6 (0.4%)	11 (0.3%)
Leishmaniasis	8 (3.2%)	15 (3.2%)	62 (4.3%)	75 (1.9%)
Lupus erythematosus	2 (0.8%)	6 (1.3%)	14 (1.0%)	42 (1.1%)
Melanoma	0 (-)	1 (0.2%)	25 (1.7%)	160 (4.1%)
Superficial Mycosis	5 (2.0%)	24 (5.1%)	63 (4.4%)	47 (1.2%)
Paracoccidioidomycosis	9 (3.6%)	8 (1.7%)	28 (1.9%)	25 (0.6%)
Bullous pemphigoid	0 (-)	1 (0.2%)	6 (0.4%)	28 (0.7%)
Pemphigus foliaceus	8 (3.2%)	12 (2.6%)	22 (1.5%)	23 (0.6%)
Psoriasis	5 (2.0%)	8 (1.7%)	38 (2.6%)	197 (5.1%)
Syphilis	46 (18.4%)	14 (3.0%)	12 (0.8%)	26 (0.7%)
Urticaria	0 (-)	1 (0.2%)	3 (0.2%)	42 (1.1%)
Vitiligo	1 (0.4%)	3 (0.6%)	9 (0.6%)	71 (1.8%)
Zoster	0 (-)	2 (0.4%)	12 (0.8%)	5 (0.1%)

[a] Data up to 04/01/2025; Cells in GREEN: lowest frequency ($p < 0.05$); Cells in RED: highest frequency ($p < 0.05$).

the significant increase in the number of publications in the last period and the variation in the frequency of references to these diseases over time.

In the last century, Brazil underwent an epidemiological transition marked by a reduction in infectious diseases as well as an increase in chronic non-communicable diseases and neoplasms, driven by population aging and lifestyle changes. This process occurred in parallel with social and cultural transformations, such as accelerated urbanization, improved sanitation, and advances in medical science.[8]

Penicillin arrived in Brazil in the 1950s, which may explain the reduction in publications on treponematoses from the

third period onward. Similarly, multidrug therapy for leprosy was instituted in 1986, drastically reducing its morbidity and prevalence, reflecting lower numbers of publications in the last period.

Immunobiologicals, which revolutionized psoriasis, have been available in Brazil since the first decade of the millennium, which may explain the recent increase in publications on the disease. The same can be said for modern treatments for atopic dermatitis, urticaria, vitiligo, and alopecia areata.

The progressively greater longevity of the population and the development of Brazilian dermatological surgery over the last 50 years may be reasons for the progressive increase in the frequency of publications in oncology and bullous pemphigoid.

Between the 1960s and 1980s, cases of sporotrichosis emerged in the Southeast region, mainly among farmers and vegetable handlers, sparking the interest of dermatologists. The increasing urbanization of the Brazilian population, associated with the availability of effective outpatient treatments, may explain the recent reduction in publications on paracoccidioidomycosis, pemphigus foliaceus, and leishmaniasis.

The reduced prominence of infectious diseases, despite the greater focus on inflammatory dermatoses and neoplasms, reflects not only changes in disease epidemiology but also research funding priorities.[6,9] Over time, the frequency of these topics in medical journals illustrates the dynamic nature of medicine, where public health demands and pharmaceutical advances drive scientific discourse.[10]

Finally, ABD publications have accompanied global health crises, such as syphilis, AIDS, and the COVID-19 pandemic. Similarly, they have reflected the evolution of therapies for venereal diseases, leishmaniasis, leprosy, psoriasis, atopic dermatitis, and alopecia areata.

This study has limitations related to the individual analysis of terms without assessing their semantic relationships, variations in medical terminology, and editorial rules over time. Future studies should be conducted based on the analysis of full texts, considering their impact, citations, and types of publication, for a more detailed understanding of the variations in editorial practices in Brazilian dermatology.

In conclusion, given the scenario of constant scientific evolution, understanding the trends in academic production allows not only revisiting the trajectory of Brazilian dermatology but also identifying knowledge gaps and directing future research to meet the emerging demands of the specialty.

Financial support

CNPq (306358/2022-0) – Hélio Amante Miot is a CNPq research fellow.

Authors' contributions

Hélio Amante Miot: Design and planning of the study; analysis and interpretation of data; statistical analysis; drafting and editing of the manuscript; critical review of the literature; critical review of the manuscript; approval of the final version of the manuscript.

Thays Herbst Carvalho: Collection of data; analysis and interpretation of data; statistical analysis; drafting and editing of the manuscript; critical review of the literature; critical review of the manuscript; approval of the final version of the manuscript.

Aluísio José de Oliveira Monteiro Neto: Collection of data; analysis and interpretation of data; drafting and editing of the manuscript; critical review of the literature; critical review of the manuscript; approval of the final version of the manuscript.

Laís Acioli Lins: Collection of data; analysis and interpretation of data; drafting and editing of the manuscript; critical review of the literature; critical review of the manuscript; approval of the final version of the manuscript.

Milena Aguiar Alencar de Oliveira: Collection of data; analysis and interpretation of data; drafting and editing of the manuscript; critical review of the literature; critical review of the manuscript; approval of the final version of the manuscript.

Mateus Harmad Char: Collection of data; analysis and interpretation of data; drafting and editing of the manuscript; critical review of the literature; critical review of the manuscript; approval of the final version of the manuscript.

Research data availability

The entire dataset supporting the results of this study was published in this article.

Editor

Hiram Larangeira de Almeida Jr.

Conflicts of interest

None declared.

References

1. Costa IM, Vallarelli AF, Bonamigo RR, Reis VM. Historical evolution of the Brazilian Annals of Dermatology. An Bras Dermatol. 2012;87:13–92.
2. Miot HA, Criado PR, Castro CCS, Ianhez M, Talhari C, Ramos PM. Bibliometric evaluation of anais brasileiros de dermatologia (2013-2022). An Bras Dermatol. 2024;99:90–9.
3. Marques SA, Roselino AMF, Almeida Junior HL, Abbade LPF. Anais brasileiros de dermatologia: 100 years of history (1925–2025). An Bras Dermatol. 2025;100:3–11.
4. Marques SA, Roselino AM, Almeida HLJ, Abbade LPF. Anais brasileiros de dermatologia: new challenges. New guidelines for authors. An Bras Dermatol. 2021;96:261–2.
5. Marques SA, Roselino AM, Almeida HL Jr, Abbade LPF. Anais brasileiros de dermatologia: updating guidelines for authors. An Bras Dermatol. 2023;98:1–2.
6. Perez S, Laperriere V, Borderon M, Padilla C, Maignant G, Oliveau S. Evolution of research in health geographics through the international journal of health geographics (2002-2015). Int J Health Geogr. 2016;15:3.
7. Miola AC, Miot HA. Comparing categorical variables in clinical and experimental studies. J Vasc Bras. 2022;21:e20210225.
8. Prata PR. The epidemiologic transition in Brazil. Cad Saude Publica. 1992;8:168–75.

9. Atenstaedt RL. Word cloud analysis of historical changes in the subject matter of public health practice in the United Kingdom. Public Health. 2021;197:39–41.
10. Legg T, Hatchard J, Gilmore AB. The science for profit model-how and why corporations influence science and the use of science in policy and practice. PLoS One. 2021;16:e0253272.

Thays Herbst Carvalho,
Aluísio José de Oliveira Monteiro Neto,
Laís Acioli Lins, Milena Aguiar Alencar de Oliveira,
Mateus Harmad Char, Hélio Amante Miot *

Department of Infectology, Dermatology, Imaging Diagnosis and Radiotherapy, Faculty of Medicina, Universidade Estadual Paulista, Botucatu, SP, Brazil

* Corresponding author.
E-mail: heliomiot@gmail.com (H.A. Miot).

Received 3 April 2025; accepted 2 June 2025
Available online 20 August 2025

SOCIEDADE BRASILEIRA DE DERMATOLOGIA

Anais Brasileiros de Dermatologia

www.anaisdedermatologia.org.br

LETTER - RESEARCH

Sporotrichosis in Amazon: series of 46 cases with emphasis on zoonotic transmission☆

Dear Editor,

Sporotrichosis is a chronic, granulomatous, subcutaneous fungal infection caused by fungi of the genus *Sporothrix*.[1,2] Transmission occurs mainly through direct contact with contaminated soil or organic matter[3,4] and through interaction with infected animals, especially cats.[1] Sporotrichosis can manifest cutaneously or extracutaneously, mainly in immunocompromised patients.[5]

This is a descriptive and observational study carried out at the Dermatology Service of Universidade do Estado do Pará, a reference in secondary care for dermatological diseases in the North region, between April 2022 and June 2024, related to 46 patients with sporotrichosis. The research was approved by the Research Ethics Committee of the University (Opinion n. 5.647.696/2022). The present study followed the CARE checklist for case reports and series. Data collection was performed through medical records, including demographic information, clinical characteristics, and treatment details.

Of the 46 patients, there was a predominance of females (71.7%), probably due to the fact that women are usually the main caregivers of animals, increasing the risk of contamination. Age ranged from 6 to 85 years, with a mean of 41.3 years (Fig. 1). All participants were considered immunocompetent at the time of diagnosis.

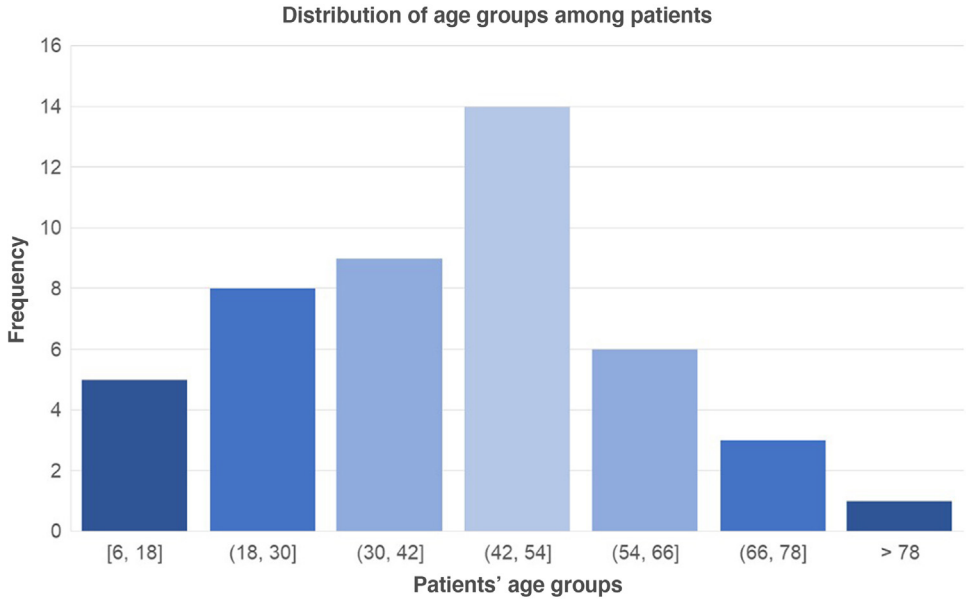

Figure 1 Distribution of age groups among patients diagnosed with sporotrichosis between April 2022 and June 2024 at a reference center in the Northern Region of Brazil.

☆ Study conducted at the Dermatology Outpatient Clinic Prof. Miguel Saraty de Oliveira, Centro de Ciências Biológicas e da Saúde II (CCBS-II), Universidade do Estado do Pará, Belém, PA, Brazil.

https://doi.org/10.1016/j.abd.2025.501171

Figure 2 Patient with the lymphocutaneous form of sporotrichosis.

Regarding epidemiology, 15.2% (n = 7) reported previous contact with soil or decomposing organic matter, while 95.5% (n = 44) reported contact with cats. Of these, 76% (n = 35) indicated recent scratches or bites, and 36.9% (n = 17) mentioned contact with cat secretions.

Histopathological examination was performed on 78.2% of the samples (n = 36), with reports suggestive or diagnostic of sporotrichosis. In 62.5% of the cases (n = 28), a culture was performed and confirmed in 32.6% (n = 15).

The skin lesions ranged from nodules to ulcers, with predominance in the extremities. In 28.3% of the cases (n = 13), concomitant involvement of lymphatic chains was observed. The localized cutaneous form was the most frequent one (69.5%), followed by the lymphocutaneous (28.3%; Fig. 2) and the severe/disseminated form (2.2%).

The evaluation of the animals showed that 63.6% of the felines (n = 28) had received a clinical veterinary diagnosis, and/or with the aid of direct mycological examination, of sporotrichosis. Information on clinical outcomes was obtained for 16 animals: 5 (31.2%) were euthanized due to the severity of the condition, 6 (37.5%) received successful treatment with itraconazole, and 5 (31.3%) died without veterinary intervention.

The medication prescribed in 93.5% of human cases (n = 43) was itraconazole, with doses ranging between 100 mg and 200 mg daily. In 4.5% of cases, potassium iodide (KI) was used due to the patients' age (children, with doses between 1.4 and 2.1 g/day). Treatment lasted up to six months in 46% of patients, resulting in complete healing of the lesions. Adverse effects of itraconazole were reported by only three patients (6.9%) – myalgia, vertigo, requiring replacement by Terbinafine, with satisfactory response.

Regarding prognosis, 79% of cases (n = 36) showed healing of the lesions. Eight patients did not return for follow-up, and two are still being followed. In general, healing occurred between two and four months after the start of treatment. Outpatient discharge was recorded in 94.1% of cases, with complete healing and no recurrence or treatment failures.

Figure 3 Patient with the fixed cutaneous form of sporotrichosis.

Clinically, the most common form observed was the fixed or localized cutaneous form (Fig. 3), with predominant lesions being ulcers, nodules, and erythematous-infiltrated plaques. This difference in relation to other studies[6] can be attributed to the higher number of immunocompetent patients in this study and early access to medical care. The diagnostic methods most often used in the present study were culture of the material and histopathological analysis, with culture on Sabouraud Dextrose Agar being considered the gold standard.[7] Moreover, 12 of the 27 cases showed a negative culture, despite presenting suggestive histopathology. It is worth noting that some patients were already undergoing treatment at the time of diagnosis, which may have influenced the culture results.

The results of this study (Table 1) highlighted the variety of clinical presentations and characteristics of the lesions, the good efficacy of the treatment used, the relatively short healing time (less than six months for 46% of patients), and the cure outcome. The positive therapeutic response to itraconazole in all cases reinforces the drug efficacy,[8] already well established in national protocols.

Since the 1990s, interaction with infected felines has been widely associated with the increased incidence of cases in Brazil,[2,9] accounting for 95.5% of the reported causes of infection.[10] This finding is corroborated by the data from the present study, which identified this route of transmission in 44 patients (95.5%).

Transmission occurs mainly through scratches, bites or contact with respiratory secretions from infected cats,[4,9] affecting especially veterinarians, owners, or animal rescue activists. Sanitary measures, veterinary control, and keeping felines in safe environments, without access to the street, are essential to reduce transmission between felines and humans.

The limitations of this research include the sample being restricted to a single center and the lack of prolonged follow-up of some patients. The need for accurate diagnostic methods and awareness of the disease is essential to prevent morbidity and sequelae. The lack of mandatory reporting in some states,[7] such as Pará, and the lack of knowledge of the disease among physicians contribute to underreporting, impacting public control policies.

Table 1 Clinical-epidemiological data of patients diagnosed with sporotrichosis between April 2022 and June 2024 from a reference center in the Northern Region of Brazil.

Clinical-epidemiological data		Total	(%)
Sex	Male	13	27,3%
	Female	33	71,7%
Origin	Metropolitan Region of Belém	2	4,3%
	Belém	44	95,7%
Feline exposure	Yes	44	95,5%
	No	2	4,5%
Scratch, bite or contact with/secretions		37	84%
Diagnostic confirmation in the feline		28	63,6%
Feline under treatment		6	21,4%
Clinical form	Localized cutaneous	32	69,5%
	Lymphocutaneous	13	28,3%
	Severe/disseminated	1	2,2%
Medication	Itraconazole	43	93,5%
	Potassium Iodide	3	4,5%
Healing time after starting the treatment[a]	< 3 months	10	22%
	< 6 months	21	46%
	> 6 months	5	11%

[a] 8 patients lost to follow-up/2 patients still being followed.

Research data availability

The data that support the findings of this study are available from the corresponding author upon reasonable request.

Editor

Sílvio Alencar Marques.

Financial support

This study was funded by CNPq (*Conselho Nacional de Desenvolvimento Científico e Tecnológico*) and FAPESPA (*Fundação Amazônia de Amparo a Estudos e Pesquisas*) through PIBIC (*Programa Institucional de Bolsas de Iniciação Científica*) N. 026/2023 – Universidade do Estado do Pará (UEPA).

Authors' contributions

Luiza Rennó Rocha de Oliveira: Collection of data, or analysis and interpretation of data; statistical analysis; drafting and editing of the manuscript or critical review of important intellectual content; collection, analysis and interpretation of data; critical review of the literature; approval of the final version of the manuscript.

Isabela de Nazaré Tavares Cardoso Souza: Collection of data, or analysis and interpretation of data; statistical analysis; drafting and editing of the manuscript or critical review of important intellectual content; collection, analysis and interpretation of data; critical review of the literature; approval of the final version of the manuscript.

Murilo dos Santos Souza: Collection of data, or analysis and interpretation of data; statistical analysis; drafting and editing of the manuscript or critical review of important intellectual content; collection, analysis and interpretation of data; critical review of the literature; approval of the final version of the manuscript.

Carla Andrea Avelar Pires: Design and planning of the study; effective participation in research orientation; intellectual participation in the propaedeutic and/or therapeutic conduct of the studied cases; critical review of the literature; approval of the final version of the manuscript.

Maria Amélia Lopes dos Santos: Design and planning of the study; effective participation in research orientation; intellectual participation in the propaedeutic and/or therapeutic conduct of the studied cases; critical review of the literature; approval of the final version of the manuscript.

Francisca Regina Oliveira Carneiro: Design and planning of the study; effective participation in research orientation; intellectual participation in the propaedeutic and/or therapeutic conduct of studied cases; critical review of the literature; approval of the final version of the manuscript.

Conflicts of interest

None declared.

References

1. Orofino-Costa R, de Macedo PM, Rodrigues AM, Bernardes-Engemann AR. Sporotrichosis: an update on epidemiology, etiopathogenesis, laboratory and clinical therapeutics. An Bras Dermatol. 2017;92:606–20.
2. Hernández-Castro R, Pinto-Almazán R, Arenas R, Sánchez-Cárdenas CD, Espinosa-Hernández VM, Sierra-Maeda KY, et al. Epidemiology of clinical sporotrichosis in the Americas in the last ten years. J Fungi (Basel). 2022;8:588.
3. Rasamoelina T, Raharolahy O, Rakotozandrindrainy N, Ranaivo I, Andrianarison M, Rakotonirina B, et al. Chromoblastomycosis and sporotrichosis, two endemic but neglected fungal infections in Madagascar. J Mycol Med. 2017;27:312–24.

4. Schechtman RC, Falcão EMM, Carard M, García MSC, Mercado DS, Hay RJ. Sporotrichosis: hyperendemic by zoonotic transmission, with atypical presentations, hypersensitivity reactions and greater severity. An Bras Dermatol. 2022;97:1–13.
5. Falcão EMM, de Lima Filho JB, Campos DP, Valle ACF do, Bastos FI, Gutierrez-Galhardo MC, et al. Hospitalizações e óbitos relacionados à esporotricose no Brasil (1992-2015). Cad Saúde Pública. 2019;35:e00109218.
6. Caus ALO, Zanotti RL, Faccini-Martínez ÁA, Paterlini GV, Falqueto A. Epidemiological and Clinical Aspects of Sporotrichosis in Espírito Santo State, Southeast Brazil: A Study of Three Decades (1982–2012). Am J Trop Med Hyg. 2019;100:706–13.
7. Veasey JV, Carvalho GSM, Ruiz LRB, Neves Neto MF, Zaitz C. Epidemiological and geographical distribution profile of urban sporotrichosis in the city of São Paulo. An Bras Dermatol. 2022;97:228–30.
8. Sharma R, Mahajan VK, Singh Chauhan P, Mehta KS, Sharma A, Sharma J. The clinico-epidemiological characteristics and therapeutic experience of 152 patients with cutaneous sporotrichosis: a 10-year retrospective study from India. Int J Dermatol. 2021;60:99–106.
9. Lecca LO, Paiva MT, de Oliveira CSF, Morais MHF, de Azevedo MI, Bastos CVE, et al. Associated factors and spatial patterns of the epidemic sporotrichosis in a high density human populated area: a cross-sectional study from 2016 to 2018. Prev Vet Med. 2020;176:104939.
10. Tirado-Sánchez A, Bonifaz A. Nodular Lymphangitis (Sporotrichoid Lymphocutaneous Infections). Clues to Differential Diagnosis. J Fungi (Basel). 2018;4:56.

Luiza Rennó Rocha de Oliveira [a,*],
Isabela de Nazaré Tavares Cardoso Souza [b],
Murilo dos Santos Souza [b],
Carla Andrea Avelar Pires [a],
Maria Amélia Lopes dos Santos [a],
Francisca Regina Oliveira Carneiro [a]

[a] *Service of Dermatology, Universidade do Estado do Pará, Belém, PA,Brazil*
[b] *Universidade do Estado do Pará, Belém, PA, Brazil*

[*] Corresponding author.
E-mail: luiza.renno@hotmail.com
(L. Rennó Rocha de Oliveira).

Received 21 December 2024; accepted 5 March 2025
Available online 9 August 2025

Anais Brasileiros de Dermatologia 2025;100(5):501188

SOCIEDADE BRASILEIRA DE DERMATOLOGIA

Anais Brasileiros de Dermatologia

www.anaisdedermatologia.org.br

LETTER - RESEARCH

Use of biologics in pediatric-onset hidradenitis suppurativa: a case series☆

Dear Editor,

Recent literature reveals a bimodal distribution of Hidradenitis Suppurativa (HS), with the first peak occurring in late adolescence and the second in the fourth decade of life. Most publications focus on adulthood, with limited research addressing pediatric HS,[1,2] particularly concerning the use of biological agents in this population.[2–4]

Aiming to add further data to this topic, we performed a retrospective analysis of patients diagnosed with HS under the age of 18 at a Portuguese tertiary university hospital, selecting those who initiated their first biologic before adulthood.

Twelve patients were included in the analysis (8 female, 67%), with a median age at diagnosis of 16 years (range 10–17 years). The median time from symptom onset to diagnosis was 27 months (IQR 14–34.3-months), and the median follow-up duration was 6-years (IQR 3–8.8-years). At diagnosis, 67% (n = 8) were classified as Hurley Stage III, 25% (n = 3) as Stage II, and 8% (n = 1) as Stage I. Additional clinical characteristics and previous therapies are available in Table 1. Regarding biologic therapy, adalimumab was administered to all 12 patients, ustekinumab to 4 patients (33%), and infliximab and secukinumab, each to 3 patients (25%). A mean of 2 biologics were administered per patient (range 1–4). The median age for starting biologic therapy was 16.5 years, with therapy initiated before age 18 in all adalimumab patients (ages 11 to 17), in 2 out of 4 ustekinumab patients (both aged 17), and in 2 out of 3 infliximab patients (aged 13 and 17). Secukinumab therapy was initiated during adulthood. Adalimumab (n = 12) had primary failure (no response at week 16) in 17% of cases (2 patients), secondary failure in 50% (6 patients, median duration 24 months), and maintained efficacy in 33% (4 patients, median follow-up 36 months). Ustekinumab (n = 4) exhibited primary failure in 1 patient, with maintained efficacy in the remaining 3 (with a median follow-up of 23-months). Infliximab (n = 3) showed secondary failure in all 3 cases (median duration of 18 months), and secukinumab (n = 3) exhibited primary failure in 1 patient, with maintained efficacy in the remaining 2 (with a median follow-up of 12 months). Complete results are shown in Table 2. Dose intensification of adalimumab, from 40 mg to 80 mg/weekly, was attempted in 5 patients, without therapeutic benefit. Overall, 42% (n = 5) of patients on biologics achieved controlled disease – defined as improvement from severe to mild in the Hidradenitis Suppurativa Severity Score System (IHS4), while 33% (n = 4) achieved partial control – IHS4 improvement from severe to moderate, and 25% (n = 3) had uncontrolled disease (no IHS4 improvement). While on biologic, 83% of patients underwent HS surgery (n = 10), with the same percentage requiring oral antibiotics (n = 10), 33% requiring oral corticosteroids (n = 4), and 25% oral retinoids (n = 3). None of the patients submitted to surgery discontinued biologic therapy before the intervention, and all reported local improvement in their condition following the procedure. Finally, we matched our cohort with 16 pediatric-onset HS patients from our center who did not require biologic therapy, for comparison of baseline clinical characteristics. These groups displayed no significant differences regarding sex, age, and age at diagnosis. Patients in the biologic group displayed higher

Table 1 Clinical characteristics and previous therapies of the pediatric-onset hidradenitis suppurativa patients treated with biologics (n = 12).

Clinical data	n (%)
Comorbidities	
Overweight/obesity	10 (83%)
Severe acne	5 (42%)
Pilonidal sinus	4 (33%)
Affected locations	
Inguinal	12 (100%)
Axillary	10 (83%)
Perineal	7 (58%)
Intermammary	4 (33%)
Previous Treatments	
Oral antibiotics	12 (100%)
Contraceptive Pill (Female patients, n = 8)	5 (63%)
Oral retinoids	5 (42%)
Dapsone	3 (25%)

☆ Study conducted at the University of Porto, Porto, Portugal.

https://doi.org/10.1016/j.abd.2025.501188

Table 2 Biologic therapies and treatment outcomes in the 12 pediatric-onset hidradenitis suppurativa patients.

Biologic Agent	n (%)	Age Range at Start (years)	Initiated before 18 (n)	Median duration (months)	Primary failure, n (%)	Secondary failure, n (%)	Maintained Efficacy, n (%)
Adalimumab	12 (100)	11–17	12	24	2 (17%)	6 (50%)	4 (33%)
Ustekinumab	4 (33)	17–24	2	21	1 (25%)	–	3 (75%)
Infliximab	3 (25)	13–23	2	18	–	3 (100%)	–
Secukinumab	3 (25)	18–26	0	6	1 (33%)	–	2 (67%)

Hurley scores at diagnosis ($p < 0.001$), more perineal involvement ($p = 0.03$), and higher probability of undergoing surgery ($p = 0.005$).

The use of biologics in pediatric-onset HS remains underreported. A recent systematic review of medical treatments in pediatric HS included 33 patients treated with biologics,[4] with 12 derived from a single study,[3] and the remainder from case reports or small case series. Clinical improvement was reported in 94% of patients receiving biologic therapy, a higher response rate than observed in our cohort. This discrepancy may partially reflect shorter follow-up durations and potential positive publication bias in published case reports. In our cohort, a noteworthy need for additional therapies was also observed among patients on biologics, including oral antibiotics, corticosteroids, and retinoids. Despite this, our findings reinforce the efficacy and significant role of biologics, namely adalimumab, in this population, although no benefit was noted with dose escalation. Ustekinumab, though off-label, also appears to be a valid therapeutic option for adolescents. Surgery is increasingly recognized as a complementary therapeutic approach alongside medical therapy, enabling further management of HS lesions following initial improvement achieved with biologics, with positive results in our patients. Nevertheless, our data additionally reveal a striking prevalence of overweight/obesity in this pediatric population, which should be addressed, and a significant diagnostic delay, with a median of 27-months from symptom onset to diagnosis, and most patients already displaying severe disease at this time. This highlights the need for earlier recognition, facilitating timely access to these therapies, with the goal of avoiding disease progression and reducing cumulative damage.

Research data availability

The data that support the findings of this study are available from the corresponding author upon reasonable request.

Editor

Hiram Larangeira de Almeida Jr.

Financial support

This research received no specific grant from any funding agency in the public, commercial, or not-for-profit sectors.

Authors' contributions

Gilberto Pires da Rosa: The study concept and design, data collection, or analysis and interpretation of data, statistical analysis, writing of the manuscript or critical review of important intellectual content, critical review of the literature, final approval of the final version of the manuscript.

Sofia Magina: The study concept and design, effective participation in the research guidance, intellectual participation in the propaedeutic and/or therapeutic conduct of the studied cases, and final approval of the final version of the manuscript.

Carmen Lisboa: The study concept and design, effective participation in the research guidance, intellectual participation in the propaedeutic and/or therapeutic conduct of the studied cases, and final approval of the final version of the manuscript.

Filomena Azevedo: The study concept and design, effective participation in the research guidance, intellectual participation in the propaedeutic and/or therapeutic conduct of the studied cases, final approval of the final version of the manuscript.

Alberto Mota: The study concept and design, effective participation in the research guidance, intellectual participation in the propaedeutic and/or therapeutic conduct of the studied cases, and final approval of the final version of the manuscript.

Maria João Cruz: The study concept and design, data collection, or analysis and interpretation of data, statistical analysis, writing of the manuscript or critical review of important intellectual content, effective participation in the research guidance, intellectual participation in the propaedeutic and/or therapeutic conduct of the studied cases, critical review of the literature, final approval of the final version of the manuscript.

Conflicts of interest

None declared.

References

1. Liy-Wong C, Kim M, Kirkorian AY, Eichenfield LF, Diaz LZ, Horev A, et al. Hidradenitis suppurativa in the pediatric population: an international, multicenter, retrospective, cross-sectional study of 481 pediatric patients. JAMA Dermatol. 2021;157:385–91.
2. Górecka A, Barańska-Rybak W, Lewandowski M, Szymańska E, Świerczewska Z, Walecka I. Pediatric-onset hidradenitis suppu-

rativa: a case series of 42 patients. Postepy Dermatol Alergol. 2024;41:525–9.
3. Fougerousse AC, Reguiai Z, Roussel A, Bécherel PA. Hidradenitis suppurativa management using tumor necrosis factor inhibitors in patients younger than 18 years: a series of 12 cases. J Am Acad Dermatol. 2020;83:199–201.
4. Masson R, Ma E, Parvathala N, Shih T, Atluri S, Hogeling M, et al. Efficacy of medical treatments for pediatric hidradenitis suppurativa: a systematic review. Pediatr Dermatol. 2023;40:775–88.

Gilberto Pires da Rosa [a,b], Sofia Magina [a,c], Carmen Lisboa [a,d], Filomena Azevedo [a], Alberto Mota [a,b,e], Maria João Cruz [a,b,*]

[a] *Department of Dermatology and Venereology, São João Local Health Unit, Porto, Portugal*
[b] *Department of Medicine, Faculty of Medicine, University of Porto, Porto, Portugal*
[c] *Biomedicine Department, Faculty of Medicine, University of Porto, Porto, Portugal*
[d] *Microbiology, Department of Pathology, Faculty of Medicine, University of Porto, Porto, Portugal*
[e] *CINTESIS@RISE – Center for Health Technology and Services Research, Porto, Portugal*

[*] Corresponding author.
E-mail: mjmc@live.com.pt (M.J. Cruz).

Received 24 January 2025; accepted 12 February 2025
Available online 14 August 2025

SOCIEDADE BRASILEIRA DE DERMATOLOGIA

Anais Brasileiros de Dermatologia

www.anaisdedermatologia.org.br

LETTER - CLINICAL

Appearance of basal cell carcinoma on untreated capillary malformation☆

Dear Editor,

Capillary malformations are congenital abnormalities in the morphogenesis of capillary vessels in the skin, consisting of a network of dilated blood vessels in the superficial dermis beneath a normal epidermis. They are present in 0.1%–0.3% of infants and represent the most common congenital vascular malformation.[1] The development of basal cell carcinoma (BCC) within a capillary malformation is a rare finding, and its etiology remains unclear.[2]

We present the case of a 62-year-old female patient with a history of a left frontal nevus flammeus following the V1 trigeminal dermatome since birth, with no prior evaluation or treatment. She reported a seven-year history of an asymptomatic, progressively enlarging lesion in the left frontal region, accompanied by the development of nodules and tumors. On physical examination, an erythematous-violaceous plaque with superficial nodules, some hyperkeratotic and tending to coalesce, was observed (Fig. 1). The lesion had a soft consistency and followed the distribution of the V1 trigeminal branch. Dermoscopy revealed an erythematous base with ectatic red vessels, presenting as linear structures with a horizontal orientation and rounded, globular structures with a vertical orientation. Additionally, some nests and blue-gray globules were noted (Fig. 2). Doppler ultrasound identified a low-flow vascular malformation with poorly defined borders in the supraciliary and left frontal region, extending to the junction with the scalp. An incisional biopsy, guided by dermoscopic demarcation, revealed superficial hyperkeratosis, an infundibulum with cystic dilation, and irregular nests of basaloid cells infiltrating into the deep reticular dermis, consistent with pigmented nodular basal cell carcinoma (Fig. 3). A Limberg flap was selected to provide broader coverage without tissue tension and to facilitate closure of the secondary defect (Fig. 4).

Figure 1 Erythematous-violaceous plaque with superficial nodules, some hyperkeratotic, with a tendency to coalesce, soft consistency, following the distribution of the V1 trigeminal branch.

Previous therapy, particularly radiotherapy, has been proposed as a contributing factor to the development of BCCs within capillary malformations. Although this treatment approach is now obsolete for these lesions, its association with BCC has been reported in up to 75% of cases.[2,3] The first description of BCC arising in a capillary malformation was made by Scott in 1948,[4] and to date, approximately 27 cases have been reported,[5] of which only six occurred in untreated capillary malformations.[2,6] It has been suggested that the production of an oncogenic factor by the underlying static vessels may render the epidermis more susceptible to ultraviolet or ionizing radiation.[2]

In conclusion, we report a case of BCC arising within an untreated facial capillary malformation, an association that has been rarely documented and poses a diagnostic challenge. Dermoscopy plays a crucial role in highlighting vascular and pigmented features suggestive of basal cell

☆ Study conducted at the Clínica Alemana, Universidad del Desarrollo, Santiago, Chile.

https://doi.org/10.1016/j.abd.2025.501190

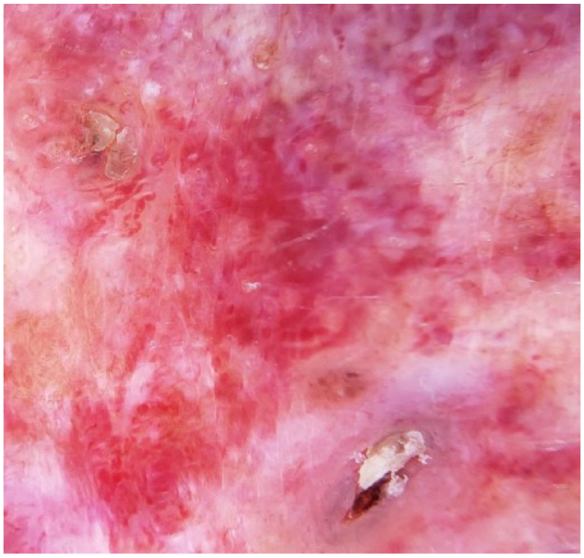

Figure 2 Dermoscopy image displays an erythematous base with ectatic red vessels, linear with a horizontal orientation and rounded, globular with a vertical orientation. Associated with some nests and blue-gray globules, rosettes, fibrosis, and areas resembling seborrheic keratosis.

carcinoma, particularly in this context. However, further studies are needed to determine the presence of local factors that may contribute to the development of these tumors within a capillary malformation.

Financial support

None declared.

Research data availability

Does not apply.

Editor

Sílvio Alencar Marques.

Author's contributions

Catalina Buchroithner: Approval of the final version of the manuscript; critical literature review; manuscript critical review; preparation and writing of the manuscript.

Nelson Lobos: Approval of the final version of the manuscript; critical literature review; manuscript critical review; preparation and writing of the manuscript.

Gabriel Neely: Critical literature review; manuscript critical review; preparation and writing of the manuscript.

Arturo Madrid: Critical literature review; manuscript critical review; preparation and writing of the manuscript.

Valentina Darlic: Critical literature review; manuscript critical review; preparation and writing of the manuscript.

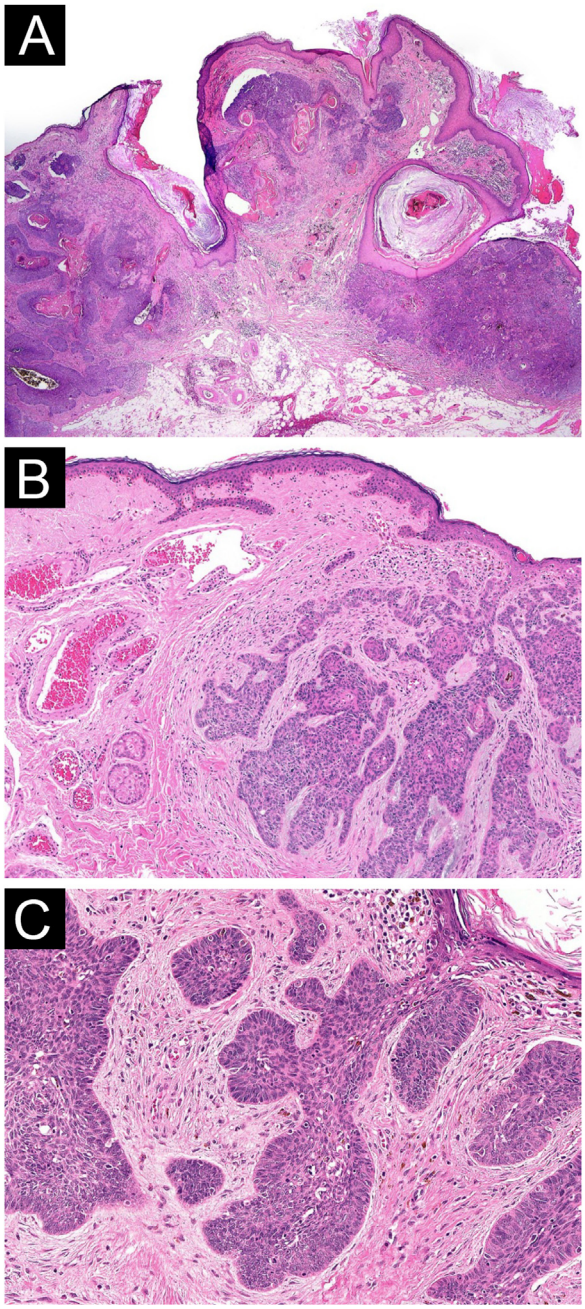

Figure 3 Histopathology (A) Hematoxylin & eosin, ×40: Low power shows tumor composed of nests of basaloid cells. Some retraction spaces are visible between tumor islands and stroma. (B) Hematoxylin & eosin, ×100: Tumor is made of basaloid cells arranged in cords and nests. The stroma is fibrous and exhibits mucinous change. At the left, abnormal dilated dermal vessels are seen. (C) Hematoxylin & eosin, ×200: High power shows tumor nests composed of basaloid cells with oval nuclei and scant cytoplasm, forming a peripheral palisading.

Alex Castro: Critical literature review; manuscript critical review; preparation and writing of the manuscript.

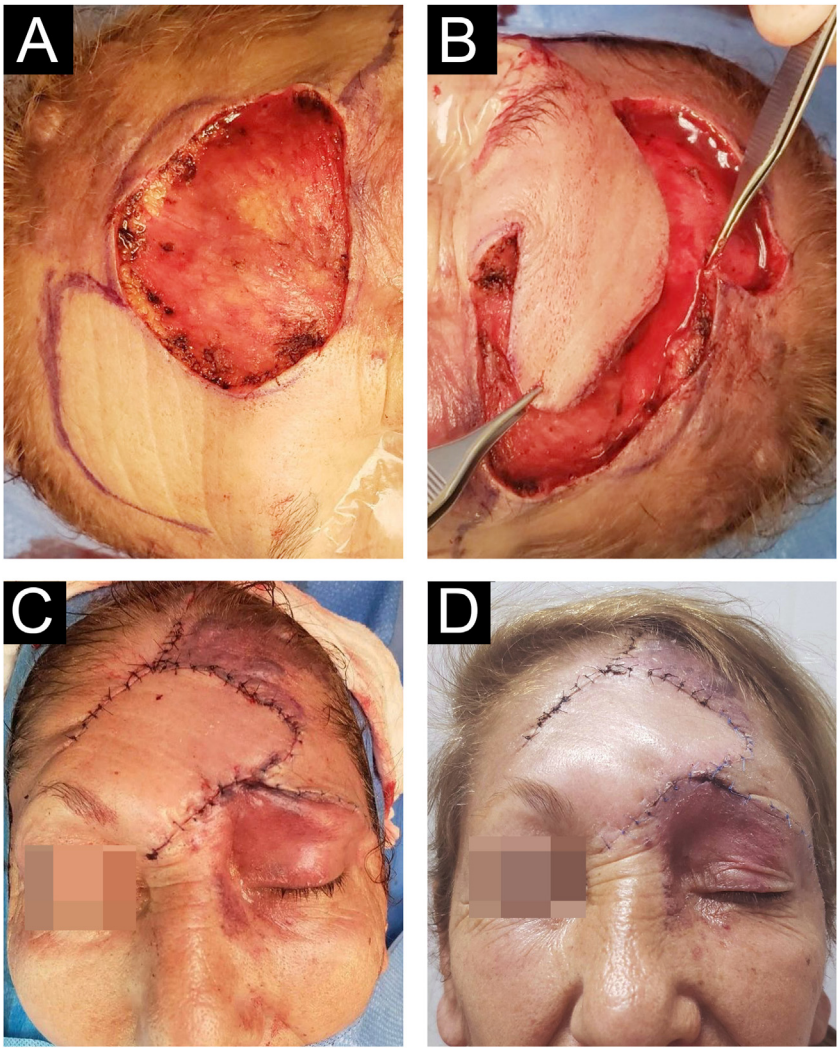

Figure 4 Limberg flap was chosen to achieve greater coverage without tissue tension and to facilitate the closure of the secondary defect. (A) Primary defect. (B) Closure planning. (C) Immediate postoperative period. (D) Postoperative day 21.

Conflicts of interest

None declared.

References

1. Faurshou A. Laser or light sources for treating port-wine stains (Review). Cochrane Database Syst Rev. 2011:CD007152.
2. Fujita M, Tanizaki H, Tanioka M, Kabashima K, Miyachi Y. Basal cell carcinoma arising within port-wine stains with no preceding radiotherapy. J Dermatol. 2015;42(10):1007–8, http://dx.doi.org/10.1111/1346-8138.12995.
3. Lapidoth M, Ad-El D, David M, Alcalay J, Azaria R. Basal cell carcinoma arising over facial port wine stain: a single centre experience. J Eur Acad Dermatol Venereol. 2006;20:1066–9.
4. Scott IM. Basal cell epithelioma on the site of an angioma. Br J Dermatol Syph. 1948;60:69–70.
5. Kaune KM, Haas E, Buhl T, Schön MP, Zutt M. Multiple basal cell carcinomas arising in radiotherapy-treated nevus flammeus: early detection facilitated by 595-nm pulsed dye laser. Eur J Dermatol. 2010;20:510.
6. Hackett CB, Langtry JAA. Basal cell carcinoma of the ala nasi arising in a port wine stain treated using mohs micrographic surgery and local flap reconstruction. Dermatol Surg. 2014;40:590–2.

Catalina Buchroithner [a], Nelson Lobos [a,b,*], Gabriel Neely [a,b], Arturo Madrid [c], Valentina Darlic [d], Alex Castro [d]

[a] *Dermatology Department, Clínica Alemana, Universidad del Desarrollo, Santiago, Chile*
[b] *Dermato-Oncology Unit, Head and Neck Surgery Department, Instituto Nacional del Cancer, Santiago, Chile*
[c] *Head and Neck Surgery Department, Clínica Alemana, Universidad del Desarrollo, Santiago, Chile*
[d] *Pathology Department, Clínica Alemana, Universidad del Desarrollo, Santiago, Chile*

* Corresponding author.
E-mail: nelsonlobosguede@gmail.com (N. Lobos).

Received 20 February 2025; accepted 19 April 2025
Available online 9 August 2025

SOCIEDADE BRASILEIRA DE DERMATOLOGIA

Anais Brasileiros de Dermatologia

www.anaisdedermatologia.org.br

LETTER - CLINICAL

Composite hemangioendothelioma: report of a rare neoplasm☆

Dear Editor,

Hemangioendothelioma is the term used to name a group of heterogeneous vascular neoplasms that show an intermediate behavior between hemangiomas, which are completely benign, and angiosarcomas, which are malignant.[1–4] It includes the epithelioid, fusiform, retiform, kaposiform, polymorphic lymph nodal and composite variants.[1] Most are low-grade vascular neoplasms, being locally aggressive, with a high tendency for local recurrence and low metastatic potential.[3] Composite hemangioendothelioma (CHE) differs from others by disclosing, in histopathology, the combination of different vascular proliferation patterns, both benign and malignant, in the same lesion.[1–4]

The present report describes a case of CHE, a rarely reported neoplasm.

The project was approved by the Research Ethics Committee, under number 59637316.6.0000.5515.

A 70-year-old female patient reported the appearance of a tumor in the left inframammary region one year after the excision of a clinically diagnosed hemangioma in the same location, which was growing. She reported that approximately two months before the lesion started to grow more rapidly, bleed, and become extremely painful. She had systemic arterial hypertension, had no other morbidities, and had no other significant personal or family history. Dermatological examination revealed the presence of an ulcerated tumor measuring 10 cm, with raised, violaceous edges, a friable and bleeding surface, and a necrotic background, located in the left inframammary region (Fig. 1). There were no palpable regional lymph nodes, and the rest of the physical examination was unremarkable. Routine laboratory tests were normal. Computed tomography scans of the chest and abdomen showed only an ulcerated lesion in the skin and subcutaneous tissue in the left inframammary region, with intense venous contrast uptake. The histopathological examination of the lesion biopsy was compatible with CHE (Fig. 2). The immunohistochemistry was positive for anti-CD31 and anti-CD34 antibodies, common endothelial markers, and anti-factor VIII and anti-Ki67 (10% positivity), which demonstrate the tumor intermediate malignant potential. The lesion was excised with wide safety margins but recurred two years later, and the patient underwent a new surgical excision. However, due to the involvement of the sternum, costal arches, and pericardium, palliative chemotherapy with paclitaxel was started, but the patient died within six months.

Fig. 1 Ulcerated, bleeding tumor with raised, violaceous edges, necrotic background covered by fibrin and purulent secretion, well-defined, located in the left inframammary region. Adjacent skin is normal.

In 2000, Nayler et al.[5] reported eight cases of a neoplasm with a variable vascular pattern, showing vascular combinations of benign and malignant neoplasms, naming it CHE,[5] which was included in the 2002 WHO classification of tumors of soft tissue and bone.[3]

CHE is an extremely rare neoplasm with borderline behavior that differs from other hemangioendotheliomas due to its typical histopathological characteristics.[1–4] Its incidence varies by age, with cases reported in children and the elderly,[2] with a mean age of 39 years, and a predilection for the female sex (2.7:1).[3] The lesions are clinically indistinguishable from other vascular neoplasms and may manifest as nodules, plaques, or ulcerations, most of which are located at the cutaneous level, mainly in the distal portion of the upper and lower extremities,[1–4] with reports

☆ Study conducted at the Universidade do Oeste Paulista, Presidente Prudente, SP, Brazil.

https://doi.org/10.1016/j.abd.2025.501166

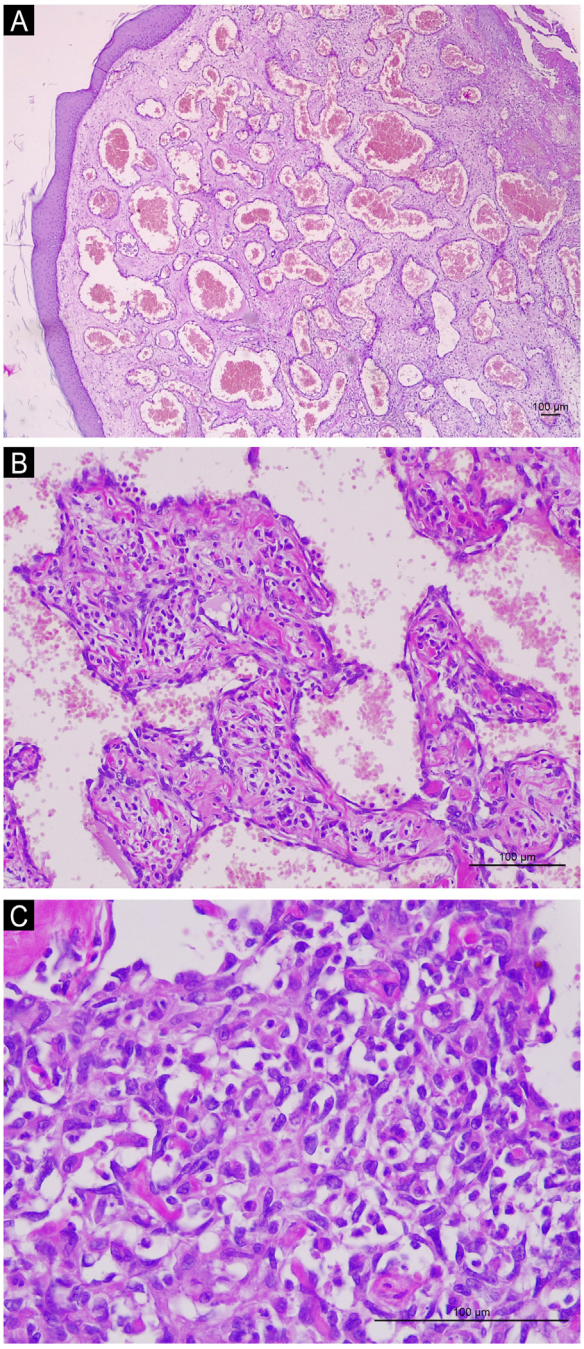

Fig. 2 (A) Dilated vascular channels with a cavernous appearance, resembling a common hemangioma in the superficial portion of the biopsy. Magnification of ×40. (B) Observe vessels lined by endothelial cells whose nuclei are often protruding (hobnail), resembling a retiform hemangioendothelioma. Magnification of ×200. (C) Small vascular spaces surrounded by cells with scant cytoplasm and round and fusiform, hyperchromatic and irregular nuclei, suggestive of kaposiform hemangioendothelioma. Magnification of ×400. In (A), (B) and (C): Hematoxylin & eosin, Scale bar: 100 µm.

of extracutaneous locations.[6–8] Cutaneous locations on the trunk, as in the case described here, are not common.

It is classified as a low-grade malignant neoplasm, rarely evolving with metastases, which occur mainly in the lymph nodes.[2]

Histopathological examination demonstrates an association of benign vascular patterns, such as hemangioma, and malignant ones, such as angiosarcoma, within the same lesion, and the proportion of each component varies.[1] The histopathological diagnosis requires the presence of at least two variants of hemangioendothelioma.[3] The predominant components, in most cases, are retiform hemangioendothelioma, epithelioid hemangioendothelioma and spindle cell hemangioma.[1,3] More rarely, areas of angiosarcoma are also present.

In the present case, the patient reported that the CHE appeared one year after the excision of a hemangioma diagnosed only clinically in the same location, but the histopathological examination was not performed, which leads to the question of whether the lesion was not already a CHE, since the emergence of CHE in a previous scar of another vascular malformation, as well as the malignant transformation of an hemangioma, are extremely rare events.[4]

It is not known what the best therapeutic approach is; there are reports of chemotherapy, interferon alpha, radiotherapy, and excision of the lesion with wide margins.[2]

The authors emphasize the difficulty in diagnosing CHE since the lesion is clinically indistinguishable from other malignant vascular neoplasms and is rare, in addition to requiring the participation of an experienced pathologist.

Research data availability

Does not apply.

Editor

Sílvio Alencar Marques.

Financial support

None declared.

Authors' contributions

Marilda A. M. Morgado de Abreu: Design and planning of the study; critical review of the literature; collection, analysis and interpretation of data; effective participation in research orientation; intellectual participation in the propaedeutic and/or therapeutic conduct of the studied cases; approval of the final version of the manuscript.

Carolina A. de A. Ferreira: Drafting and editing of the manuscript; collection, analysis and interpretation of data; intellectual participation in the propaedeutic and/or ther-

apeutic conduct of the studied cases; critical review of the literature.

Gisele A. Nai: Critical review of the literature; collection, analysis and interpretation of data; effective participation in research orientation; intellectual participation in the propaedeutic and/or therapeutic conduct of the studied cases; approval of the final version of the manuscript.

Conflicts of interest

None declared.

References

1. Biagioli M, Sbano P, Miracco C, Fimiani M. Composite cutaneous haemangioendothelioma: case report and review of the literature. Clin Exp Dermatol. 2005;30:385–7.
2. Mahmoudizad R, Samrao A, Bentow JJ, Peng SK, Bhatia N. Composite hemangioendothelioma: an unusual presentation of a rare vascular tumor. Am J Clin Pathol. 2014;141:732–6.
3. Stojsic Z, Brasanac D, Stojanovic M, Boricic M. Cutaneous composite hemangioendothelioma: case report and review of published reports. Ann Saudi Med. 2014;34:182–8.
4. Chu YC, Choi SJ, Park IS, Kim L, Han JY, Kim JM. Composite hemangioendothelioma—a case report. Korean J Pathol. 2006;40:142–7.
5. Nayler SJ, Rubin BP, Calonje E, Chan JK, Fletcher CD. Composite haemangioendothelioma: a complex, low-grade vascular lesion mimicking angiosarcoma. Am J Surg Pathol. 2000;24:352–61.
6. Cakir E, Demirag F, Gulhan F, Oz G, Tastepe I. Mediastinal composite hemangioendothelioma. A rare tumor at an unusual location. Tumori. 2009;95:98–100.
7. Zhang J, Wu B, Zhou GQ, Zhang RS, Wei X, Yu B, et al. Composite hemangioendothelioma arising from the kidney: case report with review of the literature. Int J Clin Exp Pathol. 2013;6:1935–41.
8. Schaeffer T, Glatz K, Eckstein FS, Matt P. Composite haemangioendothelioma in the heart: a case report. Eur Heart J Case Rep. 2023;7:ytad343.

Marilda Aparecida Milanez Morgado de Abreu *, Carolina Aparecida de Almeida Ferreira, Gisele Alborghetti Nai

Department of Dermatology, Universidade do Oeste Paulista, Presidente Prudente, SP, Brazil

* Corresponding author.
E-mail: marilda@morgadoeabreu.com.br
(M.A. Morgado de Abreu).

Received 22 August 2024; accepted 1 October 2024
Available online 9 August 2025

Anais Brasileiros de Dermatologia 2025;**100(5)**:501191

SOCIEDADE BRASILEIRA DE DERMATOLOGIA

Anais Brasileiros de Dermatologia

www.anaisdedermatologia.org.br

LETTER - CLINICAL

Derm dotting technique to detect micro-invasive component in lentigo maligna and subsequent margin control with a modified staged excision technique☆

Dear Editor,

Detecting microinvasion in lentigo maligna (LM) is crucial for accurate staging and management. Various techniques have been proposed to mark areas of interest for histological analysis, but their use in LM is limited. Reflectance confocal microscopy (RCM) may aid in this process, though identifying microinvasive atypical melanocytes remains challenging. We describe a practical approach using the derm-dotting (DD) method to assess microinvasion while simultaneously controlling peripheral margins during surgery.

A 72-year-old male presented with a 2.5 cm polychromic macule on the nasal dorsum, showing progressive growth and color changes over the past year. An incisional biopsy confirmed LM, and he was referred for a complete peripheral margin assessment. Dermoscopy revealed two well-defined hyperpigmented eccentric areas with angulated lines, rhomboid structures, asymmetric follicular pigmentation, and dark blotches, interrupted by a central light brown zone with a pseudonetwork pattern. After discussion in our melanoma committee, we opted for a modified staged excision technique (MSET) as a ''slow Mohs'' procedure to assess 100% of the peripheral margins, instead of using paraffin-embedded radial sections. Before the debulking of the central portion of the melanoma, we decided to perform an in vivo DD technique. We selectively marked (with red nail polish) the dermoscopic areas of irregular dark blotches and pigmented follicular openings to ensure they were processed and examined under a microscope (Fig. 1B). We debulked the tumor and sent it for paraffin-embedded sections for prognostic assessment. For margin evaluation, we excised four peripheral 5 mm skin quadrants beyond the dermoscopic perimeter, marking each with a suture at the distal border, oriented clockwise (Fig. 1C). Additional sutures were placed for reference in case further excision was needed. Histology revealed invasive LM with a 0.42 mm Breslow thickness, no ulceration, and two positive margins (1 and 2) (Fig. 1D). The involved margins were immediately enlarged, all proving tumor-free. The defect was repaired with a full-thickness graft.

Conventional skin biopsy processing may miss key areas between serial sections. Dermoscopic marking techniques enhance histopathological analysis by highlighting these regions.[1,2] For this purpose, punches, sutures, or nail polish have been suggested. The latter has the advantage that it is not altered during the processing of the specimen nor does it affect the histological evaluation. On the other hand, non-invasive techniques such as RCM or optical coherence tomography can be used for this purpose, however, their high cost and low availability make their use difficult.

Haspeslagh et al. using ex vivo DD in 8,584 biopsies, showed that the diagnosis of affected margins in non-melanoma skin cancer significantly increased with the use of this technique. So did the diagnosis of the degree of dysplasia in melanocytic nevi and the presence of ulceration in melanoma.[3]

The DD technique was originally described with in vivo dermoscopic marking, but there are also reports using the ex vivo modality.[1,4] For marking purposes in vivo DD has the advantage that certain structures, especially those of vascular origin, are not altered.

To our knowledge, to date, there have been no reports of the specific use of DD in LM to detect microinvasive foci. Peruilh-Bagolini et al. described irregular blotches and angulated lines as significant dermoscopic predictors of invasive LM.[5] Like that reported case, we usually use these findings to indicate the use of DD and find a positive correlation with the microinvasive foci.

DD can also allow us to make other diagnostic and therapeutic decisions since detecting microinvasive foci would allow us to rule out non-surgical treatments such as imiquimod. In addition, detecting invasive foci allows us to make decisions such as performing a sentinel lymph node.

In this case, we did not expand the peripheral or deep margins after identifying microinvasive foci, as these atypical cells were confined to the debulking center, with only in situ involvement at the periphery. The benefits of margin enlargement in microinvasive LM remain unproven, requir-

☆ Study conducted at the Clínica Alemana, Santiago de Chile.

https://doi.org/10.1016/j.abd.2025.501191

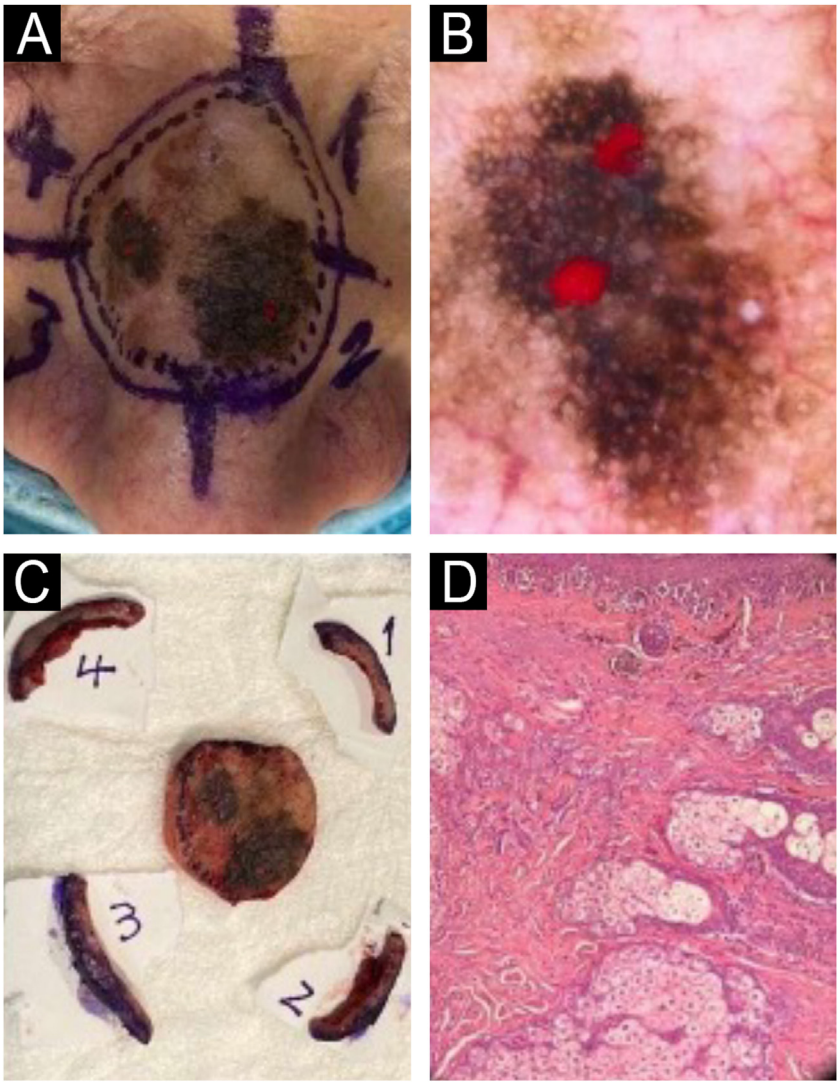

Fig. 1 (A) Pre-operative clinical image of the dorsum nasi LM. (B) In vivo derm dotting image showing suspicious areas for invasive components on dermoscopy marked with red nail polish. (C) Tumor debulking of the central LM and four perimeter quadrants of 5 mm guided by dermoscopy. (D) Histopathology: Extensive involvement of melanoma in situ and a microinvasive focus of 0.42 mm Breslow (Hematoxylin & eosin, 10×, paraffin-embedded permanent sections).

ing further longitudinal studies. However, given the thorough histological assessment provided by MSET, its use appears reasonable, particularly for extensive facial lesions.

We present a simple, cost-effective dermoscopy-guided technique to mark areas of interest for histological analysis, aiding in the detection of invasive components. Simultaneously, MSET allowed for complete peripheral margin assessment, optimizing surgical time.

Research data availability

Does not apply.

Editor

Sílvio Alencar Marques.

Financial support

None declared.

Authors' contributions

Nelson Lobos: Approval of the final version of the manuscript; critical literature review; manuscript critical review; preparation and writing of the manuscript.

Pablo Vargas: Critical literature review; manuscript critical review; preparation and writing of the manuscript.

Gabriela Coulon: Critical literature review; manuscript critical review; preparation and writing of the manuscript.

Chantal Caussade: Critical literature review; manuscript critical review; preparation and writing of the manuscript.

Valentina Darlic: Critical literature review; manuscript critical review; preparation and writing of the manuscript.

Magdalena Delgado: Critical literature review; manuscript critical review; preparation and writing of the manuscript.

Conflicts of interest

None declared.

References

1. Haspeslagh M, Degryse N, De Wispelaere I. Routine use of ex vivo dermoscopy with ''derm dotting'' in dermatopathology. Am J Dermatopathol. 2013;35:867–9.
2. Moreno Romero JA, Pérez Muñoz N, Campoy Sánchez A, Urbano Carrillo M, Fernández Figueras MT. Derm dotting: A new technique that improves diagnostic precision in the evaluation of skin lesions. Actas Dermosifiliogr (Engl Ed). 2019; 110:193–6.
3. Haspeslagh M, Hoorens I, Degryse N, De Wispelaere I, Degroote A, Van Belle S, et al. Pathologic evaluation of skin tumors with ex vivo dermoscopy with derm dotting. JAMA Dermatol. 2017;153:154–61.
4. Lanssens S, Vossaert K, De Schepper S. In vivo derm dotting: An easy and inexpensive way for clinicopathological correlation. Dermatol Pract Concept. 2019;9:71–2.
5. Peruilh-Bagolini L, Apalla Z, González-Cuevas R, Lallas K, Papageorgiou C, Bobos M, et al. Dermoscopic predictors to discriminate between in situ and early invasive lentigo maligna melanoma: A retrospective observational study. J Am Acad Dermatol. 2020;83:269–71.

Nelson Lobos-Guede [a,b,c,*], Pablo Vargas-Mora [a,b], Gabriela Coulon [c], Chantal Caussade [d], Valentina Darlic [e], Magdalena Delgado [f]

[a] *Head and Neck Surgery Department, Dermato-oncology Unit, Instituto Nacional del Cancer, Santiago, Chile*
[b] *Dermatology Department, Facultad de Medicina, Universidad de Chile, Santiago, Chile*
[c] *Dermatology Department, Clínica Alemana, Universidad del Desarrollo, Santiago, Chile*
[d] *Faculty of Medicine, Universidad de los Andes, Santiago Chile*
[e] *Faculty of Medicine, Universidad del Desarrollo, Santiago Chile*
[f] *Pathology Department, Clínica Alemana, Universidad del Desarrollo, Santiago, Chile*

[*] Corresponding author.
E-mail: nelsonlobosguede@gmail.com (N. Lobos-Guede).

Received 27 February 2025; accepted 31 March 2025
Available online 9 August 2025

SOCIEDADE BRASILEIRA DE DERMATOLOGIA

Anais Brasileiros de Dermatologia

www.anaisdedermatologia.org.br

LETTER - CLINICAL

Kaposi's sarcoma overlying Mpox scars – Case report☆

Dear Editor,

Kaposi's Sarcoma (KS) is an angiomatous tumor caused by infection with Human HerpesVirus-8 (HHV-8), often seen in immunocompromised patients, particularly those with HIV/AIDS.[1] Similarly associated with HIV, there is Mpox, a viral zoonosis with a smallpox resemblance but milder symptoms. It gained global attention during the post-COVID-19 return to normalcy and was declared a Public Health Emergency of International Concern by the World Health Organization in August 2024.[2] Mpox typically manifests as a flu-like prodrome followed by a smallpox-like rash, primarily after close interpersonal contact.[3] While KS and Mpox have distinct etiologies and clinical presentations, they share a connection through their unique manifestations in individuals infected with HIV. Currently, there are no published reports describing coexistence, overlap, or interaction between these conditions. We aim to present and discuss a case of KS arising over previous Mpox lesions.

A 22-year-old male patient presented with fever, asthenia, headache, cough, and odynophagia, followed by over 300 umbilicated pustules and crusts on the genital, perianal, and limb regions (Fig. 1A). Mpox was confirmed via PCR from lesion surfaces, and the patient was concurrently diagnosed with HIV. He required hospitalization and treatment with Tecovirimat 600 mg every 12 hours for 14 days. During hospitalization, erythematous-violaceous plaques were observed on the right upper limb, which the patient reported had existed for more than a year (Fig. 1B). Histopathology confirmed the suspicion of KS, configuring AIDS. Around 30 days later, as Mpox lesions progressed into the crusting phase, violaceous plaques appeared on the left thigh over previously healed pustules, progressively enlarging and developing an angiomatous morphology (Fig. 2). A skin biopsy was performed (Fig. 3), with histopathology showing irregular vascular structures with slit-like spaces and proliferation of endothelial cells, along with spindle-shaped cells with nuclei exhibiting both elongated and vesicular patterns. Immunohistochemical analysis demonstrated HHV-8 positivity, along with CD34 and ERG, confirming the diagnosis of Kaposi's Sarcoma. The patient began chemotherapy with doxorubicin, achieving slight reduction and improvement in violaceous coloration after one year, though residual large anetodermic nodules persisted (Fig. 4). Imaging revealed extension into the quadriceps muscles and iliac/femoral vascular bundles.

There is a well-known inverse relationship between CD4 count and the risk of KS development.[1] Immunocompromised individuals, like those with HIV/AIDS, are also at high risk for severe Mpox infection and its sequelae, as seen here with over 300 lesions, qualifying the patient for Tecovirimat treatment.[3] The development of atypical lesions over the topography of previous Mpox highlights the possible occurrence of phenomena more commonly described in other dermatological conditions. For instance, the Koebner isomorphic response refers to the development of lesions from a pre-existing condition at sites of skin injury, while the Wolf isotopic response describes the occurrence of a new and unrelated disease at the site of a previously resolved disease.[4,5] A review of over 500 KS patients identified only three cases of the Wolf isotopic phenomenon, all occurring after blistering diseases. None were described after Mpox or other infectious diseases.[6] Additionally, there are no reports of a Koebner isomorphic response involving Mpox.

In the reported case, KS presented precisely in the configuration of the Mpox lesions, suggesting an isotopic response. However, the patient had pre-existing KS on his arm which appeared before Mpox, complicating classification. Although it is not possible to definitively classify whether the condition represents an isotopic or isomorphic phenomenon, its occurrence can be explained by the old concept of *locus minoris resistentiae*, which describes the susceptibility of a vulnerable or immunocompromised area of the skin to develop lesions.[5] The Wolf isotopic phenomenon itself has been questioned as a distinct entity by authors such as Happle and Kluger,[5] who propose that a site previously affected by a dermatosis remains inherently vulnerable. This perspective suggests that all such cases

☆ Study conducted at the Department of Dermatology, Hospital Universitário Onofre Lopes, Universidade Federal do Rio Grande do Norte, Natal, RN, Brazil.

https://doi.org/10.1016/j.abd.2025.501186

Figure 1 Admission findings of a 22-year-old patient hospitalized for Mpox with a recent HIV diagnosis. Mpox lesions on the patient's thigh (A) and Kaposi sarcoma lesions present prior to Mpox (B).

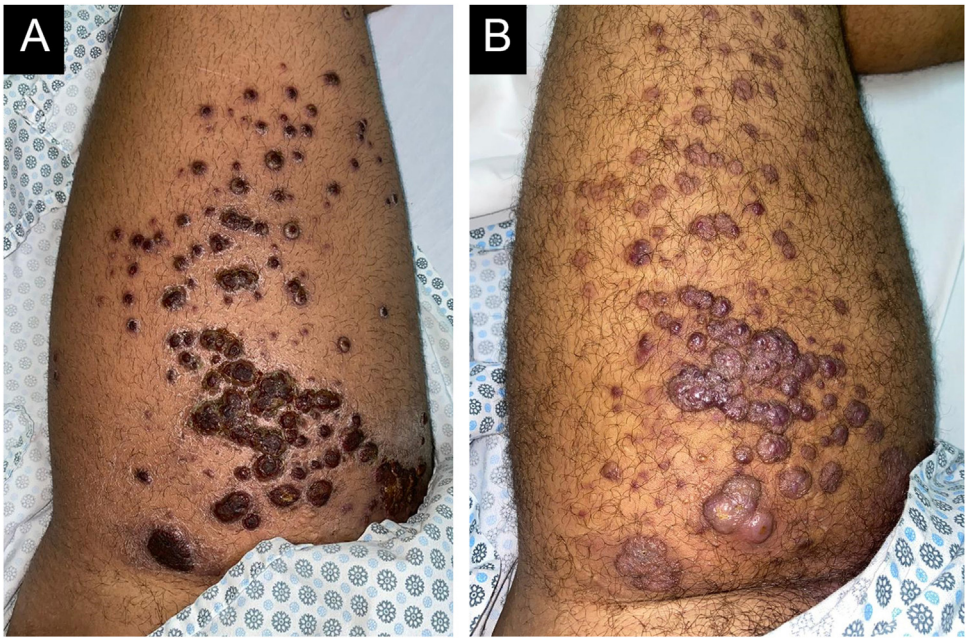

Figure 2 Evolution of lesions from the crusting phase of Mpox (A) into an angiomatous pattern (B), configuring Kaposi sarcoma overlying Mpox scars.

could potentially represent examples of the Koebner phenomenon.

This report introduces a novel presentation, bridging and revisiting concepts typically applied to other dermatoses. It highlights the need to expand diagnostic hypotheses, particularly in light of the increasing prevalence of Mpox cases, and emphasizes early recognition and treatment of this condition.

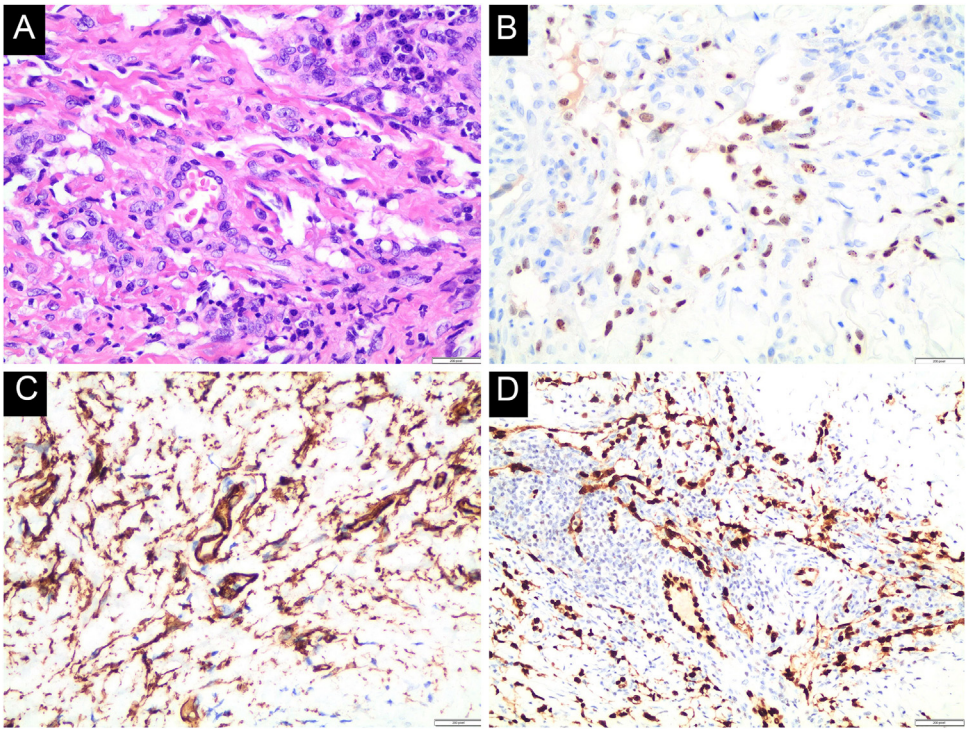

Figure 3 Histopathological findings. A. Hematoxylin & eosin, ×100, showing irregular slit-like vascular spaces lined by endothelial cells and spindle cell proliferation. B. (Immunohistochemical, ×100), positive for Human Herpesvirus type-8 (HHV-8), C. CD34, and D. ETS-Related Gene (ERG).

Figure 4 Kaposi sarcoma lesions before (A) and after (B) chemotherapy.

Financial support

None declared.

Authors' contributions

José Paulo Ribeiro Júnior: Design and planning of the study; collection, analysis and interpretation of data; critical review of the literature; drafting and editing of the manuscript or critical review of important intellectual content.

Thaís Barros Felippe Jabour: Collection, analysis and interpretation of data; Critical review of the literature; drafting and editing of the manuscript or critical review of important intellectual content.

Liana Franco de Sousa Barros: Collection, analysis and interpretation of data; critical review of the literature; drafting and editing of the manuscript or critical review of important intellectual content.

Juliana Carlos Gonçalves Rego: Design and planning of the study; critical review of the content; approval of the final version of the manuscript.

Research data availability

Does not apply.

Editor

Hiram Larangeira de Almeida Jr.

Conflicts of interest

None declared.

References

1. Etemad SA, Dewan AK. Kaposi sarcoma updates. Dermatol Clin. 2019;37:505–17.
2. Gostin LO, Jha AK, Finch A. The Mpox global health emergency - a time for solidarity and equity. N Engl J Med. 2024;391:1265–7.
3. Elsayed S, Bondy L, Hanage WP. Monkeypox virus infections in humans. Clin Microbiol Rev. 2022;35:e0009222.
4. Wolf R, Wolf D, Ruocco V, Ruocco E. Wolf's isotopic response: the first attempt to introduce the concept of vulnerable areas in dermatology. Clin Dermatol. 2014;32:557–60.
5. Happle R, Kluger N. Koebner's sheep in Wolf's clothing: does the isotopic response exist as a distinct phenomenon? J Eur Acad Dermatol Venereol. 2018;32:542–3.
6. Brambilla L, Aromolo IF, Buffon S, Benaglia C, Tourlaki A. Koebner phenomenon in kaposi's sarcoma: a large single-center case series and review of current knowledge. J Cutan Med Surg. 2023;27:102–7.

José Paulo Ribeiro Júnior [a,*],
Thaís Barros Felippe Jabour [b],
Liana Franco de Sousa Barros [b],
Juliana Carlos Gonçalves Rego [a]

[a] *Department of Dermatology, Hospital Universitário Onofre Lopes, Universidade Federal do Rio Grande do Norte, Natal, RN, Brazil*
[b] *Department of Dermatology, Universidade de Santo Amaro, São Paulo, SP, Brazil*

[*] Corresponding author.
E-mail: josepaulojr@outlook.com (J.P. Ribeiro Júnior).

Received 7 January 2025; accepted 13 February 2025
Available online 15 August 2025

SOCIEDADE BRASILEIRA DE DERMATOLOGIA

Anais Brasileiros de Dermatologia

www.anaisdedermatologia.org.br

LETTER - CLINICAL

Multinucleated cell angiohistiocytoma: independent entity or variant of dermatofibroma? Rosettes and shiny white lines as new dermoscopic findings☆

Dear Editor,

Multinucleated Cell Angiohistiocytoma (MCA) is an unusual benign vascular and fibro-histiocytic proliferation, predominantly affecting women aged 40 to 70 years.[1] Clinically, it presents as asymptomatic violaceous or brownish papules, either solitary or clustered, primarily located on the dorsal hands and extremities, although generalized forms have also been described.[1,2] These lesions may resemble annular granuloma, sarcoidosis, Kaposi sarcoma, lichen planus, or dermatofibroma.[1]

Traditionally, MCA has been described as a vascular cutaneous tumor. Although its pathogenesis remains unclear, recent observations suggest it may instead represent a fibrohistiocytic process or a chronic inflammatory condition with fibrohistiocytic and vascular hyperplasia.[2,3] Controversial hypotheses propose MCA as a particular variant of dermatofibroma, while others argue that it is a distinct entity with unique clinical, histological, and immunohistochemical characteristics.[2,4] The influence of female hormones on its pathogenesis has also been suggested, supported by the identification of estrogen receptor alpha in interstitial and multinucleated cells, which may explain its higher prevalence in women.[5]

Histologically, MCA is characterized by a proliferation of capillaries and venules in the superficial and mid-dermis, accompanied by prominent endothelial cells. Thickened collagen fibers parallel to the epidermis and frequent acanthosis of the epidermis are also observed. The most striking finding, although not pathognomonic, is the presence of multinucleated giant cells, typically positive for vimentin and factor XIIIa, with variable positivity for CD68. These cells are also found in other fibrohistiocytic proliferations, including dermatofibromas, angiofibromas, and nasal fibrous papules, with secondary vascular proliferation. This supports the hypothesis of MCA being a fibro-histiocytic process.[1]

Few studies have addressed the dermoscopy of MCA. Valerón-Almazán et al. were the first to describe its dermoscopic features, identifying three main structural patterns: diffuse reddish areas (corresponding to dilated vessels), whitish spots (associated with collagen thickening), and fine reticulated peripheral areas (likely representing melanin in epidermal ridges).[6] Despite the increasing number of reported cases, we found no additional dermoscopic descriptions of MCA in the literature.

We present four histologically confirmed cases of MCA with dermoscopic descriptions, summarized in Table 1. Three patients were female, and the age range was 60 to 65 years. Histological examination revealed characteristic features of MCA, including multinucleated giant cells, thickened collagen fibers parallel to the epidermis, and proliferation of thickened capillaries and small venules in the superficial and mid-dermis (Fig. 1). Immunohistochemistry was not performed in our cases, as the histological images and the clinicopathological correlation were consistent with the diagnosis of multinucleated cell angiohistiocytoma. All cases presented clinically similar lesions: small flat violaceous or brownish papules located on the dorsal hands (Fig. 2). The dermoscopic structures observed included rosettes, shiny white lines, pink, whitish, and homogeneous brown areas, homogeneous brown periphery, vascular dots, and whitish reticulated patterns (Fig. 3). All these structures, except for rosettes and shiny white lines, were previously described by Zeballos et al. for dermatofibromas.[7] Under polarized light dermoscopy, three cases showed rosettes and three cases exhibited shiny white lines (two cases had both structures), findings not previously described in MCA.

Rosettes are a type of shiny white structure visible only under polarized light dermoscopy, characterized by four bright white dots arranged like a four-leaf clover.[8,9] Unlike shiny lines and areas, likely caused by fibrotic dermal changes, the exact histopathological correlation of rosettes remains unknown. Smaller rosettes (0.1–0.2 mm) are believed to result primarily from polarizing keratin material at the infundibular level in

☆ Study conducted at the Department of Dermatology, Complejo Hospitalario Universitario A Coruña, A Coruña, Spain.

https://doi.org/10.1016/j.abd.2025.501183

Table 1 Summary of clinical and dermoscopic characteristics.

	Case A (Figs. 2A, 3A)	Case B (Figs. 2B, 3B)	Case C (Figs. 2C, 3C)	Case D (Figs. 2D, 3D)	
Sex		Female	Female	Female	Male
Age (years)		65	65	60	61
Location		Dorsal left hand	Dorsal left hand	Dorsum of both hands	Dorsal right hand
Evolution (years)		3	3	5	7
Dermoscopic structures (Fig. 3)	Rosettes (→)	+	+	+	–
	Shiny white lines (=)	+	+	–	+
	Whitish reticulated pattern (×)	+	+	–	–
	Vascular dots (>)	+	+	–	+
	Pink diffuse areas	+	+	+	+
	Whitish diffuse areas	+	+	+	–
	Brown diffuse areas	+	+	+	–
	Homogeneous brown periphery (*)	+	+	+	–

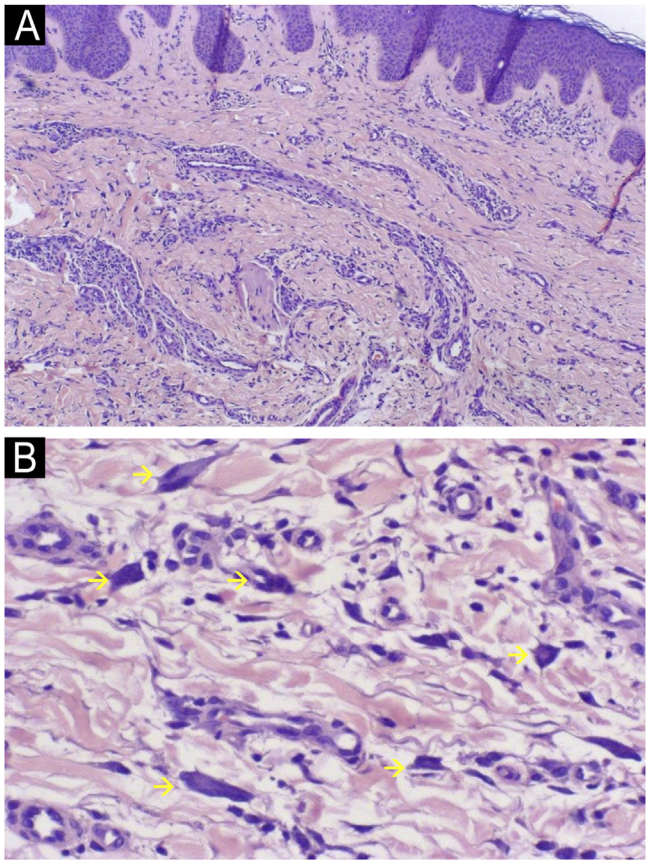

Fig. 1 Histological images.
(A) Low magnification view showing proliferation of thickened capillaries and small venules within a collagenous fibrotic stroma in the superficial and mid dermis (Hematoxylin & eosin, ×100). (B) Higher magnification picture showing the multinucleate cells (yellow arrows) (Hematoxylin & eosin, ×400).

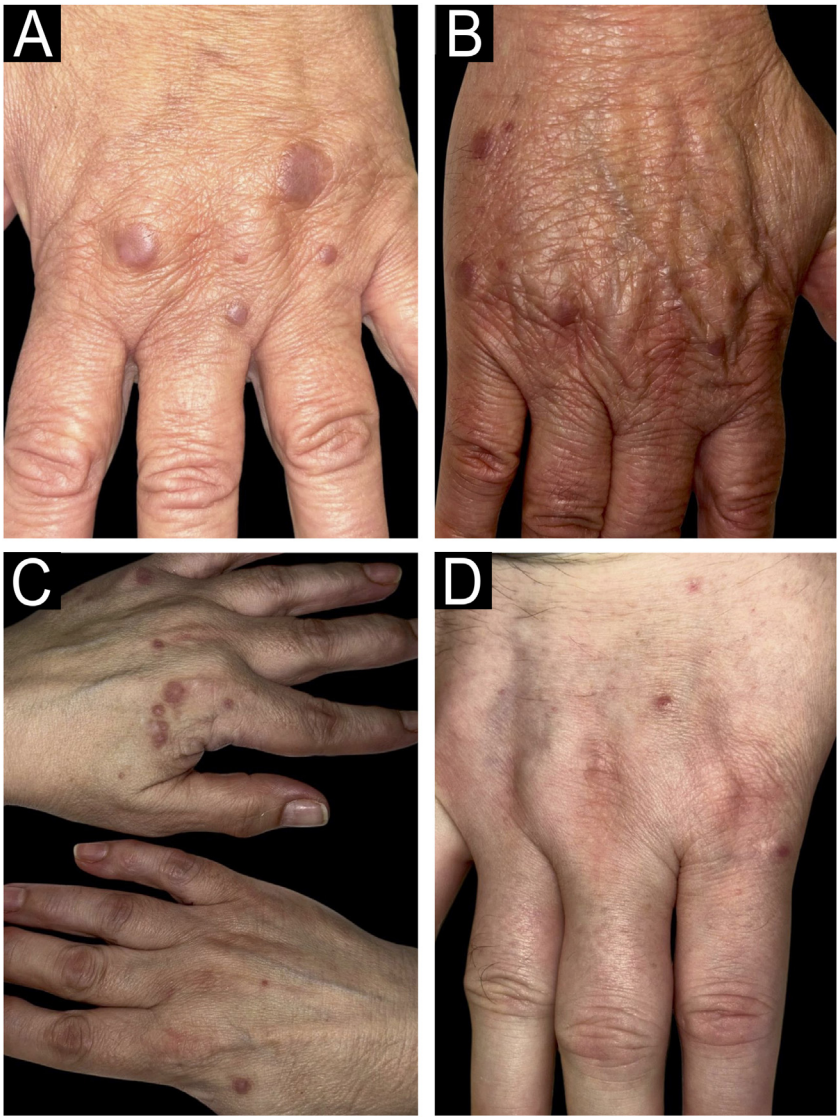

Fig. 2 Clinical images.
Small flat violaceous or brownish papules clustered on the dorsal aspect of the hands.

appendageal openings, while larger rosettes (0.3–0.5 mm) may be due to concentric perifollicular fibrosis. Historically, rosettes were considered common in actinic keratoses and squamous cell carcinoma. However, they have been observed in multiple non-keratinocytes and inflammatory lesions, including dermatofibromas, though very infrequently.[8,9]

Shiny white lines can appear orthogonal, parallel, centrifugal, or more disorganized and are primarily caused by the polarization of thickened hyaline fibrous bundles. They have been frequently described in dermatofibromas and scars, as well as in other lesions such as melanoma, Spitz nevus, basal cell carcinoma, and porokeratosis.[10]

We present new dermoscopic findings for MCA, highlighting the importance of this tool in characterizing the entity. Although rosettes and other dermoscopic structures are not specific to any condition, their presence can assist in the differential diagnosis of other conditions that clinically mimic MCA, such as Kaposi sarcoma, lichen planus, sarcoidosis, annular granuloma, or viral warts.[6] We observed significant dermoscopic similarities between MCA and dermatofibroma, supporting the hypothesis that MCA may indeed represent a histiocytic-origin entity.

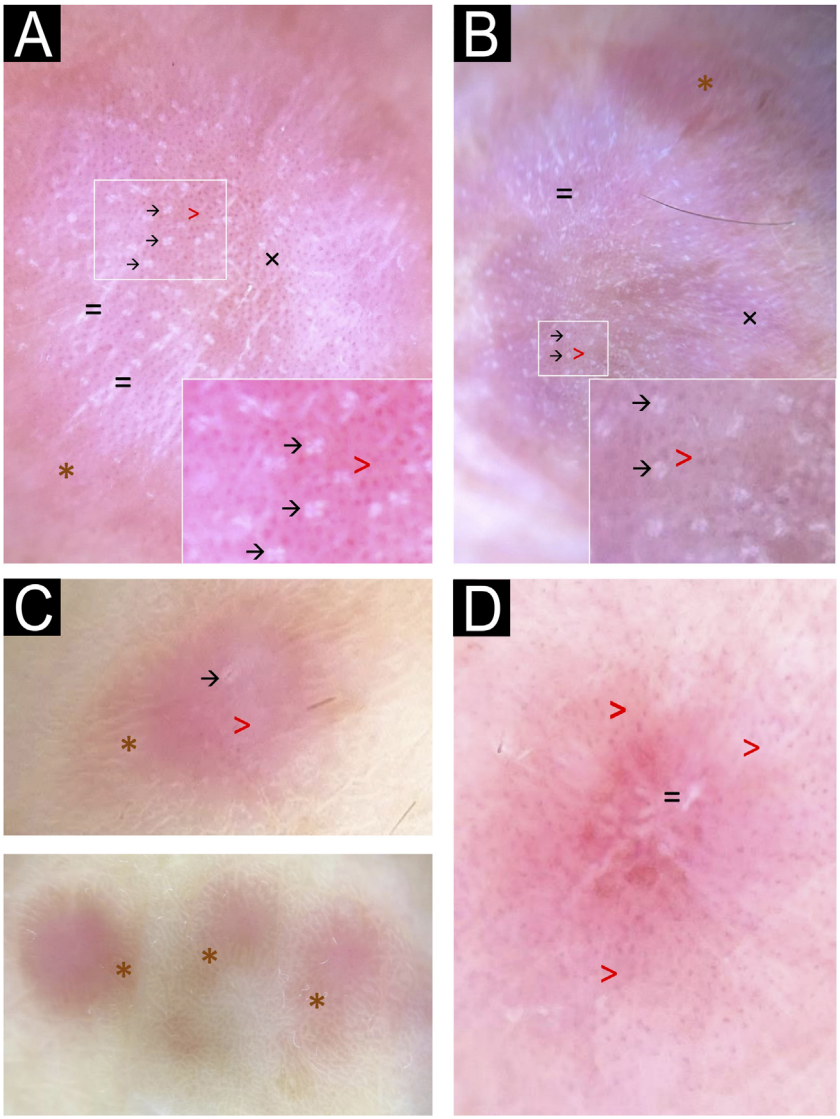

Fig. 3 Dermoscopic images.
Observed structures include homogeneous brown periphery (*), vascular dots (>), rosettes (→), shiny white lines (=), and whitish reticulated pattern (×). Pink, brown, and/or whitish diffuse areas were observed in all cases, with some lesions showing a homogeneous brown periphery (*). Regular vascular dots (>) were seen in all cases. Panels A and B highlighted multiple rosettes with a consistent distribution and orientation, whereas panel C revealed a single rosette at the lesion's center (→). Panels A and B also showed multiple shiny white lines diffusely distributed, with some localized at the lesion's center in panel B (=). Whitish reticulated areas (×) were also observed in panels A and B.

Research data availability

Does not apply.

Editor

Hiram Larangeira de Almeida Jr.

Authors' contributions

Sara Becerril Andrés: Conceptualized the study; conducted the literature review, collected and analyzed the clinical data, and wrote the original draft of the manuscript.

Eduardo de la Rosa Fernández: Assisted in the interpretation of findings, and reviewed the final version of the manuscript for approval.

Jesús del Pozo Losada: Contributed to the clinical management of the patient, provided expert input on the discussion section, and reviewed the final version of the manuscript for approval.

Financial support

None declared.

Conflicts of interest

None declared.

References

1. Grgurich E, Quinn K, Oram C, McClain R, Lountzis N. Multinucleate cell angiohistiocytoma: case report and literature review. J Cutan Pathol. 2019;46:59–61.
2. Jia QN, Qiao J, Qu T. Generalized multinucleate cell angiohistiocytoma with possible origin from fibroblasts: a clinicopathological study of 15 cases. J Dermatol. 2021;48:114–9.
3. Frew JW. Multinucleate cell angiohistiocytoma: clinicopathological correlation of 142 cases with insights into etiology and pathogenesis. Am J Dermatopathol. 2015;37:222–8.
4. Roy SF, Dong D, Myung P, McNiff JM. Multinucleate cell angiohistiocytoma: a clinicopathologic study of 62 cases and proposed diagnostic criteria. J Cutan Pathol. 2019;46:563–9.
5. Cesinaro AM, Roncati L, Maiorana A. Estrogen receptor alpha overexpression in multinucleate cell angiohistiocytoma: new insights into the pathogenesis of a reactive process. Am J Dermatopathol. 2010;32:655–9.
6. Valerón-Almazán P, Dehesa L, Santana N, Vilar J, Carretero G. Hallazgos dermatoscópicos del angiohistiocitoma de células multinucleadas: ¿una variante de dermatofibroma? [Dermoscopic features of multinucleate cell angiohistiocytoma: a variant of dermatofibroma?]. Actas Dermosifiliogr. 2011;102:69–71.
7. Zaballos P, Puig S, Llambrich A, Malvehy J. Dermoscopy of dermatofibromas: a prospective morphological study of 412 cases. Arch Dermatol. 2008;144:75–83.
8. Alorainy M, Buchanan K, Nussinow T, Rabinowitz JB, Cyr P, Seiverling EV. A systematic review of diagnoses with rosettes under dermoscopy. Dermatol Pract Concept. 2024;14:e2024125.
9. Haspeslagh M, Noë M, De Wispelaere I, Degryse N, Vossaert K, Lanssens S, et al. Rosettes and other white shiny structures in polarized dermoscopy: histological correlate and optical explanation. J Eur Acad Dermatol Venereol. 2016;30:311–3.
10. Balagula Y, Braun RP, Rabinovitz HS, Dusza SW, Scope A, Liebman TN, et al. The significance of crystalline/chrysalis structures in the diagnosis of melanocytic and nonmelanocytic lesions. J Am Acad Dermatol. 2012;67:194.e1–1948.

Sara Becerril-Andrés [a,*],
Eduardo de la Rosa-Fernández [b],
Jesús del Pozo-Losada [c]

[a] *Dermatology Department, Hospital Universitario de La Plana, Villarreal, Castellón, Spain*
[b] *Dermatology Department, Hospital Universitario Nuestra Señora de Candelaria, Santa Cruz de Tenerife, Spain*
[c] *Dermatology Department, Complejo Hospitalario Universitario A Coruña, A Coruña, Spain*

[*] Corresponding author.
E-mail: becerril_sar@gva.es, sarabecerrilandres@gmail.com (S. Becerril-Andrés).

Received 24 November 2024; accepted 27 January 2025
Available online 15 August 2025

Anais Brasileiros de Dermatologia 2025;**100(5)**:501179

SOCIEDADE BRASILEIRA DE DERMATOLOGIA

Anais Brasileiros de Dermatologia

www.anaisdedermatologia.org.br

LETTER - CLINICAL

Necrotizing fasciitis caused by *Stenotrophomonas maltophilia* on the neck of a previously healthy child☆

Dear Editor,

Necrotizing fasciitis (NF) is a rare and potentially life-threatening soft tissue infection that spreads along the fascial planes, resulting in necrosis of the fascia and subcutaneous tissue.[1] In adults, involvement of the head and neck structures is uncommon, with the lower extremities and trunk being the most prevalent locations. However, in children, the prevalence of lesions occurring in the head and neck is increased, reported to be 15% to 20%.[2] We describe a case of a child who developed an extensive necrotic ulcer on the neck due to NF caused by *Stenotrophomonas maltophilia*.

A previously healthy two-year-old girl was admitted to the intensive care unit with fever, cough, and dyspnea for 15 days. She was diagnosed with acute respiratory failure, leading to orotracheal intubation. Five days later, she presented with swelling in the bilateral submandibular, submental, retroauricular, and occipital areas. Empirical broad-spectrum antibiotics (vancomycin + meropenem) were prescribed. Despite the antibiotic therapy, the lesions progressed, and the patient had a septic shock, prompting the patient's transfer to a high-complexity hospital for further diagnostic evaluation. On her initial dermatological examination, she presented an extensive necrotic ulcer on the neck (Figs. 1A and B). A computed tomography scan (CT) revealed diffuse thickening and densification in the soft tissues of the neck (Fig. 1C). A punch biopsy and histopathological examination revealed coagulative necrosis in the epidermis, dermis, and hypodermis. In the fascia, there was a dense neutrophilic infiltrate with areas of necrosis (Fig. 2). Blood, tracheal, and skin cultures were obtained, all of which were positive for *Stenotrophomonas maltophilia* sensitive to levofloxacin and sulfamethoxazole/trimethoprim. The clinicopathological findings led to the diagnosis of necrotizing fasciitis.

Based on the antibiogram results, adjustments to the antibiotic regimen were made with the incorporation of levofloxacin, and debridement was performed. Following clinical improvement, grafting was realized. The patient progressed without complications, eventually being discharged from the hospital without any lasting sequelae (Fig. 3).

The initial clinical presentation of NF is nonspecific, and the disease can be misdiagnosed as cellulitis, erysipelas, or abscess formation.[1,2] NF often initiates as a red, hot, and painful wound. As the disease advances, intense local pain transitions to numbness or analgesia.[1] Progression of the pathological process involves necrosis of the subcutaneous and fascia, leading to arterial thrombosis, wet gangrene, and ultimately ischemic necrosis of the skin.[1,3] Inflammatory factors lead to fever, tachycardia, and eventually, septic shock.[1,2]

In the pediatric population, NF exhibits distinctive features compared to adults. Although necrotizing fasciitis is often fatal in adults, its fatality rate seems to be lower in children.[4] Unlike adult patients, where it is common in immunosuppressed and diabetic patients, children commonly affected are those previously healthy ones.[5] Initiating features include minor and major trauma, surgical wounds, and varicella lesions.[2] Also, unlike in adults, NF is usually a monomicrobial infection in children, most commonly owing to *Streptococcus pyogenes*, and is rarely polymicrobial.[4]

Stenotrophomonas maltophilia is a gram-negative aerobic bacillus that causes multi-drug-resistant opportunistic infections in hospitalized patients.[6] These infections usually have high morbidity and mortality rates. The organism can form biofilms on various surfaces. Although the respiratory system is most commonly affected, *S. maltophilia* has also been reported to cause skin, soft tissue, and biliary tract infections, endophthalmitis, and meningitis.[6] Risk factors include broad-spectrum antimicrobial therapy, prolonged stay in the intensive care unit, prolonged mechanical ventilation, immunosuppression, and the use of intravascular devices.[6]

The lack of distinctive lesions in the early stages of necrotizing fasciitis presents a significant diagnostic challenge, resulting in treatment delays. In our case, the delayed diagnosis led to septic shock and extensive tissue necrosis,

☆ Study conducted at the Faculdade de Medicina da Universidade de São Paulo, São Paulo, SP, Brazil.

https://doi.org/10.1016/j.abd.2025.501179

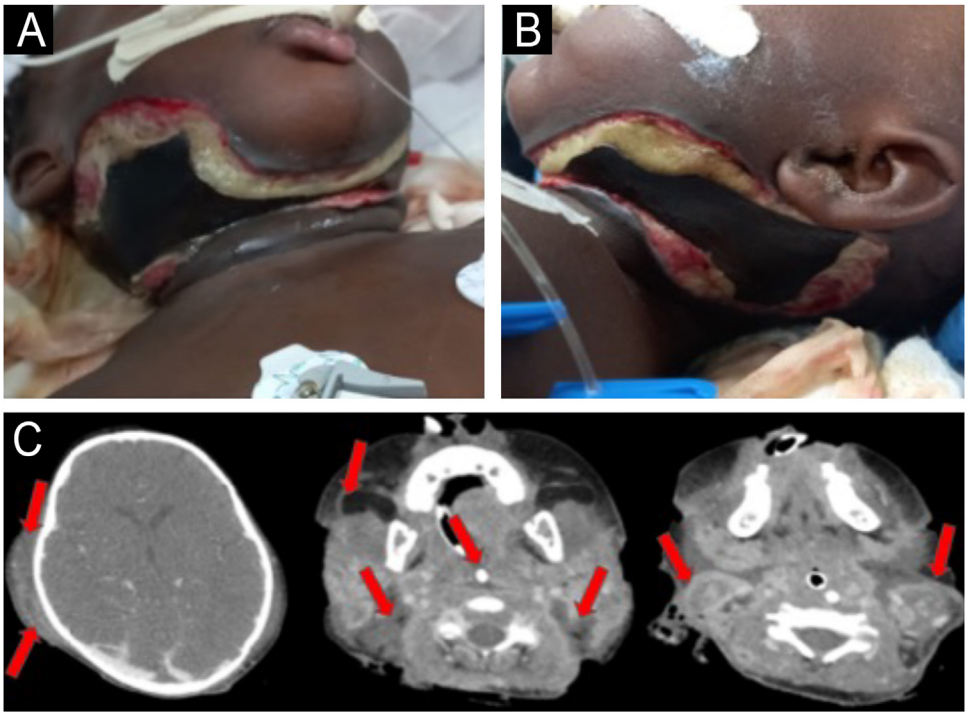

Figure 1 Extensive necrotic ulcer on the neck (A) right and anterior view (B) left view (C) CT scan showing thickening and densification of the myoadipose cervical planes and fascial enhancement (arrows).

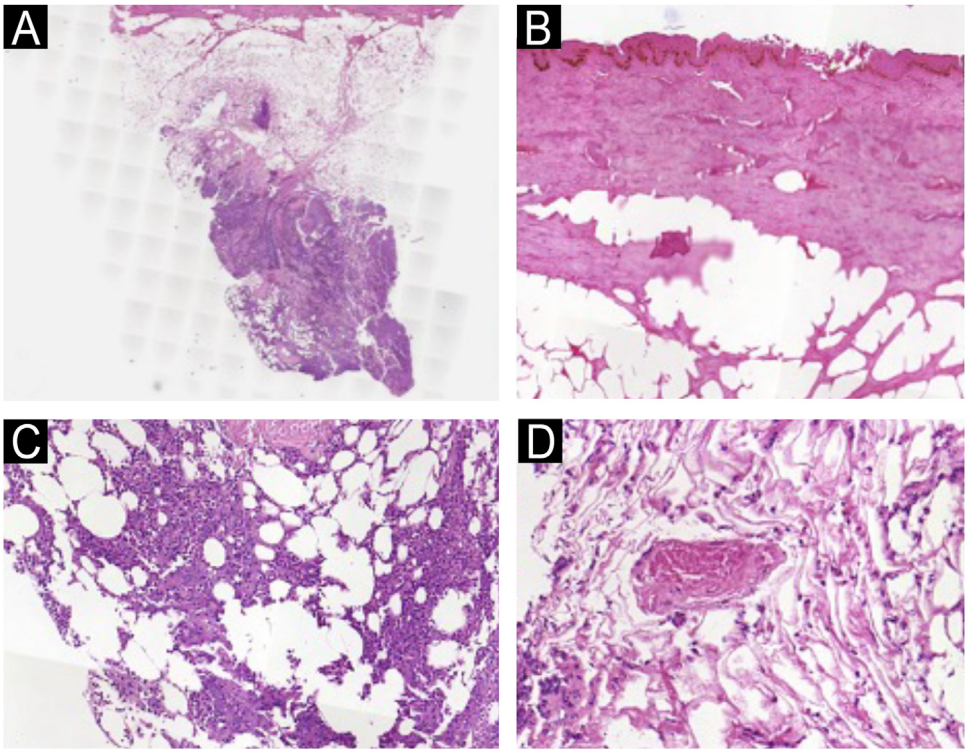

Figure 2 (A) Biopsy showing an intense inflammatory infiltrate in the fascia (Hematoxylin & eosin, ×20). (B) Epidermis with coagulative necrosis (Hematoxylin & eosin, ×20). (C) In the fascia, intense neutrophilic infiltrate, necrosis (Hematoxylin & eosin, ×20), and (D) thickening of vessels (Hematoxylin & eosin, ×20).

Figure 3 Patient after treatment.

indicative of advanced disease. When NF is suspected, it is imperative to obtain a contrast imaging exam (computed tomography or preferably magnetic resonance) to assess inflammatory changes, edema, fluid collection or abscesses, fascial enhancement, and gas formation.[1,2]

Early and extensive surgical debridement is the mainstay of treatment. Immediate reconstruction is not recommended and should be delayed until the infection has been contained.[1–6] Cultures obtained from the tissue can guide long-term antibiotic therapy.

Research data availability

Does not apply.

Editor

Sílvio Alencar Marques.

Financial support

The author(s) received no financial support for the research, authorship, and/or publication of this article.

Authors' contributions

Giovanna Gelli Carrascoza: Contributed to the approval of the final version of the manuscript, critical literature review, data collection, analysis and interpretation, intellectual participation in propaedeutic and/or therapeutic management of studied cases, manuscript critical review, preparation, and writing of the manuscript and study conception and planning.

Denis Miyashiro: Contributed to the approval of the final version of the manuscript, critical literature review, data collection, analysis and interpretation, effective participation in research orientation, intellectual participation in propaedeutic and/or therapeutic management of studied cases, manuscript critical review, preparation and writing of the manuscript and study conception and planning.

Murilo Perin da Silva: Contributed to the approval of the final version of the manuscript, data collection, analysis, and interpretation, intellectual participation in propaedeutic and/or therapeutic management of studied cases, and manuscript critical review.

Talita Georgeana Baratieri Pinheiro: Contributed to the approval of the final version of the manuscript, data collection, analysis, and interpretation, intellectual participation in propaedeutic and/or therapeutic management of studied cases, manuscript critical review.

Suheyla Pollyana Pereira Ribeiro: Contributed to the approval of the final version of the manuscript, critical literature review, data collection, analysis and interpretation, intellectual participation in propaedeutic and/or therapeutic management of studied cases, manuscript critical review, preparation and writing of the manuscript and study conception and planning.

José Antonio Sanches: Contributed to the approval of the final version of the manuscript, critical literature review, data collection, analysis and interpretation, effective participation in research orientation, intellectual participation in propaedeutic and/or therapeutic management of studied cases, manuscript critical review, preparation and writing of the manuscript and study conception and planning.

Conflicts of interest

None declared.

References

1. Marques SA, Abbade LPF. Severe bacterial skin infections. An Bras Dermatol. 2020;95:407–17.
2. Miller LE, Shaye DA. Noma and necrotizing fasciitis of the face and neck. Facial Plast Surg. 2021;37:439–45.
3. Choi MS. Necrotizing fasciitis of the head and neck: a case report. J Korean Assoc Oral Maxillofac Surg. 2015;41:90–6.
4. Schröder A, Gerin A, Firth GB, Hoffmann KS, Grieve A, Oetzmann von Sochaczewski C. A systematic review of necrotising fasciitis in children from its first description in 1930 to 2018. BMC Infect Dis. 2019;19:317.
5. Bingöl-Koloğlu M, Yildiz RV, Alper B, Yağmurlu A, Ciftçi E, Gökçora IH, et al. Necrotizing fasciitis in children: diagnostic and therapeutic aspects. J Pediatr Surg. 2007;42:1892–7.
6. Karan NB, Kose R, Kalyoncu A, Sekeryapan B, Oter K, Findik H, et al. Fatal orbital necrotizing fasciitis secondary to *Stenotrophomonas maltophilia* associated stomatitis. J Stomatol Oral Maxillofac Surg. 2019;120:260–2.

Giovanna Gelli Carrascoza [a,*], Denis Miyashiro [a], Murilo Perin da Silva [a], Talita Georgeana Baratieri Pinheiro [b], Suheyla Pollyana Pereira Ribeiro [c], José Antonio Sanches [a]

[a] *Dermatology Department, Faculty of Medicine, Universidade de São Paulo, São Paulo, SP, Brazil*
[b] *Pediatrics Department, Faculty of Medicine, Universidade de São Paulo, São Paulo, SP, Brazil*
[c] *Radiology Department, Faculty of Medicine, Universidade de São Paulo, São Paulo, SP, Brazil*

[*] Corresponding author.
E-mail: gi.carrascoza@gmail.com (G.G. Carrascoza).

Received 30 December 2024; accepted 6 February 2025
Available online 19 August 2025

SOCIEDADE BRASILEIRA DE DERMATOLOGIA

Anais Brasileiros de Dermatologia

www.anaisdedermatologia.org.br

LETTER - CLINICAL

Paradoxical lichenoid reaction during dupilumab treatment-Case report and literature review☆

Dear Editor,

Paradoxical reactions (PRs) are defined as the onset of new or the exacerbation of existing immune-mediated disorders following the initiation of targeted biologic therapies.[1,2] Dupilumab, an IL-4Rα inhibitor, is effective for atopic dermatitis (AD) but may trigger PRs. While paradoxical psoriasiform or head and neck dermatitis are common, lichenoid reactions remain rare.[2] We present a case of dupilumab-induced paradoxical lichenoid reaction with erythroderma and review existing literature to identify clinical patterns.

A 64-year-old male with refractory AD developed erythroderma 4 months after initiating dupilumab therapy. He reported improved pruritus and lesions after the first dose of dupilumab (600 mg). However, he began developing pruritic scaly erythematous patches since the second dose of dupilumab (300 mg every other week), which gradually progressed to erythroderma and hyperpigmentation. Physical examination revealed diffuse erythema, scaling, and symmetrical violaceous papules on the dorsal hands (Fig. 1A–C). Histopathology demonstrated lichenoid dermatitis, featuring parakeratosis, necrotic keratinocytes, and a band-like dermal infiltrate of lymphocytes and histiocytes (Fig. 2A–C). Immunohistochemistry (IHC) confirmed the presence of T-cell (Fig. 3A–B; CD4 and CD8; CD4/CD8 ratio of 3:2) and histiocytic proliferation (Fig. 3C; CD68). IHC staining also confirmed the expression of CD3, CD5, and CD7, while showing negativity for CD20, perforin, and granzyme B. Few cells were positive for Langerin. Dupilumab was discontinued after the fifth dose. Treatment with oral methylprednisolone, upadacitinib, antihistamines, and topical steroids led to erythema resolution within 3-weeks, though hyperpigmentation persisted. At 3-month follow-up, no disease flares occurred, and pruritus remained controlled. Concomitant medications (betastin, cetirizine) had been used long-term without prior adverse effects, supporting dupilumab as the likely trigger. This case highlights dupilumab-induced lichenoid reaction manifesting as erythroderma, necessitating histopathological confirmation for timely intervention.

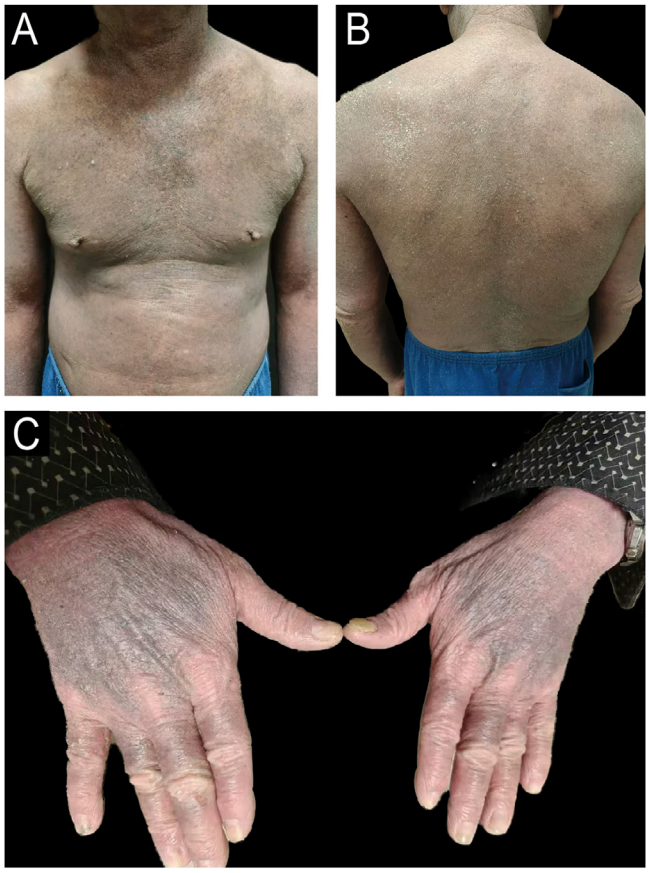

Fig. 1 (A–B) The patient presented to our hospital with generalized erythema, hyperpigmentation and scaling over the entire body. (C) Symmetrical flat-topped violaceous papules were observed on the dorsal hands.

A review of seven reported cases of dupilumab-associated lichenoid reactions was conducted (Table 1).[3–7] Patients predominantly affected were female (71.4%, 5/7) with a mean age of 45.3 years, all diagnosed with AD. The

☆ Study conducted at the First Affiliated Hospital, Fujian Medical University, Fuzhou, Fujian, China.

https://doi.org/10.1016/j.abd.2025.501192

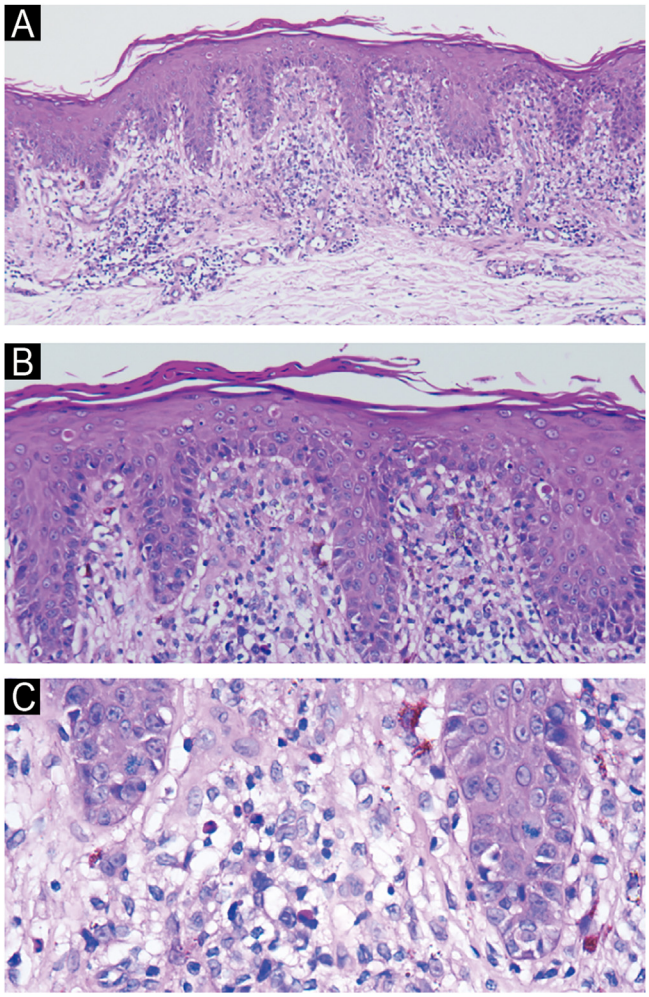

Fig. 2 (A–C) Histopathology revealed epidermal parakeratosis, acanthosis, scattered necrotic keratinocytes and basilar vacuolar change. A band-like infiltrate of lymphocytes, histiocytes, melanophages, eosinophils, and neutrophils was present at the dermoepidermal junction. (A, Hematoxylin & eosin ×10; B, Hematoxylin & eosin ×20; C, Hematoxylin & eosin ×40).

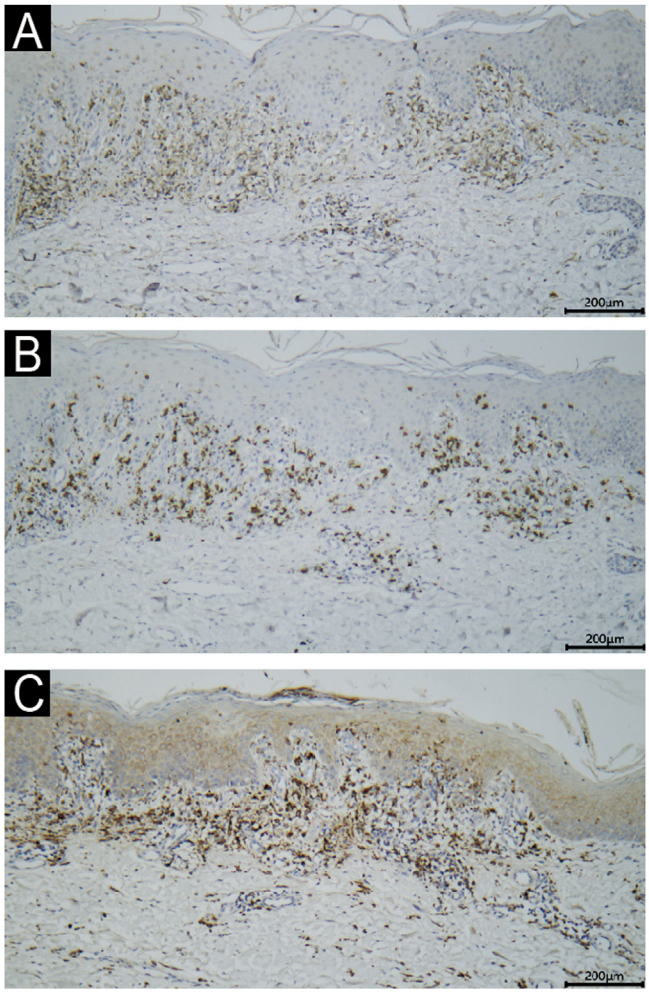

Fig. 3 Immunohistochemical staining demonstrated that the lymphocytes stained positive for CD4 (A, ×10) and CD8 (B, ×10), with a CD4/CD8 ratio of approximately 3:2. The histiocytes stained positive for CD68 (C, ×10).

median latency from dupilumab initiation to lichenoid reactions was 29.7 weeks. Clinically, 85.7% (6/7) presented with lichen planus (LP) like violaceous papules or plaques, while 28.6% (2/7) developed erythroderma. Lesions primarily involved the hands and extremities (85.7%) and trunk (57.1%), with oral mucosa involvement in 28.6%. Histopathology categorized lichenoid reactions into three subtypes: classic LP-type (33%), lichenoid drug eruption (LDE)-type (33%), and lichenoid granulomatous reaction (LGR)-type (33%), the latter characterized by granulomatous inflammation with eosinophils and histiocytes. The histopathological findings in this case are consistent with LDE-type, characterized by lichenoid interface dermatitis accompanied by parakeratosis and a mixed infiltration of lymphocytes, histiocytes, and eosinophils. Management universally included dupilumab discontinuation (85.7%), with systemic therapies such as glucocorticoids (57.1%), JAK inhibitors (28.6%), and cyclosporine or methotrexate (14.3%) employed. Resolution occurred within a median of 15.8 weeks post-treatment. Notably, two cases exhibited persistent post-inflammatory hyperpigmentation.[4] These findings underscore the variability in dupilumab-induced lichenoid reactions, emphasizing the need for early recognition via biopsy and tailored immunomodulatory strategies.

This case highlights dupilumab-induced lichenoid reaction presenting as erythroderma. This patient was initially misdiagnosed as an exacerbation of AD, leading to the continued administration of dupilumab, which further worsened the patient's symptoms. However, subsequent histological examination confirmed the diagnosis of paradoxical lichenoid reaction, enabling the appropriate treatment and subsequent disease remission. Histopathology and immunohistochemistry revealed $CD8^+$ T-cell infiltration and histiocytic proliferation, aligning with a delayed hypersensitivity reaction.[8] The absence of perforin and granzyme-B suggests alternative pathways beyond cytotoxic T-cell activity, possibly involving Th1/Th2 imbalance. The downregulation of the Th2 response characteristic of AD could promote a Th1 response by increasing Th1 cell activity and IFN-γ production due to IL-4 antagonism.[3]

These findings emphasize the need for heightened vigilance regarding paradoxical reactions during biologic

Table 1 Cases of lichenoid reactions associated with dupilumab therapy.

Author (year)	Age/ Sex	Primary disease	Latent period	Clinical manifestations	Distribution patterns	Histopa-thology	Diagnosis	Treatment for lichenoid reaction	Resolution time	Treatment response
Tae-Eun et al. (2021) [3]	44, M	AD	4 months	Localized flat-topped erythematous to violaceous papules and plaques	Dorsum of both hands	LP type	Lichenoid reaction	Cessation of dupilumab and cyclosporin	3 months after dupilumab cessation	Partial response
Laura et al. (2022) [4]	23, F	AD	11 months	Flat-topped violaceous papules	Wrists, fingers, abdominal wall, upper thighs, lower legs and oral mucosa	LP type	Drug-induced lichen planus	Cessation of dupilumab and systematic glucorticosteroids	4 months after dupilumab cessation	Marked improvement with hyperpigmentation
Mark et al. (2022) [5]	18, F	AD	14 months	Erythematous plaques with scale	Chest and abdomen	LDE type	Lichenoid reaction	Cessation of dupilumab and upadacitinib	NA	Na
Luca et al. (2022) [6]	60 s, F	AD	More than a year	Papular, polygonal, confluent, very itchy lesions	Upper and lower extremities	NA	Lichen ruber planus	Continuation of dupilumab, systematic glucorticosteroids and topical glucorticosteroids	4 months after treatment	Complete resolution with residual lichenification and xerosis

Table 1 (*Continued*)

Author (year)	Age/ Sex	Primary disease	Latent period	Clinical manifestations	Distribution patterns	Histopathology	Diagnosis	Treatment for lichenoid reaction	Resolution time	Treatment response
Zahra et al. (2023) [7]	72, F	AD	1) 15 months; 2) 24 months; 3) 28 months	1) Erosive lichenoid mucositis; 2) Violaceous, indurated plaques; 3) Erythroderma	1) Oral mucosa; 2) Widespread; 3) Widespread, including hands	LGR type	Lichenoid granulomatous drug reaction	1) Continuation of dupilumab, systematic glucorticosteroids and alitretinoin; 2) Continuation of dupilumab, systematic glucorticosteroids and topical glucorticosteroids; 3) Acitretin with no improvement, methotrexate, and cessation of dupilumab	6 months after dupilumab cessation	Complete clearance
	51, F	AD	15 months	Erythematous and indurated plaques with lichenification and fissuring	Predominantly hands	LGR type	Lichenoid granulomatous drug reaction	Cessation of dupilumab and methotrexate	A period of months after dupilumab cessation	Complete clearance
Present case	64, M	AD	2 weeks	Pruritic scaly erythematous plaques progressing to erythroderma; and violaceous papules	Widespread and dorsum of both hands	LDE type	Lichenoid reaction	Cessation of dupilumab, systematic glucorticosteroids, antihistamines, topical steroids and upadacitinib	11 weeks after dupilumab cessation	Complete resolution with hyperpigmentation

F, Female; M, Male; AD, Atopic Dermatitis; LP, Lichen Planus; LDE, Lichenoid Drug Eruption; LGR, Lichenoid Granulomatous reaction; NA, Not Available.

therapies. In addition, AD is associated with higher risks of Cutaneous T-Cell Lymphoma (CTCL), which could also mimic eczematous skin lesions or erythroderma, requiring skin biopsy for accurate diagnosis.[9] Clinically, violaceous plaques or sudden erythroderma in dupilumab-treated patients warrant immediate biopsy to differentiate other conditions, including lichenoid reaction and CTCL from AD exacerbation. Continued dupilumab administration in misdiagnosed cases risks worsening symptoms, as observed here. Discontinuation of dupilumab, combined with systemic steroids or JAK inhibitors (e.g., upadacitinib), achieved rapid remission in this and prior cases, though post-inflammatory hyperpigmentation may persist. While JAK inhibitors show promise in managing PRs, further research is required to elucidate precise molecular mechanisms and optimize therapeutic strategies.[10]

Research data availability

Does not apply.

Editor

Hiram Larangeira de Almeida Jr.

Financial support

None declared.

Authors' contributions

Fuchen Huang: Conception and design of the study; data collection, or analysis and interpretation of data; statistical analysis; writing of the manuscript; data acquisition, analysis, and interpretation; critical review of the literature.

Zequn Tong: Analysis and interpretation of data; critical revision of the manuscript for important intellectual content.

Xueting Zeng: Analysis and interpretation of data; critical revision of the manuscript for important intellectual content.

Jiawen Chen: Analysis and interpretation of data; critical revision of the manuscript for important intellectual content.

Ying Zou: Critical revision of the manuscript for important intellectual content.

Chao Ji: Significant participation in research supervision; critical revision of the manuscript for important intellectual content.

Conflicts of interest

None declared.

References

1. Miyagawa F. Pathogenesis of paradoxical reactions associated with targeted biologic agents for inflammatory skin diseases. Biomedicines. 2022;10:1485.
2. Murphy MJ, Cohen JM, Vesely MD, Damsky W. Paradoxical eruptions to targeted therapies in dermatology: A systematic review and analysis. J Am Acad Dermatol. 2022;86:1080–91.
3. Kim TE, Shin MK. De novo case of lichenoid eruption following dupilumab treatment. JAAD Case Rep. 2021;13:71.
4. Kern L, Kleinheinrich L, Feldmann R, Sator P, Stella A, Breier F. Dupilumab-induced lichen planus: a case with oral and cutaneous eruptions. Case Rep Dermatol. 2022;14:356–61.
5. Derbyshire M, Beatty C, Marks K, Kazlouskaya V. Lichenoid eruption during treatment of atopic dermatitis with dupilumab. Int J Dermatol. 2023;62:1202–3.
6. Mastorino L, Ortoncelli M, Giura MT, Avallone G, Viola R, Quaglino P, et al. Lichen ruber planus arising during dupilumab treatment for atopic dermatitis. Ital J Dermatol Venerol. 2022;157:449–50.
7. Rehan Z, Pratt MD, Teo I, Petkiewicz S, Ayroud Y, Evans J, et al. Lichenoid-granulomatous drug reactions to dupilumab: a report of 2 cases. JAAD Case Rep. 2023;33:13.
8. Braswell DS, Hakeem A, Walker A, Sokumbi O, Kapil J, Motaparthi K. Lichenoid granulomatous dermatitis revisited: a retrospective case series. J Am Acad Dermatol. 2019;81:1157–64.
9. Wan J, Shin DB, Syed MN, Abuabara K, Lemeshow AR, Fuxench ZCC, et al. Malignancy risk in patients with atopic dermatitis: a population-based cohort study. Br J Dermatol. 2023;189:53–61. Erratum in: Br J Dermatol. 2024;190:e49.
10. Zhang Y, Jiang G. Application of JAK inhibitors in paradoxical reaction through immune-related dermatoses. Front Immunol. 2024;15:1341632.

Fuchen Huang [a,b,c], Zequn Tong [a,b,c], Xueting Zeng [a,b,c], Jiawen Chen [a,b,c], Ying Zou [a,b,c], Chao Ji [a,b,c,*]

[a] *Department of Dermatology, First Affiliated Hospital, Fujian Medical University, Fuzhou, Fujian, China*
[b] *Fujian Dermatology and Venereology Research Institute, First Affiliated Hospital, Fujian Medical University, Fuzhou, Fujian, China*
[c] *Key Laboratory of Skin Cancer, Fujian Higher Education Institutions, Fuzhou, Fujian, China*

* Corresponding author.
E-mail: jichaofy@fjmu.edu.cn (C. Ji).

Received 12 March 2025; accepted 20 April 2025
Available online 22 August 2025

SOCIEDADE BRASILEIRA DE DERMATOLOGIA

Anais Brasileiros de Dermatologia

www.anaisdedermatologia.org.br

LETTER - CLINICAL

Penile erosions: an atypical initial manifestation of pemphigus vulgaris☆

Dear Editor,

Pemphigus represents a group of rare intraepidermal bullous autoimmune diseases.[1] Pemphigus vulgaris (PV) is the most common subtype of pemphigus and is characterized by the presence of autoantibodies directed against epithelial adhesion proteins, Desmogleins (Dsg) 1 and 3, resulting in a loss of cell adhesion between keratinocytes.[2–4] Penile involvement in PV is rarely documented, particularly as the initial manifestation of the disease.[1,2,5] We report an atypical case of PV with onset in the penis and without involvement of other mucous membranes during the course of the disease.

A 52-year-old man presented with a 4-month history of painful penile erosions involving the glans and inner foreskin (Fig. 1). He had previously been diagnosed with candidiasis, balanoposthitis, and impetigo and was treated for those conditions without improvement. At the time of presentation to our department, the dermatosis had evolved with the appearance of lesions in other locations, namely flaccid blisters, erosions and adherent crusts in the inguinal region, trunk and scalp (Fig. 2) leading to the diagnostic hypothesis of PV. Histological examination of lesional skin was suggestive of PV (Fig. 3) and direct immunofluorescence in perilesional skin revealed intercellular deposits of IgG and C3 in the lower epidermis. Serum levels (detected by ELISA) of anti-Dsg-1 and anti-Dsg-3 IgG autoantibodies were >200 U/mL (normal <20) and 149,2 U/mL (normal <20), respectively, confirming the diagnosis. The patient was treated with oral prednisolone 100 mg/day (1 mg/kg body weight/day) along with azathioprine 150 mg/day. Due to the elevation of the liver enzyme levels, azathioprine was discontinued, and rituximab was started (two infusions of 1 g two weeks apart and an infusion of 1 g after 6-months as maintenance therapy). This resulted in a favorable clinical response with normalization of anti-Dsg 1 and 3 values, accompanied by a progressive reduction in prednisone dose over 6-months. The penile lesions took the longest time to heal and after 24-months of follow-up, the patient remains relapse-free.

Fig. 1 Penile erosions involving the glans and inner foreskin.

Although PV often manifests in the oral mucosa, involvement of other mucous membranes is less common and there are few cases reports in the literature of the penis being affected.[1] In the present case, the initial presentation consisted of painful erosions on the penis. While subsequent involvement of other areas of the tegument was observed, the disease did not affect other mucous membranes. A study analyzing 12 patients with penile pemphigus[5] found that 11 had oral involvement, 2 had esophageal involvement, and one patient each had involvement of the larynx, epiglottis, and conjunctiva. This highlights how uncommon is the involvement of the penis without the involvement of other mucous membranes.

In female patients, genital involvement is more frequent and is significantly associated with nasal involvement and

☆ Study conducted at the Dermatology and Venereology Department, Hospital Garcia de Orta EPE, Almada, Portugal.

https://doi.org/10.1016/j.abd.2025.501189

Fig. 2 Flaccid blisters, erosions and adherent crusts in the trunk.

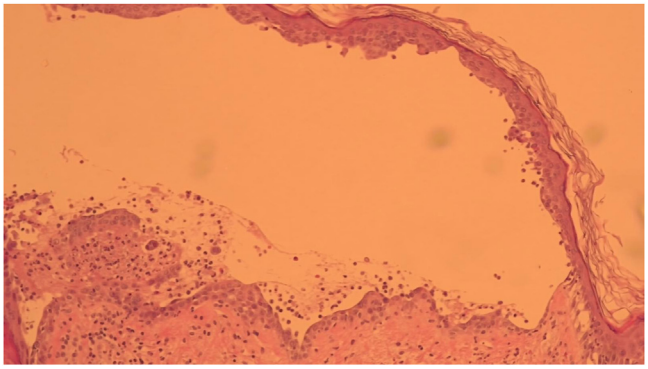

Fig. 3 Suprabasal intraepidermal cleft with acantholytic cells, consistent with pemphigus vulgaris. Haematoxylin and eosin, original magnification 100×.

genital symptoms.[6,7] Usually occurs when other sites are extensively affected.[7] Involvement of the cervix, vagina and vulva has been described either concomitantly with other affected sites or when other involved sites were already in remission.[7]

In our patient the distinctive location in the genital region initially prompted the formulation of alternative diagnoses, resulting in the administration of unwarranted therapeutic interventions, a postponement in the diagnosis and a deterioration in the condition. Other differential diagnoses should include herpes simplex and drug-induced eruptions, both of which can present with similar erosion lesions. In addition, herpes infection has been associated with PV and may complicate therapeutic management.[8]

Clinicians should consider immunobullous diseases, such as bullous pemphigoid, mucous membrane pemphigoid, and PV as a cause for chronic mucosal lesions at genital sites. The presence of genital lesions may be associated with treatment resistance.[1] Although rare, PV should be part of the differential diagnosis of painful erosions on the penis and, if in doubt, biopsies should be taken.

Editor

Ana Maria Roselino.

Research data availability

Does not apply.

Financial support

None declared.

Authors' contributions

Hugo J. Leme: Preparation and writing of the manuscript; approval of the final version of the manuscript.

José Ramos: Approval of the final version of the manuscript; manuscript critical review.

António Magarreiro Silva: Approval of the final version of the manuscript; manuscript critical review.

Ana Isabel Gouveia: Approval of the final version of the manuscript; manuscript critical review.

João Alves: Approval of the final version of the manuscript; manuscript critical review.

Conflicts of interest

None declared.

References

1. Su O, Dizman D, Ozkaya BD, Yildiz P, Demirkesen C, Onsun N. Pemphigus vulgaris localised exclusively to the penis. Indian J Dermatol Venereol Leprol. 2015;81:298–9.
2. Stieger M, Pelivani N, Ramelet AA, Beltraminelli H, Borradori L. Penile erosions as first manifestation of pemphigus vulgaris: A misleading presentation. Acta Derm Venereol. 2013;93:248–9.
3. Nayak V, Kini R, Rao PK, Shetty U. Pemphigus vulgaris. BMJ Case Rep. 2020;13:e235410.
4. Thanmai JV, Ramlal G, Tejaswi K, Mounica IL. Pemphigus vulgaris: a case report. Pan Afr Med J. 2022;42:184.
5. Sami N, Ahmed AR. Penile pemphigus. Arch Dermatol. 2001;137:756–8.
6. Kavala M, Demir FT, Zindanci I, Can B, Turkoglu Z, Zemheri E, et al. Genital involvement in pemphigus vulgaris (PV): Correlation with clinical and cervicovaginal Pap smear findings. J Am Acad Dermatol. 2015;73:655–9.
7. Batta K, Munday PE. Pemphigus vulgaris localized to the vagina presenting as chronic vaginal discharge. Br J Dermatol. 1999;140:945–7.
8. Machado AR da SR, La Serra L, Turatti A, Machado AM, Roselino AM. Herpes simplex virus 1 and cytomegalovirus are associated with pemphigus vulgaris but not with pemphigus foliaceus disease. Exp Dermatol. 2017;26:966–8.

Hugo J. Leme *, José Ramos ,
António Magarreiro-Silva , Ana Isabel Gouveia ,
João Alves

Dermatology and Venereology Department, Hospital Garcia de Orta EPE, Almada, Portugal

* Corresponding author.
E-mail: hugojleme@gmail.com,
hugo.leme@ulsas.min-saude.pt (H.J. Leme).

Received 31 January 2025; accepted 5 April 2025
Available online 9 August 2025

SOCIEDADE BRASILEIRA DE DERMATOLOGIA

Anais Brasileiros de Dermatologia

www.anaisdedermatologia.org.br

LETTER - CLINICAL

Posterior reversible encephalopathy syndrome in a patient treated with ustekinumab☆

Dear Editor,

Ustekinumab, a monoclonal antibody targeting the p40 subunit of Interleukin (IL)-12 and IL-23, is a safe and effective treatment for psoriasis.[1] Although most patients do not experience serious adverse effects, some neurological conditions have been reported.[2–6]

This report describes a case of posterior reversible encephalopathy syndrome (PRES) caused by ustekinumab.

The study was approved by the Research Ethics Committee, number 78147224.3.0000.5515, and the patient signed the informed consent form.

A 47-year-old male patient with psoriasis vulgaris for 20 years presented with erythematous-scaly plaques covering 28% of his body surface area, with a Psoriasis Area and Severity Index (PASI) of 24.4. He had a history of alcoholism, grade II hepatic steatosis, and controlled arterial hypertension. He developed disease progression, previous intolerance to methotrexate, and no response to acitretin.

It was decided to initiate ustekinumab, 90 mg (dose adjusted to weight >100 kg), at weeks 0 and four, subcutaneously, and maintenance every 12 weeks. After the second dose (week six), the patient suddenly developed mental confusion. He was hospitalized, ustekinumab was suspended due to suspicion as the causative agent, and he was treated with risperidone, antihypertensives, promethazine, and lactulose. On the third day, he developed headache and tetraparesis.

A magnetic resonance imaging (MRI) of the brain revealed bilateral foci of hyperintensity in the periventricular and subcortical white matter of the frontal and parietal lobes on fluid-attenuated inversion recovery (FLAIR) and diffusion-weighted sequence (DWI) images, and foci of hypointensity in the reconstruction of the apparent diffusion coefficient (ADC) maps, characterizing restricted mobility of water molecules, and consistent with true restriction caused by ischemic foci (Fig. 1). The findings were consistent with the PRES diagnosis. Laboratory investigations ruled out infections and metabolic or inflammatory diseases, such as autoimmune ones, and it was impossible to rule out the occurrence of an epiphenomenon.

The neurological symptoms were reversed with supportive measures and he was discharged from the hospital on the 10th day with oral memantine hydrochloride.

An MRI of the brain three months later showed the same hyperintense foci on FLAIR, with no changes in the DWI sequences and ADC map, corresponding to small areas of gliosis (scars).

One year later, the patient had a PASI of zero, with no neurological deficits.

Immunobiologicals represent an advance in the treatment of psoriasis and have been increasingly used.[1] Serious side effects have been reported, mainly with anti-TNF-α. Ustekinumab, although safe, can also cause severe reactions, including neurological complications, such as PRES (Table 1),[1–6] this being the first case documented in Brazil and the seventh in the world. The development of PRES can occur soon after induction,[4,6] as in this case, or after years of using ustekinumab.[2,3,5]

PRES is an uncommon, often reversible, severe neurological disorder with acute symptoms including headache, visual changes, paresis, nausea, altered consciousness, and seizures.[7,8]

It seems to result from loss of cerebral vascular autoregulation or endothelial dysfunction, most commonly associated with malignant hypertension, eclampsia, and immunosuppressive agents such as corticosteroids, mycophenolate, cyclosporine, cyclophosphamide, and methotrexate.[6–8] The name is imprecise, as it is not an alteration exclusive to the posterior brain regions and does not always lead to complete reversion.[6–8]

The MRI ensures the diagnosis and predicts prognosis, assessing whether or not the lesions are reversible. The classic findings are bilateral diffuse or focal symmetrical hyperintense signal on FLAIR images, predominantly in the white matter, involving the posterior regions, mainly the occipital and parietal lobes. Atypical images, including involvement of the frontal lobe, basal ganglia, temporo-

☆ Study conducted at the Department of Dermatology, Hospital Regional de Presidente Prudente, Universidade do Oeste Paulista, Presidente Prudente, SP, Brazil.

https://doi.org/10.1016/j.abd.2025.501177

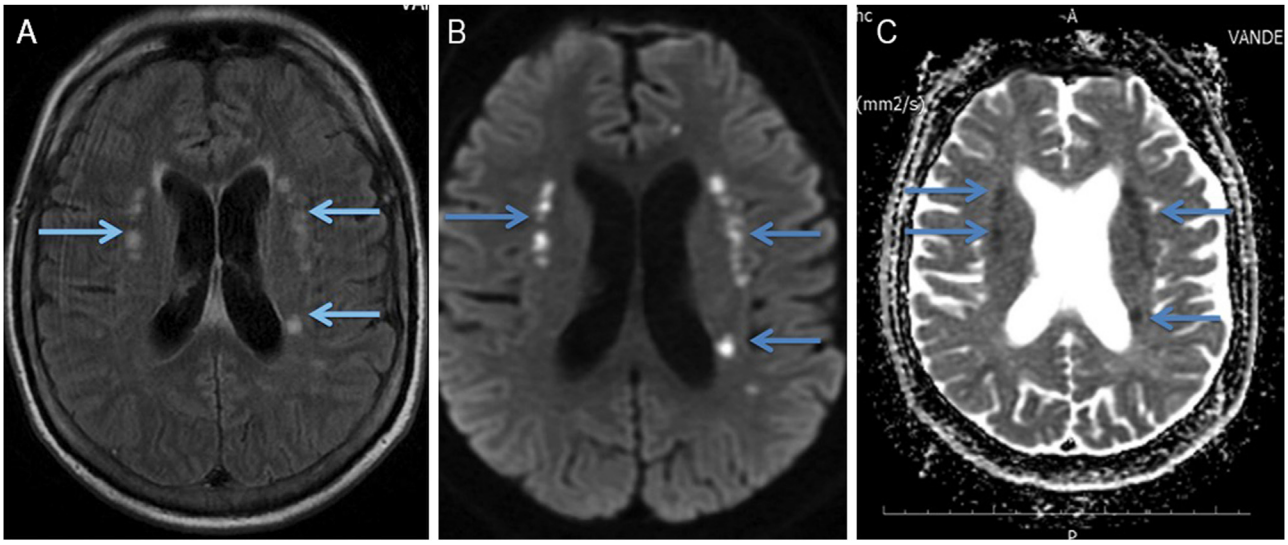

Figure 1 Magnetic resonance imaging of the brain. (a) FLAIR (fluid-attenuated inversion recovery) showing small foci of hyperintense signal in the periventricular and subcortical white matter of the bilateral frontal and parietal lobes. (b) DWI (diffusion-weighted imaging) showing hyperintense signal from the punctate foci seen on FLAIR (fluid-attenuated inversion recovery), suggesting cytotoxic edema. (c) ADC (apparent diffusion coefficient) MAP confirms the diffusion findings, showing restricted diffusion.

Table 1 Characteristics of cases of Posterior Reversible Encephalopathy Syndrome (PRES) associated with ustekinumab reported in the literature.

Authors/Year	Age/Sex	Dose	Time of treatment from symptom onset	Indication	Clinical evolution: Persistent neurological deficit	Radiological evolution: Persistent radiological images
Gratton et al., 2011[2]	65/Female	45 mg every 12 weeks	2 1/2 years	Psoriasis	No	No
Dickson, Menter, 2017[3]	58/Male	90 mg every eight weeks	6 years	Psoriasis and psoriatic arthritis	No	No
Mishra, Seril, 2018[4]	18/Female	340 mg single induction dose	12 days following induction	Crohn's Disease	No	No
Mishra, Seril, 2018[4]	54/Male	390 mg single induction dose	6 days following induction	Crohn's Disease	No	No
Jordan, Kinnucan, 2022[5]	64/Female	90 mg every eight weeks	2 1/2 years	Crohn's Disease	Difficulty walking	Yes (one month later)
Sarto et al., 2022[6]	48/Male	390 mg followed by 90 mg at week eight	30 days after the second dose	Crohn's Disease	No	Yes (18 months later)
Este estudo	47/Male	90 mg at weeks 0 and four	14 days after the second dose	Psoriasis	No	Yes (three months later)

occipital junction, and cerebellum, do not rule out the diagnosis.[7]

Most cases lead to neurotoxicity related to vasogenic edema, with no restriction on DWI sequence, and are reversible. However, approximately 11% to 26% of cases of infarction or tissue injury with cytotoxic edema, which is seen as restricted diffusion, evolving with sequelae [7] are described as in this patient, who evolved with permanent imaging lesions, perhaps due to a delayed diagnosis.[2–4]

There is no consensus on PRES treatment, but it is directed at the precipitating cause, in addition to manage-

ment with antiepileptics. Symptoms usually resolve in one or two weeks.[9]

Despite the safety of ustekinumab and other drugs increasingly used in dermatological practice, the present case emphasizes their association with the occurrence of potentially serious neurological events. Early recognition and adequate management would prevent or reduce possible neurological sequelae and fatal outcomes.

Research data availability

Does not apply.

Editor

Sílvio Alencar Marques.

Financial support

None declared.

Authors' contributions

Marilda Aparecida Milanez Morgado de Abreu: Approval of the final version of the manuscript; design and planning of the study; effective participation in research orientation; intellectual participation in the propaedeutic and/or therapeutic conduct of the studied cases; critical review of the literature; critical review of the manuscript.

Naíra M. de A. Guaresemin: Design and planning of the study; drafting and editing of the manuscript; collection, analysis, and interpretation of data; intellectual participation in the propaedeutic and/or therapeutic conduct of the studied cases; critical review of the literature.

Murilo de Oliveira Lima Carapeba: Design and planning of the study; drafting and editing of the manuscript; collection, analysis, and interpretation of data; intellectual participation in the propaedeutic and/or therapeutic conduct of the studied cases; critical review of the literature.

Conflicts of interest

None declared.

References

1. Silva DLFD, Secamilli EN, Beleli MV, Massuda JY, Franca AFEC, Magalhães RF. Immunobiologicals in dermatology. An Bras Dermatol. 2022;97:275–83.
2. Gratton D, Szapary P, Goyal K, Fakharzadeh S, Germain V, Saltiel P. Reversible posterior leukoencephalopathy syndrome in a patient treated with ustekinumab: case report and review of the literature. Arch Dermatol. 2011;147:1197–202.
3. Dickson L, Menter A. Reversible posterior leukoencephalopathy syndrome (RPLS) in a psoriasis patient treated with ustekinumab. J Drugs Dermatol. 2017;16:177–9.
4. Mishra A, Seril DN. Posterior reversible encephalopathy syndrome following ustekinumab induction for Crohn's disease. Case Rep Gastroenterol. 2018;12:521–7.
5. Jordan A, Kinnucan J. Ustekinumab-associated posterior reversible encephalopathy syndrome in a patient with Crohn's disease. ACG Case Rep J. 2022;9:e00867.
6. Sarto J, Caballol B, Berenguer J, Aldecoa I, Carbayo Á, Santana D, et al. Clinically reversible ustekinumab-induced encephalopathy: case report and review of the literature. Ther Adv Neurol Disord. 2022;15:17562864221079682.
7. Silva CJ, Rocha AJ. Encefalopatias tóxicas, nutricionais e neurometabólicas adquiridas. In: Rocha AJ, Vedolin L, Mendonça RA, editors. Encéfalo. Rio de Janeiro: Elsevier; 2012. p. 247–88.
8. Pirola JP, Baenas DF, Haye Salinas MJ, Benzaquén NR, Colazo M, Borghi MV, et al. Posterior reversible leukoencephalopathy syndrome: case series and review of the literature. Reumatol Clin (Engl Ed). 2020;16:169–73.
9. Hobson EV, Craven I, Blank SC. Posterior reversible encephalopathy syndrome: a truly treatable neurologic illness. Perit Dial Int. 2012;32:590–4.

Marilda Aparecida Milanez Morgado de Abreu [a,*],
Naíra M. de A. Guaresemin [b],
Murilo de Oliveira Lima Carapeba [a]

[a] *Department of Dermatology, Hospital Regional de Presidente Prudente, Universidade do Oeste Paulista, Presidente Prudente, SP, Brazil*
[b] *Department of Radiology and Diagnostic Imaging, Hospital Rio Preto, São José do Rio Preto, SP, Brazil*

* Corresponding author.
E-mail: marilda@morgadoeabreu.com.br
(M.A. Morgado de Abreu).

Received 18 July 2024; accepted 14 October 2024
Available online 9 August 2025

SOCIEDADE BRASILEIRA DE DERMATOLOGIA

Anais Brasileiros de Dermatologia

www.anaisdedermatologia.org.br

LETTER - CLINICAL

Recurrent metastatic malignant peripheral nerve sheath tumor associated with neurofibromatosis I: a rare case with atypical immunohistochemistry☆

Dear Editor,

Malignant Peripheral Nerve Sheath Tumor (MPNST) is an extremely rare tumor (1/100,000) that represents up to 10% of sarcomas, divided into those related to Neurofibromatosis type 1 (NF1), which corresponds to 50% of cases, and sporadic ones.[1,2] The most widely accepted hypothesis today is that NF1-related MPNST arises from a neurofibroma that undergoes multiple genetic and phenotypic alterations until transforming into a malignant lesion. It presents diagnostic criteria that are not yet consolidated in the literature due to its variable morphological, immunohistochemical (IHC), and genetic pattern, which is not yet fully elucidated.[2,3] Thus, this case demonstrates an evolution of NF1-related MPNST, the diagnostic difficulties, as well as the role of the dermatologist in the final diagnosis of the neoplasm.

A 43-year-old white male patient, a waiter with no known comorbidities, complained of a progressively growing mass on his right thigh for three months, with intense local pain associated with the externalization of the tumor 30 days before (Fig. 1). Dermatological examination revealed a violaceous tumor mass measuring approximately 23 cm with areas of hemorrhage, necrosis, and a fistulous tract with fetid serosanguineous drainage.

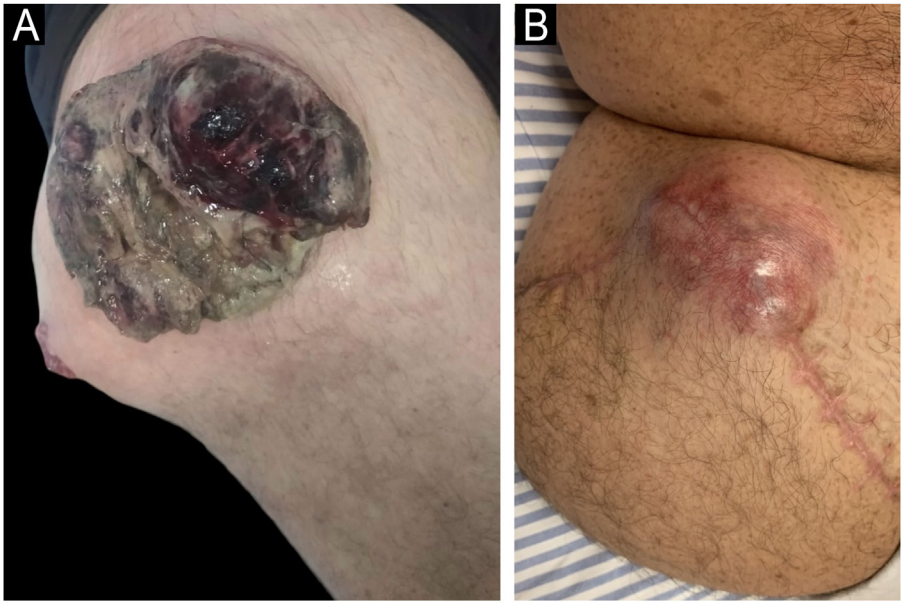

Figure 1 Tumor mass respectively: (A) on the day of admission and (B) recurrence 68 days after surgery.

☆ Study conducted at the Departments of Dermatology, Oncology and Pathology, Hospital Regional de Presidente Prudente, Universidade do Oeste Paulista, Presidente Prudente, SP, Brazil.

https://doi.org/10.1016/j.abd.2025.501199

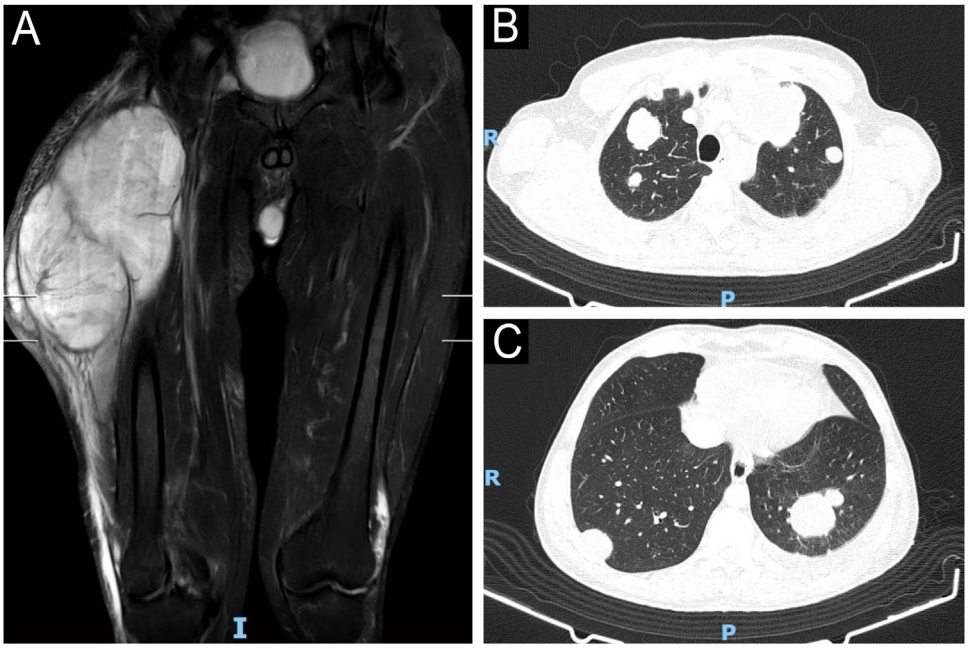

Figure 2 (A) Pre-surgery MRI of the thigh showing an expansile mass in the region of the extensor muscles measuring approximately 23.3 by 12.8 × 13.0 cm, with a volume of approximately 2000 mL, with a heterogeneous liquid content, areas suggestive of hemorrhage, and peripheral contrast uptake. (B and C) Contrast-enhanced chest computed tomography performed 68 days after complete excision of the lesion showed several pulmonary nodules with a neoplastic appearance.

Patient was hospitalized for diagnostic elucidation, chest and abdominal CT scans were performed, which were normal. MRI of the right thigh demonstrated a large, septate, heterogeneous expansile mass located in the region of the extensor muscles with peripheral contrast enhancement (Fig. 2).

Right rip disarticulation and inguinal lymphadenectomy were performed uneventfully. The pathology and IHC results (Fig. 3) were consistent with poorly differentiated sarcoma, with a spindle cell pattern, high cellularity, moderate atypia, fibrillar and edematous stroma, a mitotic index of 8 per 2 mm, diffusely positive CD34, diffusely positive monoclonal H3K27me3, Sox10-, S100-, Desmin-, and Myogenin-, suggesting a possible diagnosis of MPNST, especially if there are clinical signs of NF1-type genetic comorbidity.

The patient returned with regrowth of the tumor lesion 68 days after surgery (Fig. 1). Upon re-admission, he was evaluated by the Dermatology team, and revealed multiple café-au-lait macules, multiple cutaneous neurofibromas, axillary freckles, and Lisch nodules in both irises. Diagnosis was confirmed by the National Institutes of Health criteria for NF1 (Fig. 4), which, together with the anatomopathological pattern and IHC, confirmed the diagnosis of MPNST.[3] New staging exams were performed, which demonstrated recurrence of the local tumor associated with iliac lymph node involvement and pulmonary metastasis, recurrent stage IV T4 N1 M1 (Fig. 2). Palliative chemotherapy with ifosfamide and doxorubicin was initiated; the patient remains under multidisciplinary follow-up.

The diagnosis of MPNST remains a challenge, given its clinical behavior similar to that of other sarcomas. Anatomopathological examination is nonspecific and aims to exclude other tumor diagnoses, with heterogeneous microscopy findings of a high mitotic index, nuclear atypia, necrosis, and hemorrhage being common. On IHC, S-100 is positive in 50%–60% of cases; however, its negative expression indicates a higher mortality and risk of metastasis[4,5]; SOX10 is present in 70% of cases; however, when the expression is negative, it also impacts a worse prognosis[6]; CD34 is weakly positive in high-grade sarcomas[7]; complete loss of H3K27me3 expression occurs in 30%–90%, with positivity being more common in those related to NF1.[8] Negative expression of desmin and myogenin is important for the diagnostic exclusion of ''Triton''-type MPNST and rhabdomyosarcoma.[9]

No defining markers for the disease have yet been discovered. The above case was a major challenge due to the late discovery of NF1, which was only made after tumor recurrence.

When compared with other reports in the literature, this case stands out on IHC, presenting an atypical set of findings, previously outside the patterns reported in MPNST related to NF1.[10] Negative for S100 and SOX10, weakly positive CD34, and positive H3K27me3 are extremely rare and, as previously mentioned, indicative of a worse prognosis, which may explain the extremely aggressive behavior of the reported MPNST, which recurred with metastatic lesions 68 days after surgery. The survival rate for neurofibromatosis-related MPNST is estimated at 21% over the next five years,[2]

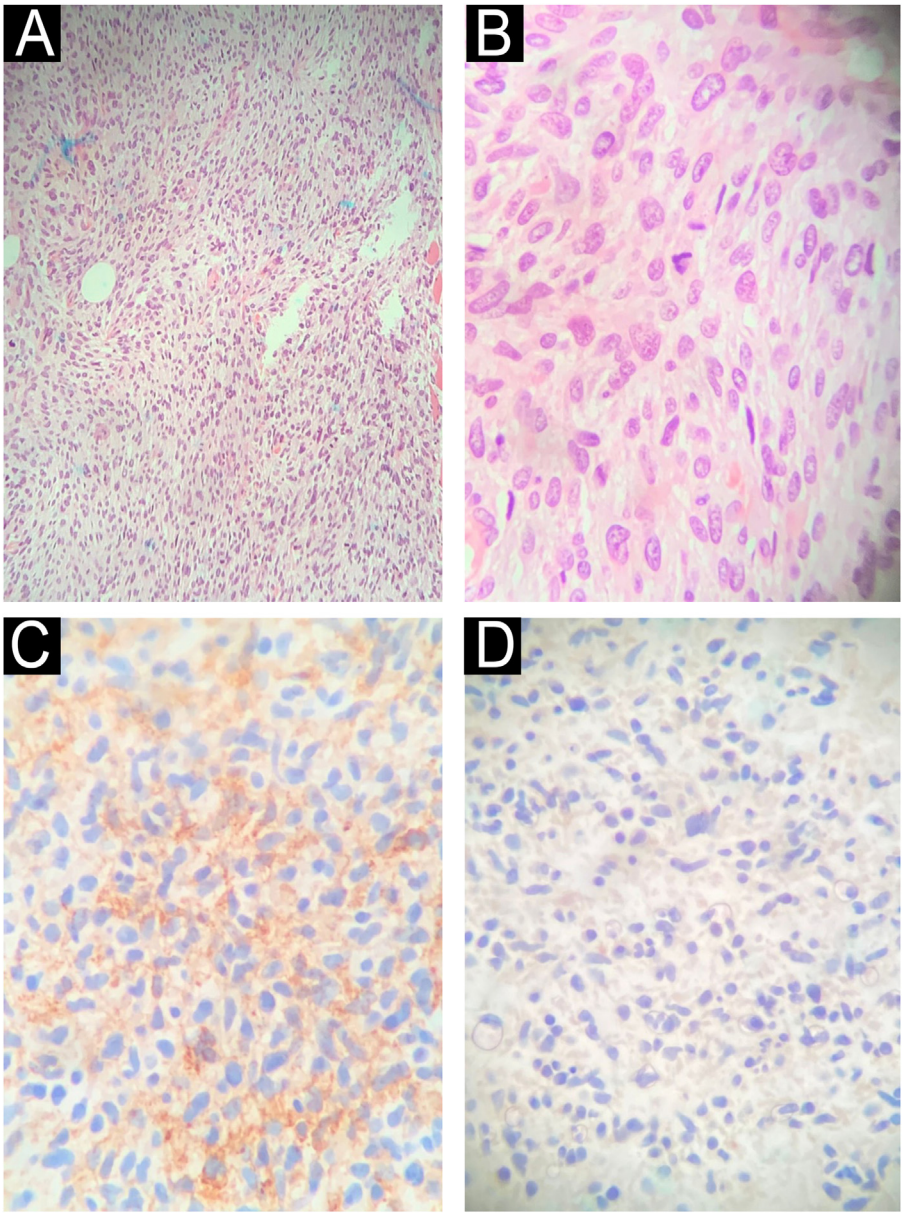

Figure 3 (A and B) Excisional fragment of a right hip disarticulation product stained with hematoxylin and eosin, ×100 and ×400, respectively, demonstrating proliferation of spindle cells with high cellularity, mitotic index of 8 per 2 mm^2, moderate atypia, forming fascicles with variable, narrow elongations, in fibrillar and edematous stroma. (C) Immunohistochemistry of the specimen weakly positive for CD34. (D) Immunohistochemistry of the specimen negative for S100.

possibly lower in this metastatic patient with an atypical and even more aggressive IHC pattern.

The rarity of this case, as well as its diagnostic difficulty and severity, demonstrates the importance of such reports, so that the disease becomes more widely known among healthcare professionals, especially dermatologists who conduct ongoing follow-up of patients with NF1, those primarily affected by the tumor.

Figure 4 Presence of multiple superficial cutaneous neurofibromas, axillary freckles and multiple café-au-lait spots.

Research data availability

Does not apply.

Editor

Hiram Larangeira de Almeida Jr.

Financial support

None declared.

Authors' contributions

Luis Regagnan Dias: Collection of data; analysis of data; critical review of the literature; drafting and editing of the manuscript.

Beatriz Zimermano Coimbra: Collection, analysis, and interpretation of data.

Marcelo Tiezzi: Critical review of the literature; intellectual participation in the introductory process.

Mayndra Mychelle Landgraf: Critical review of the literature; intellectual participation in the introductory process.

Marilda Aparecida Milanez Morgado de Abreu: Design and planning of the study; effective participation in research orientation; intellectual participation in the introductory process; approval of the final version of the manuscript.

Conflicts of interest

None declared.

References

1. Stucky CCH, Johnson KN, Gray RJ, Pockaj BA, Ocal IT, Rose PS, et al. Malignant peripheral nerve sheath tumors (MPNST): the Mayo Clinic experience. Ann Surg Oncol. 2012;19:878–85.
2. Jesus DC, Formigo A, Florova E, Fernandes C, Fontes L, Vieira MJM, et al. Tumor maligno da bainha do nervo periférico: relato de caso. Rev Soc Bras Clin Méd. 2012;10:67–72.
3. Ferner R, Huson S, Thomas N, Moss C, Willshaw H, Evans D, et al. Guidelines for the diagnosis and management of individuals with neurofibromatosis 1. J Med Genet. 2007;44:81–8.
4. Gonzalez-Martinez T, Perez-Piñera P, Díaz-Esnal B, Vega JA. S-100 proteins in the human peripheral nervous system. Microsc Res Tech. 2003;60:633–8.
5. Zou C, Smith KD, Liu J, Lahat G, Myers S, Wang WL, et al. Clinical, pathological, and molecular variables predictive of malignant peripheral nerve sheath tumor outcome. Ann Surg. 2009;249:1014–22.
6. Ito Y, Kohashi K, Endo M, Yoshimoto M, Ishihara S, Toda Y, et al. Clinicopathological and prognostic significance of H3K27 methylation status in malignant peripheral nerve sheath tumor: correlation with skeletal muscle differentiation. Virchows Archiv. 2021;479:1233–44.
7. Weiss SW, Nickoloff BJ. CD-34 is expressed by a distinctive cell population in peripheral nerve, nerve sheath tumors, and related lesions. Am J Surg Pathol. 1993;17:1039–45.
8. Cleven AH, Sannaa GA, Briaire-de Bruijn I, Ingram DR, van de Rijn M, Rubin BP, et al. Loss of H3K27 tri-methylation is a diagnostic marker for malignant peripheral nerve sheath tumors and an indicator for an inferior survival. Mod Pathol. 2016;29:582–90.
9. Hornick JL, Nielsen GP. Beyond ''Triton'': Malignant peripheral nerve sheath tumors with complete heterologous rhabdomyoblastic differentiation mimicking spindle cell rhabdomyosarcoma. Am J Surg Pathol. 2019;43:1323–30.
10. Lucas CHG, Vasudevan HN, Chen WC, Magill ST, Braunstein SE, Jacques L, et al. Histopathologic findings in malignant peripheral nerve sheath tumor predict response to radiotherapy and overall survival. Neuro-Oncol Adv. 2020;2:vdaa131.

Luis Regagnan Dias [a], Beatriz Zimermano Coimbra [a,b], Marcelo Tiezzi [c], Mayndra Mychelle Landgraf [d], Marilda Aparecida Milanez Morgado de Abreu [a,b,*]

[a] *Department of Dermatology, Hospital Regional de Presidente Prudente, Presidente Prudente, SP, Brazil*
[b] *Stricto Sensu Postgraduate Program in Health Sciences, Universidade do Oeste Paulista, Presidente Prudente, SP, Brazil*
[c] *Department of Pathology, Hospital Regional de Presidente Prudente, Presidente Prudente, SP, Brazil*
[d] *Department of Oncology, Hospital Regional de Presidente Prudente, Presidente Prudente, SP, Brazil*

[*] Corresponding author.
E-mail: marilda@morgadoeabreu.com.br (M.A. Abreu).

Received 29 January 2025; accepted 30 March 2025
Available online 22 August 2025

SOCIEDADE BRASILEIRA DE DERMATOLOGIA

Anais Brasileiros de Dermatologia

www.anaisdedermatologia.org.br

LETTER - CLINICAL

Refractory myelodysplasia cutis in a patient with progression to acute myeloid leukaemia☆

Dear Editor,

In 1964, Dr Robert D Sweet reported eight patients with acute febrile neutrophilic dermatosis, later named Sweet Syndrome (SS). Histopathologically, the lesions were characterized by a dermal inflammatory infiltrate rich in neutrophils.[1] Subsequently, it was observed that up to 20% of patients with SS were associated with malignancy, especially hematological malignancies and specifically of myeloid lineage (acute myeloid leukaemia and Myelodysplastic Dyndrome [MDS]).[2] In 2005, Requena et al. first reported that some cases of SS did not have neutrophils with normal reactive characteristics but were immature. These mononuclear cells looked more like histiocytes and immunohistochemically expressed Myeloperoxidase (MPO), CD33, CD163, CD68, an immunophenotype consistent with myeloid precursors, and myelomonocytic cells. This histological variant of SS was termed Histiocytoid Sweet Syndrome (HSS) and was subsequently shown to be more common in SS associated with hematological processes than in idiopathic or reactive SS.[3] More recent findings in the last decade have attempted to further investigate neutrophilic dermatoses associated with MDS. Based on the studies of the group of Vignon-Pennamen et al., the term Myelodysplasia Cutis (MC) has been proposed to refer to myeloid dermatoses in the spectrum between SS and leukemia cutis in patients with MDS. Specifically, the precise definition of MC would represent patients with MDS, lesions compatible with SS, with a dermal infiltrate composed of immature, non-blastogenic myeloid cells, and their clonality is exactly the same as that associated with myelodysplastic cells in the bone marrow. Thus, MC in the skin would be the expression of a clonal process in the bone marrow, with identical mutations to the bone marrow.[4] This concept would explain why MC is generally corticosteroid dependent, with usually increasing doses (unlike common SS, which generally responds well to corticosteroids). In fact, the most effective treatments reported for MC are those commonly used for MDS, such as demethylating agents (especially azacitidine and decitabine) and, ultimately and as a curative treatment, allogeneic Hematopoietic Stem Cell Transplantation (allo-HSCT).[4,5]

We present a 68-year-old male patient with a history of high-risk MDS (mutations in DMT3A, EZH2 and TP53) who was recently diagnosed and treated of MC in our dermatology department. This patient initially presented (Fig. 1) with lesions compatible (and histologically confirmed) with panniculitis, specifically neutrophilic lobular panniculitis. After an initial response to prednisone, when the dose was reduced to <10 mg/day, the patient continued to develop new nodules and ulcers resembling pyoderma gangrenosum, especially in areas of trauma (canals, biopsies, etc.) (Fig. 2), demonstrating a prominent pathergy phenomenon. In view of these lesions, a diagnosis of MC was proposed and treatment with weekly subcutaneous azacitidine 75 mg/m^2 was started in collaboration with the hematology department. Histopathological findings (Fig. 3) revealed that the dermal infiltrate was rich in cells of histiocytic habitus, and immunohistochemistry showed that the cells combined myeloid and monocytic immunophenotypes, with expression of both MPO and CD163 and negativity for CD3, PAX5, CD79a, CD34, CD43, CD56 or CD117. No histopathological or immunohistochemical findings compatible with leukemia cutis were found in the samples examined, which was also inconsistent with the response to corticosteroids. Genetic testing of skin and bone marrow for the UBA1 gene was requested and the diagnosis of VEXAS (Vacuoles, E1 enzyme, X-linked, Autoinflammatory, Somatic) syndrome was excluded. These findings and the patient's evolution confirmed the diagnosis of MC. Despite an initial response to azacitidine, the patient continued to develop new lesions. In an attempt to reduce these neutrophilic lesions, treatment with cyclosporine and anakinra was started successively on a compassionate basis, both without response. Due to the patient's age and comorbidities, allo-HSCT was declined. Three months after diagnosis, the patient progressed systemically to acute myeloid leukemia and died of the disease despite multiple cycles of chemotherapy.

The purpose of this article is to draw the attention of the scientific community to the existence of MC. Par-

☆ Study conducted at the Department of Dermatology, Hospital Universitario y Politécnico La Fe, Comunidad Valenciana, Valencia, Spain.

https://doi.org/10.1016/j.abd.2025.501185

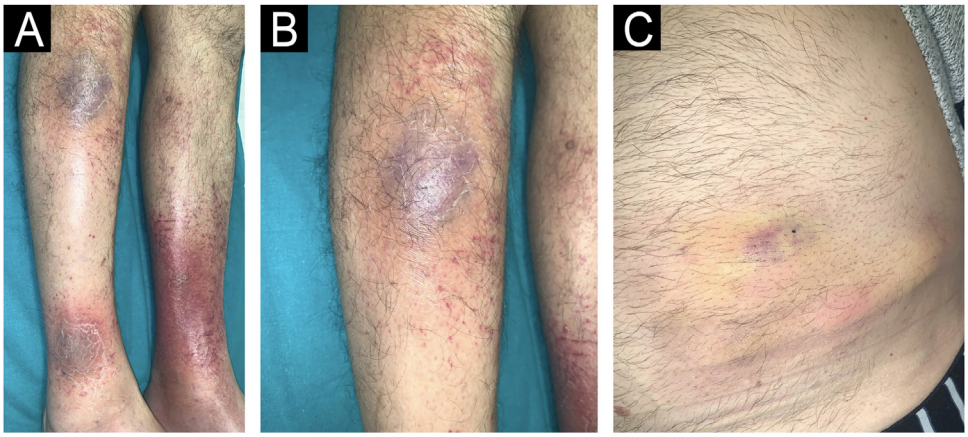

Fig. 1 Clinical appearance of the initial skin lesions.
Subcutaneous nodules on both lower limbs and left hemiabdomen (in the area of heparin administration, demonstrating a phenomenon of pathergy). Histopathology of the leg lesions showed neutrophilic lobular panniculitis.

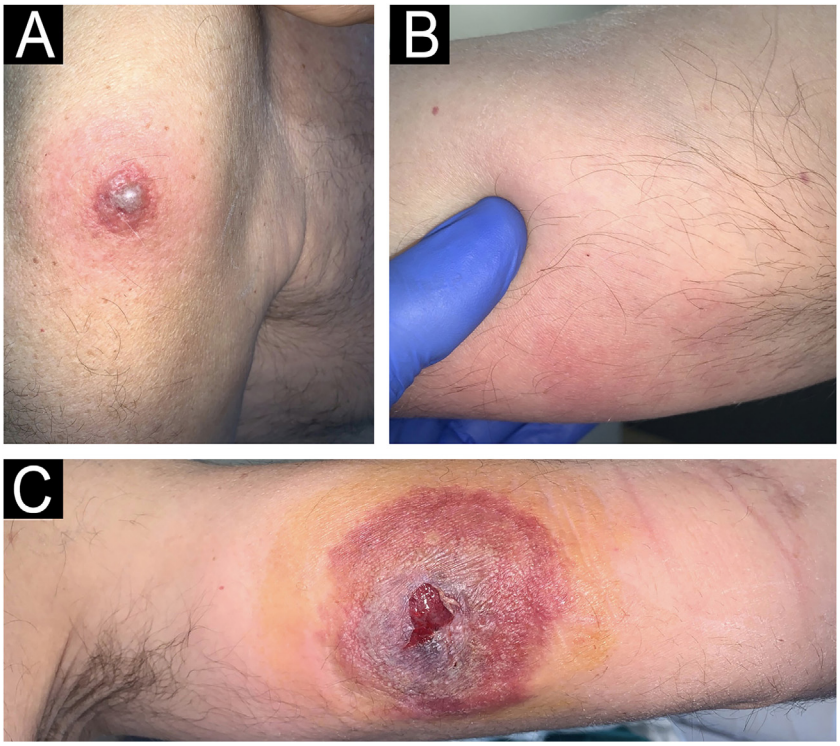

Fig. 2 New skin lesions secondary to pathergy.
(A) Erythematous violaceous plaque on the left shoulder around vaccine application. (B) Subcutaneous nodule on the medial aspect of the right arm in the area of support. (C) Ulcer resembling pyoderma gangrenosum on the inner side of the left arm in the peripheral route. Histopathology of the left shoulder lesion showed histiocytoid sweet syndrome.

ticularly striking in MC is the marked phenomenon of pathergy (hence the need to avoid invasive procedures), the frequent corticodependence (its treatment is that of MDS and not, as usual, that of neutrophilic dermatoses), and the need to rule out the presence of VEXAS syndrome, given its known and reported association. This is a recently described autoinflammatory disorder caused by somatic mutations in the UBA1 gene. It is characterized by systemic inflammation, skin lesions (characteristically erythematous oedematous plaques with the appearance of neutrophilic dermatoses), and hematological abnormalities. VEXAS is strongly associated with MDS, with many patients presenting with cytopenia's and dysplastic bone marrow changes, linking the inflammatory and hematological components through defective ubiquitination and protein homeostasis.[4,5]

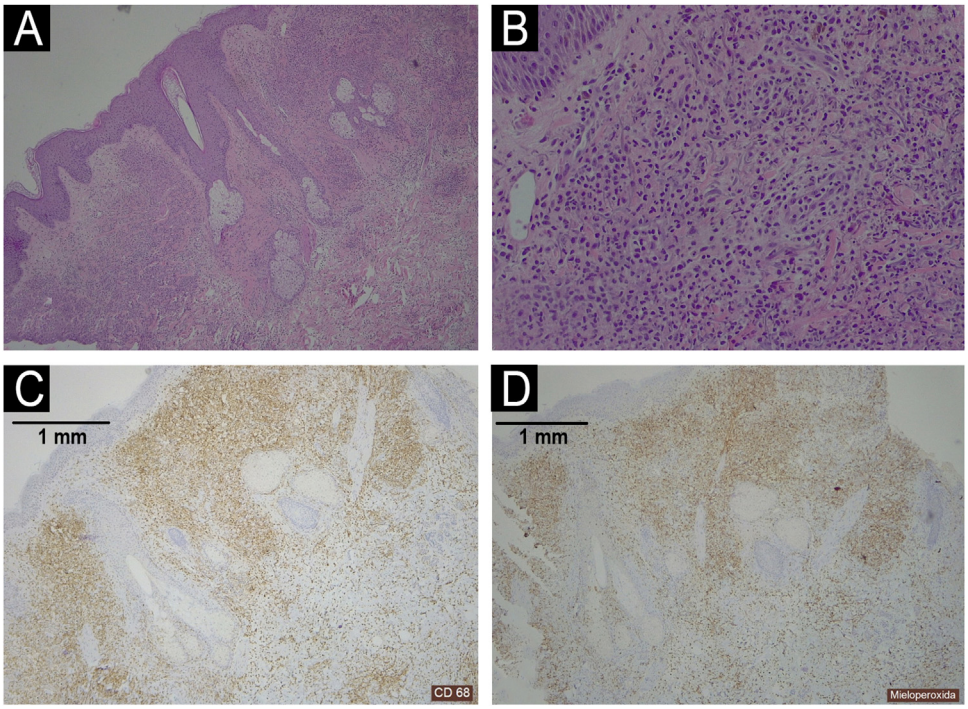

Fig. 3 Histopathology of a shoulder lesion (panel A Haematoxylin-Eosin 40×; panel B Haematoxylin-Eosin 200×; panel C CD68 40×; panel D MPO 40×).
A dermal infiltrate was rich in atypical cells of histiocytic habitus, arranged in clusters and infiltrating collagen bundles (panel A–B). Immunohistochemistry showed that the cells combined myeloid and monocytic immunophenotypes, with expression of both CD68 (panel C) and MPO (panel D). Lymphoid markers (CD3, CD79a, CD63 and PAX5) were negative. CD34, CD56, CD117 and CD138 were also negative.

Authors' contributions

Miguel Mansilla-Polo: Managed clinical treatment and procedures, and wrote the initial version of the article.

Daniel Martín-Torregrosa: Supervised the work.

Research data availability

Does not apply.

Editor

Hiram Larangeira de Almeida Jr.

Financial support

No specific funding was received from any bodies in the public, commercial, or not-for-profit sectors to carry out the work described in this article.

Conflicts of interest

None declared.

References

1. Sweet RD. An acute febrile neutrophilic dermatosis. Br J Dermatol. 1964;76:349–56.
2. Zheng S, Li S, Tang S, Pan Y, Ding Y, Qiao J, et al. Insights into the characteristics of sweet syndrome in patients with and without hematologic malignancy. Front Med (Lausanne). 2020;7:20.
3. Requena L, Kutzner H, Palmedo G, Pascual M, Fernández-Herrera J, Fraga J, et al. Histiocytoid sweet syndrome: a dermal infiltration of immature neutrophilic granulocytes. Arch Dermatol. 2005;141:834–42.
4. Vignon-Pennamen MD, Battistella M. From histiocytoid sweet syndrome to Myelodysplasia Cutis: history and perspectives. Dermatol Clin. 2024;42:209–17.
5. Whittington CP, Ross CW, Ramirez JA, Lowe L, Brown N, Hristov AC. Myelodysplasia Cutis. Arch Pathol Lab Med. 2024;148:385–9.

Miguel Mansilla-Polo [a,b,*], Daniel Martín-Torregrosa [a,b]
[a] *Department of Dermatology, Hospital Universitario y Politécnico La Fe, Comunidad Valenciana, Valencia, Spain*
[b] *Department of Dermatology, Instituto de Investigación Sanitaria (IIS) La Fe, Comunidad Valenciana, Valencia, Spain*

[*] Corresponding author.
E-mail: miguel_yecla96@hotmail.com (M. Mansilla-Polo).

Received 29 December 2024; accepted 26 February 2025
Available online 13 August 2025

SOCIEDADE BRASILEIRA DE DERMATOLOGIA

Anais Brasileiros de Dermatologia

www.anaisdedermatologia.org.br

LETTER - DERMATOPATHOLOGY

Double invasion: an unprecedented case of metastases from two distinct primary sites coexisting in a single cutaneous lesion☆

Dear Editor,

This case reports a unique presentation, in which a single cutaneous tumor was formed by metastases from two independent neoplasms from different sites. The patient was an 80-year-old man with two tumor lesions on the scalp, with a three-month duration (Fig. 1). He had a history of smoking and renal clear cell carcinoma, diagnosed 16 months earlier, treated with radical nephrectomy and retroperitoneal lymphadenectomy with no evidence of lymph node metastasis. He reported significant weight loss but denied other systemic symptoms.

The lesions were surgically excised *en bloc*, with closure using a full-thickness skin graft. Histopathological examination revealed two dermal lesions with cells with clear cytoplasm, pleomorphic nuclei, prominent vasculature, and geographic necrosis. Immunohistochemistry for CD10 and PAX-8 confirmed metastatic renal clear cell carcinoma (RCC). Beneath the largest lesion, there was a dermal proliferation of atypical cells forming glandular structures, with pleomorphism, mitotic activity, and intraluminal necrosis. Immunohistochemical staining was positive for CK20, CDX2, and SATB2, consistent with metastatic colorectal adenocarcinoma (Figs. 2 and 3).

Colonoscopy revealed an infiltrative lesion in the distal rectum, confirmed by biopsy as colorectal adenocarcinoma. CT staging revealed lung and liver metastases. One month after surgery, despite clear margins, three new metastatic implants appeared at the edge of the graft (Fig. 4). The patient was referred to oncology for palliative treatment.

Cutaneous metastases generally appear after the diagnosis of the primary tumor, but in up to one-third of cases, they can be the first manifestation of cancer. In 79% of patients, they are associated with concomitant visceral metastases.[1] The incidence of cutaneous metastases ranges from 0.7% to 9% of patients with malignancies. The most common tumors vary between the sexes: in men, lung (24%–28.6%), gastrointestinal tract (14.2%–19%), melanoma (13%–18.2%), and head and neck squamous cell carcinoma (9.1%–12%); in women, breast (69%), colorectal (9%), melanoma (5%), and ovarian cancer (4%).[2]

Renal cell carcinoma represents 2%–3% of solid neoplasms in adults, with the skin being the third most common site of metastasis, after lymph nodes and lung (6%–11%).[3] Clinically, it presents as reddish or purplish, pulsatile nodules located on the extremities, face, scalp, or scars, and may simulate angiomas and pyogenic granulomas.[3,4] Immunohistochemically, it is positive for PAX8, keratin, EMA, RCC-Ma, CD10, vimentin, and S100, and negative for CK7, CK20, inhibin, Melan-A, calretinin, and TTF-1.[2,5]

Colorectal adenocarcinoma is the gastrointestinal tumor most prone to cutaneous metastases (4% of cases).[6] They generally arise after the diagnosis of the primary tumor, manifesting as nodules in the abdomen, pelvis, or umbilical region, including the classic Sister Mary Joseph nodule.[5,7] More rarely, they occur on the face or in scars. Immunohistochemically, they are positive for SATB2, CK20, CDX2, mucin, and CEA, and negative for CK7.[2,8]

The coexistence of metastases from two distinct primary sites in a single skin lesion, as observed in this case, can be explained by metastatic progression models. According to the clonal expansion and rare variant hypotheses, genetic and epigenetic alterations confer selective advantages to tumor cells, enabling angiogenesis, immune evasion, and tissue invasion. These advantages depend on the interaction between tumor cells and tissue microenvironment, mediated by molecules such as integrins, angiogenic growth factors, and cell adhesion proteins.[2]

In this case, the scalp, being a highly vascularized region, may have offered a favorable environment for tumor development. Furthermore, the initial renal cell carcinoma metastasis may have caused local changes, such as vascular stasis, creating a favorable microenvironment that facilitated the subsequent implantation of metastatic colorectal adenocarcinoma cells.

Alternatively, the simultaneous presence of both neoplasms may be the result of a contingency process, in which immunosenescence and microenvironmental alter-

☆ Study conducted at the Hospital Universitário Professor Polydoro Ernani de São Thiago, Universidade Federal de Santa Catarina, Florianópolis, SC, Brazil.

https://doi.org/10.1016/j.abd.2025.501195

Fig. 1 Scalp tumor lesions: Both were well-adhered, firm, friable, and painless. The larger lesion was formed by contiguous metastases of renal cell carcinoma and intestinal adenocarcinoma; the smaller lesion was formed solely by renal cell carcinoma cells.

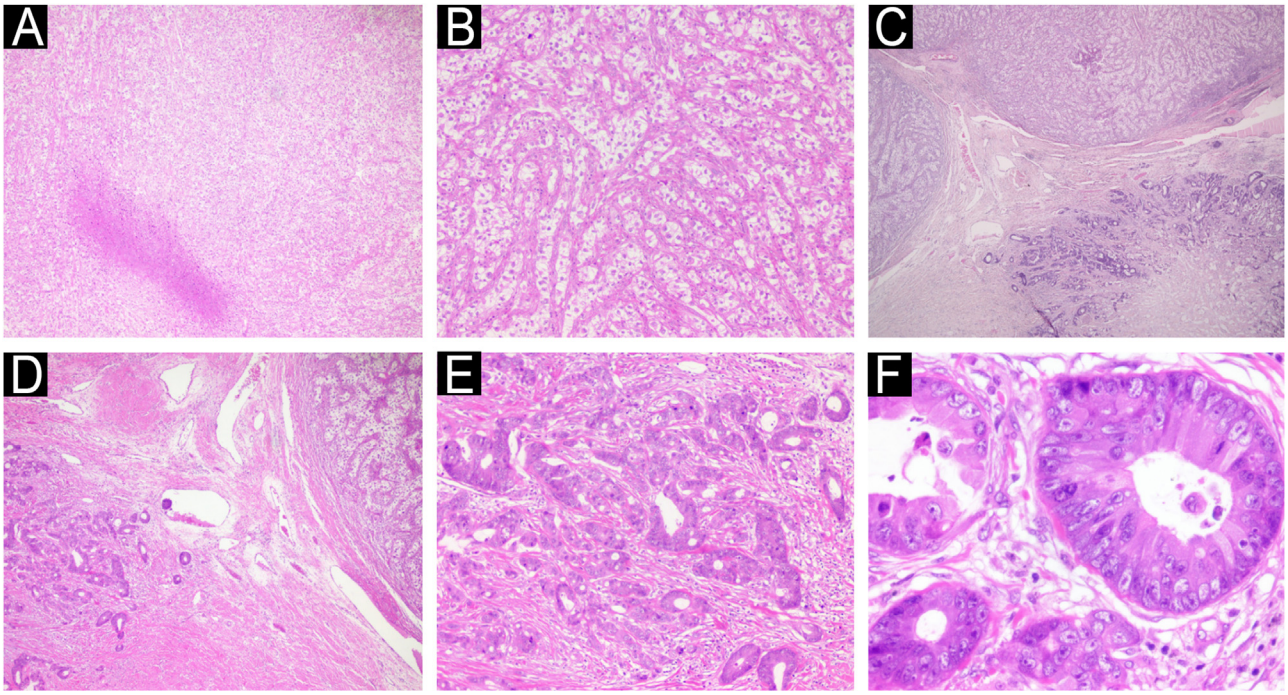

Fig. 2 Histopathology of the largest lesion on the scalp. (A) Neoplasm formed by clear cells with an area of geographic necrosis. (B) Clear cells with pleomorphic nuclei permeated by prominent vascularization. (C) Under the clear cell carcinoma, neoplasm with a tubular pattern. (D) Area of angiolymphatic embolization between the two neoplasms. (E–F) Adenocarcinoma with nuclear pleomorphism and atypical mitotic activity.

ations favor the independent but concomitant occurrence of these metastases.

This case highlights the importance of a detailed diagnostic evaluation by a dermatopathologist, with a comprehensive examination of the excised lesions to identify distinct cell patterns and guide the immunohistochemical investigation. Future studies are needed to expand our understanding of the mechanisms of interaction between

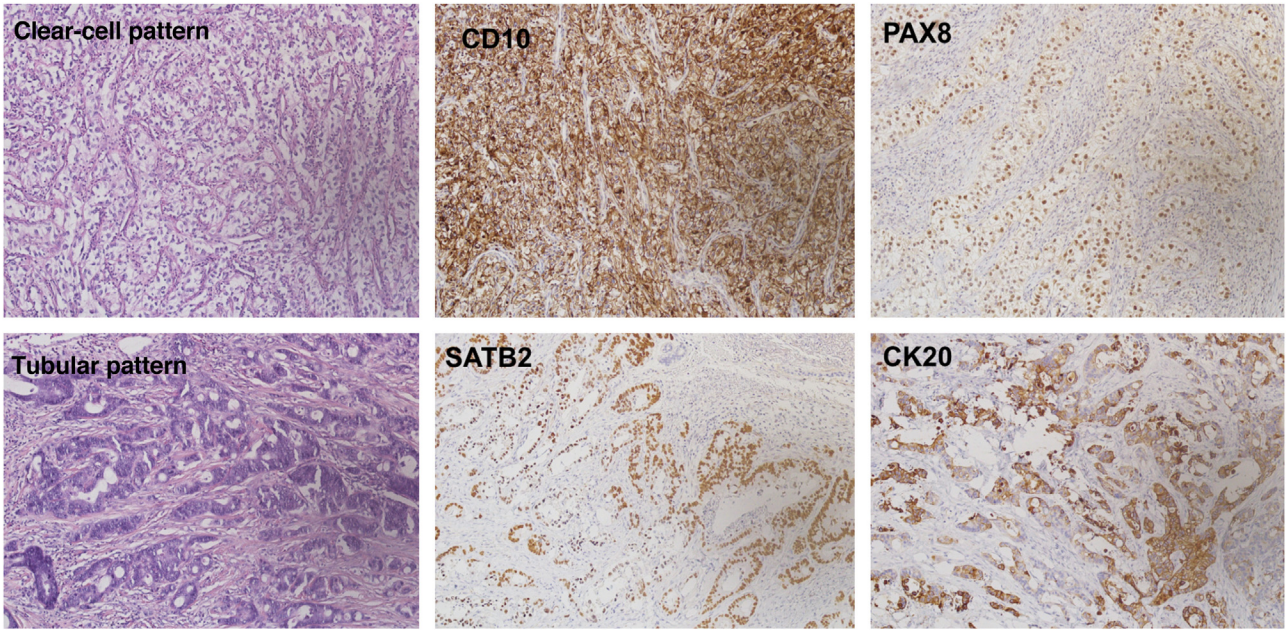

Fig. 3 Different immunohistochemical expression profile between the two neoplasms, with positivity for CD10 and PAX8 in the clear cell carcinoma, and for SATB2 and CK20 in the adenocarcinoma.

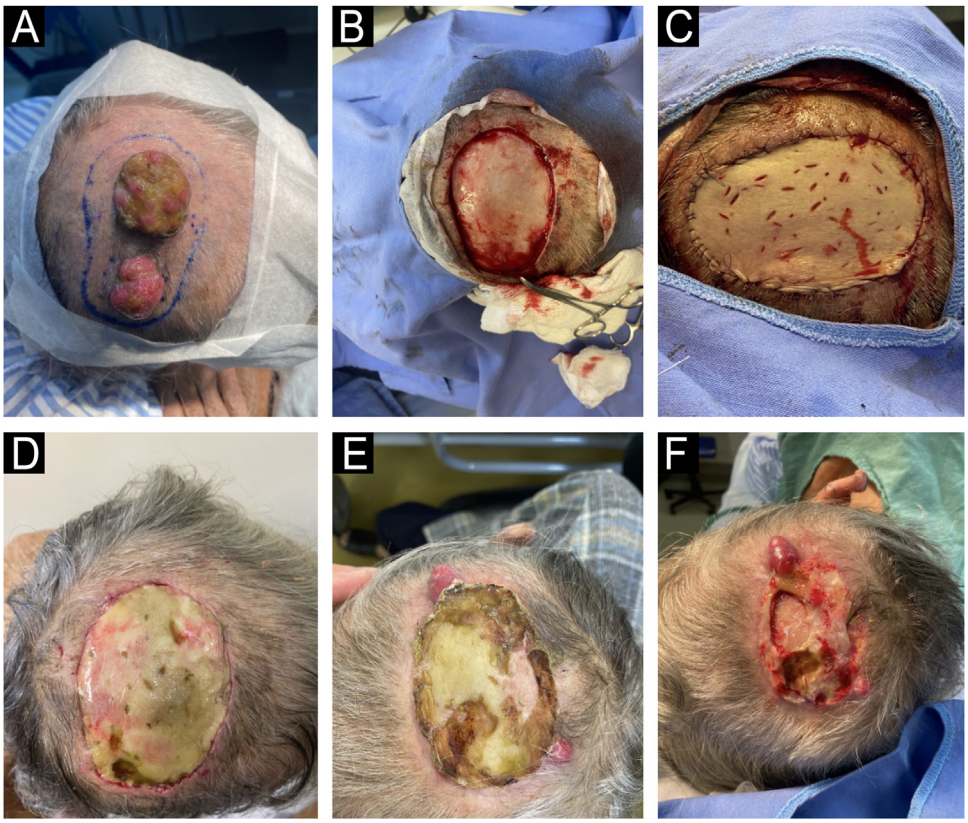

Fig. 4 (A) Preoperative planning of excised lesions. (B) Intraoperative view showing *en bloc* resection of lesions. (C) Immediate postoperative result with wound closure using full-thickness skin graft. (D–F) Late postoperative evolution, showing the emergence of new metastatic implants at the graft edge.

malignant cells and the cutaneous microenvironment, as well as their clinical implications.

Research data availability

Does not apply.

Editor

Ana Maria Roselino.

Financial support

This research did not receive any specific financial support from public, private, or non-profit funding agencies.

Authors' contributions

Matheus Alves Pacheco: Design and planning of the study; drafting and editing of the manuscript or critical review of important intellectual content.

Amanda Amaro Pereira: Design and planning of the study; drafting and editing of the manuscript or critical review of important intellectual content.

Leonardo Simas Abi Saab: Design and planning of the study.

Rúbia Tabata Rigatti: Drafting and editing of the manuscript or critical review of important intellectual content.

Oscar Cardoso Dimatos: Design and planning of the study.

Athos Paulo Santos Martini: Drafting and editing of the manuscript or critical review of important intellectual content.

Conflicts of interest

None declared.

References

1. Souza BC, Miyashiro D, Pincelli MS, Sanches JA. Cutaneous metastases from solid neoplasms × literature review. An Bras Dermatol. 2023;98:571–9.
2. Hussein MR. Skin metastasis: a pathologist's perspective. J Cutan Pathol. 2010;37:e1–20.
3. Mitomi T, Kawahara T, Nomura S, Kuroda S, Takeshima T, Takamoto D, et al. Skin metastasis of renal cell carcinoma. Case Rep Oncol. 2020;13:798–801.
4. Silver E, Roudakova K, Bial N, Daniel D. Cutaneous metastasis of renal cell carcinoma to the cheek: a case report and literature review. Am J Case Rep. 2021;22:e928999.
5. Barr ML, Jilaveanu LB, Camp RL, Adeniran AJ, Kluger HM, Shuch B. PAX-8 expression in renal tumours and distant sites: a useful marker of primary and metastatic renal cell carcinoma? J Clin Pathol. 2015;68:12–7.
6. Bittencourt MJS, Imbiriba AA, Oliveira OA, Santos JEBD. Cutaneous metastasis of colorectal cancer. An Bras Dermatol. 2018;93:884–6.
7. Sittart JA, Senise M. Cutaneous metastasis from internal carcinomas: a review of 45 years. An Bras Dermatol. 2013;88 :541–4.
8. Dragomir A, de Wit M, Johansson C, Uhlen M, Pontén F. The role of SATB2 as a diagnostic marker for tumors of colorectal origin: results of a pathology-based clinical prospective study. Am J Clin Pathol. 2014;141:630–8.

Matheus Alves Pacheco [a,*], Amanda Amaro Pereira [b], Leonardo Simas Abi Saab [c], Rúbia Tabata Rigatti [b], Oscar Cardoso Dimatos [d], Athos Paulo Santos Martini [a]

[a] *Service of Dermatology, Hospital Universitário Professor Polydoro Ernani de São Thiago, Universidade Federal de Santa Catarina, Florianópolis, SC, Brazil*
[b] *Department of Pathology, Hospital Universitário Professor Polydoro Ernani de São Thiago, Universidade Federal de Santa Catarina, Florianópolis, SC, Brazil*
[c] *Dermatological Surgery Outpatient Clinic, Dermatology Service, Hospital Universitário Professor Polydoro Ernani de São Thiago, Universidade Federal de Santa Catarina, Florianópolis, SC, Brazil*
[d] *Bullous Diseases Outpatient Clinic, Dermatology Service, Hospital Universitário Professor Polydoro Ernani de São Thiago, Universidade Federal de Santa Catarina, Florianópolis, SC, Brazil*

* Corresponding author.
E-mail: pacheco.matheus@ebserh.gov.br (M.A. Pacheco).

Received 25 January 2025; accepted 19 March 2025
Available online 18 August 2025

SOCIEDADE BRASILEIRA DE DERMATOLOGIA

Anais Brasileiros de Dermatologia

www.anaisdedermatologia.org.br

LETTER - DERMATOPATHOLOGY

The relevance of clinical-pathological correlation in the diagnosis of cutaneous Rosai-Dorfman disease☆

Dear Editor,

This report describes the case of an 82-year-old woman who sought dermatological evaluation due to two progressively enlarging lesions on her upper back for three months. She reported no symptoms such as fever, sweating, or weight loss. Physical examination revealed two violaceous papular plaques on her upper back, surrounded by similar-looking papules. Dermoscopy revealed a pink background with white structures and telangiectasias (Fig. 1). No adenomegaly was observed on palpation of the main lymph node chains. Complete blood count, biochemical parameters, chest CT scan, and abdominal ultrasound were normal. Histopathological examination revealed a dermal lesion with lymphohistiocytic infiltrate and emperipolesis—i.e., phagocytosis of lymphocytes, plasma cells, and intact red blood cells by histiocytes with ample cytoplasm and conspicuous nucleoli (Fig. 2). Immunohistochemistry was positive in the histiocytes for the markers CD68 (clone PG-M1), Cyclin D1 (clone EP12), and S100 (clone 4C4.9), and negative for CD1a (clone 010) (Fig. 3). Therefore, considering the clinical, laboratory, and histopathological findings together, the diagnosis of cutaneous Rosai-Dorfman Disease (CRDD) was achieved.

CRDD is a rare condition caused by non-Langerhans cells, described as a distinct clinicopathological entity[1] and classified in Group C of histiocytoses.[2] This exclusive skin disease accounts for approximately 3% of all extranodal cases.[3] Although some studies have attempted to establish a relationship between the disease and viral infections and autoimmune diseases, the etiology remains unknown.[1,4,5]

It primarily affects Caucasian and Asian women, with a mean age of 45 years.[1,2,4,5] The clinical presentation can vary between papular lesions, plaques, nodules, and asymptomatic, erythematous-brownish tumors of varying sizes.[1–4]

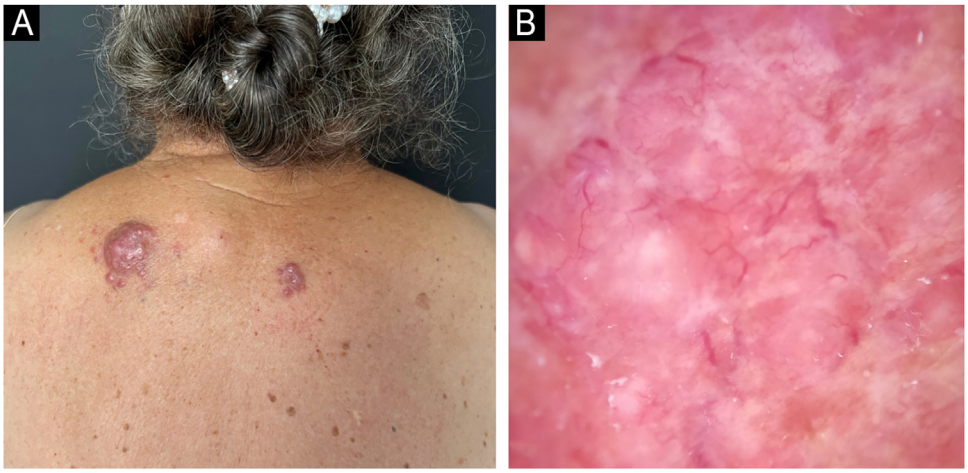

Figure 1 Clinical and dermoscopic photographs of the lesions. (A) Two violaceous papular plaques on the upper back, with surrounding papules of the same color. (B) White structures and telangiectasias with a pink background on dermoscopy.

☆ Study conducted at the Dermatology Outpatient Clinic, Autarquia Municipal de Saúde de Apucarana, Apucarana, PR, Brazil.

https://doi.org/10.1016/j.abd.2025.501180

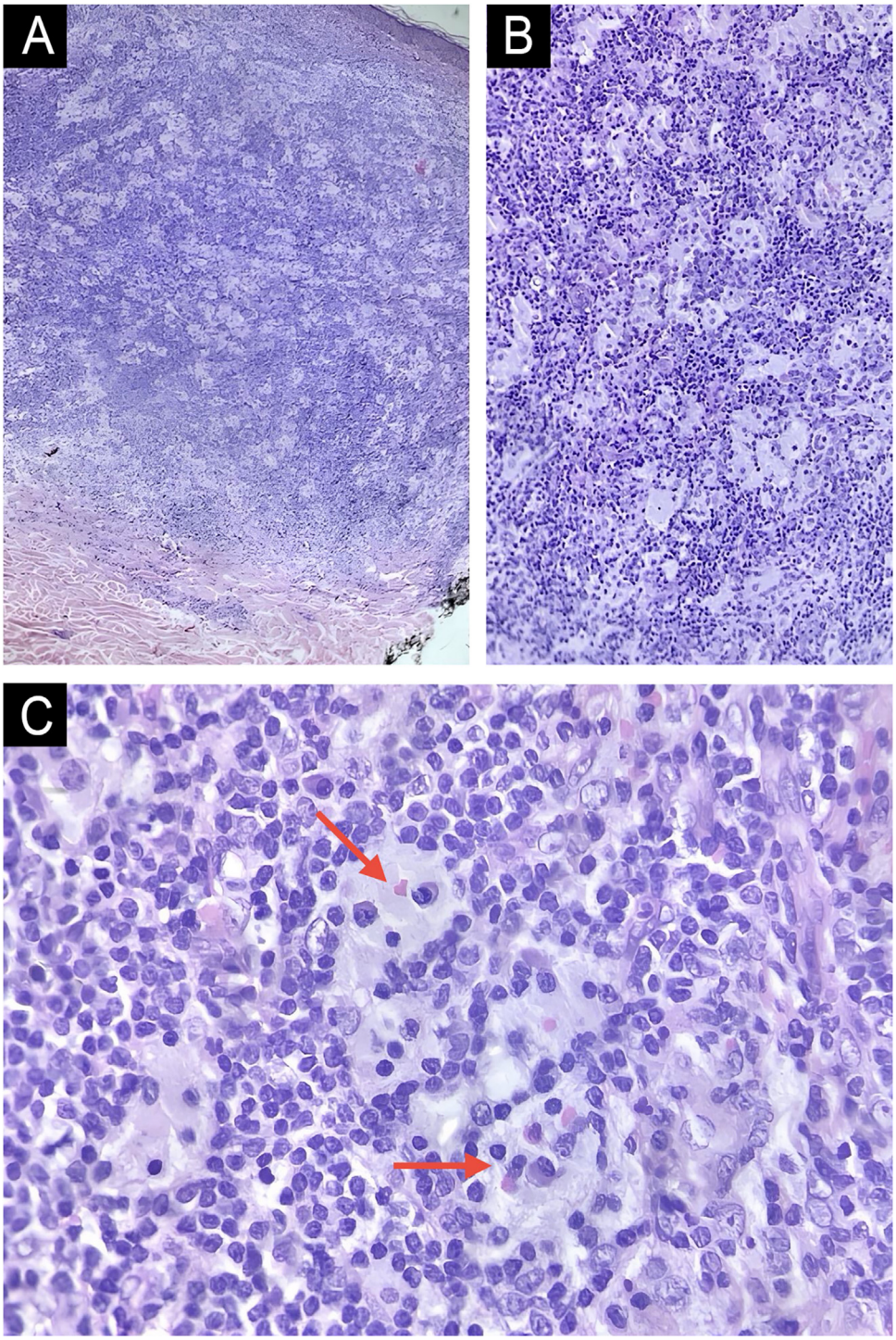

Figure 2 Histopathology of a lesion on the back, stained with Hematoxylin & eosin. (A) Well-defined dermal lymphohistiocytic proliferation without epidermal involvement (Hematoxylin & eosin, ×40). (B) Numerous histiocytes with broad amphophilic cytoplasm interspersed with small lymphocytes (Hematoxylin & eosin, ×100). (C) Presence of emperipolesis demonstrated by the red arrows (Hematoxylin & eosin, ×400).

The most commonly affected sites are the trunk, head, and neck.[1,3]

Histopathology shows dermal lesions and extension into the subcutaneous tissue, with the presence of clusters of histiocytes and emperipolesis, in a mixed inflammatory background with lymphocytes and plasma cells.[4] Immunohistochemistry is of great importance, especially to exclude differential diagnoses such as Langerhans Cell Histiocytosis.[2] The main criteria are positivity for S100 and CD68 and negativity for CD1a in histiocytic cells in CRDD.[4] However, positivity for Cyclin D1 may also be present,[6,7] as seen in the present case.

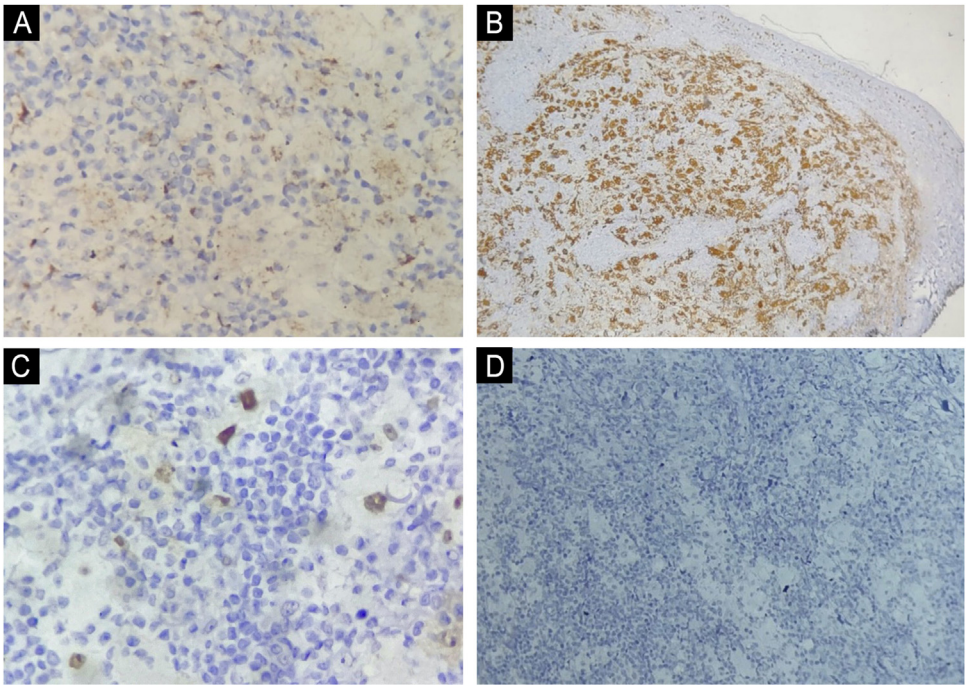

Figure 3 Immunohistochemical analysis. (A) CD68 positive (×40 magnification); (B) S100 positive (×40 magnification); (C) Cyclin D1 positive (×40 magnification); (D) CD1a negative (×10 magnification).

Rosai Dorfman-disease is a benign disease with approximately 50% of cases resolving spontaneously.[2] When exclusively cutaneous involvement occurs, the prognosis becomes even more favorable, as it has a low risk of systemic involvement.[8] Treatment can include surgical excision, systemic corticosteroids, immunomodulators, chemotherapy, or radiotherapy.[1] The patient in the present case underwent total excision of the lesions and semiannual follow-up, having already completed two years of clinical follow-up with no recurrences, new lesions, or signs of systemic disease.

Financial support

None declared.

Authors' contributions

Carolina Ferreira Baldecerra: Critical review of the literature; drafting and editing of the manuscript; critical review of the manuscript.

Patrícia Imai Zanardi: Critical review of the literature; drafting and editing of the manuscript; critical review of the manuscript.

Rafaella Cristine Zanatta: Critical review of the literature; drafting and editing of the manuscript; critical review of the manuscript.

Silvio César Franco Giovanni Filho: Critical review of the literature; effective participation in research orientation; intellectual participation in the propaedeutic and/or therapeutic conduct of the studied cases; approval of the final version of the manuscript.

Cássio Rafael Moreira: Critical review of the literature; effective participation in research orientation; intellectual participation in the propaedeutic and/or therapeutic conduct of the studied cases; approval of the final version of the manuscript.

Conflicts of interest

None declared.

Research data availability

Does not apply.

Editor

Hiram Larangeira de Almeida Jr.

References

1. Dalia S, Sagatys E, Sokol L, Kubal T. Rosai-Dorfman disease: tumor biology, clinical features, pathology, and treatment. Cancer Control. 2014;21:322–7.
2. Bruce-Brand C, Schneider JW, Schubert P. Rosai-Dorfman disease: an overview. J Clin Pathol. 2020;73:697–705.
3. El-Kamel MF, Abdelaziz AM, Mohammed H. A new presentation of isolated cutaneous Rosai-Dorfman disease: eruptive xanthoma-like lesions. Indian J Dermatol Venereol Leprol. 2020;86:158.
4. Ahmed A, Crowson N, Magro CM. A comprehensive assessment of cutaneous Rosai-Dorfman disease. Ann Diagn Pathol. 2019;40:166–73.

5. Brenn T, Calonje E, Granter SR, Leonard N, Grayson W, Fletcher CD, et al. Cutaneous Rosai-Dorfman disease is a distinct clinical entity. Am J Dermatopathol. 2002;24:385–91.
6. Baraban E, Sadigh S, Rosenbaum J, Arnam John Van, Bogusz AM, Mehr C, et al. Cyclin D1 expression and novel mutational findings in Rosai-Dorfman disease. British journal of haematology. 2019;186:837–44.
7. WHO Classification of Tumours Editorial Board. Haematolymphoid tumours. WHO classification of tumours series, Vol. 11, 5th ed. Lyon (France): International Agency for Research on Cancer; 2024.
8. Landim FM, Rios HO, Costa CO, Feitosa RGF, Rocha Filho FD, Costa AAA. Doença de Rosai-Dorfman cutânea. An Bras Dermatol. 2009;84:275–8.

Carolina Ferreira Baldecerra *, Patrícia Imai Zanardi, Rafaella Cristine Zanatta, Silvio Cesar Franco Giovanni Filho, Cássio Rafael Moreira

Dermatology Outpatient Clinic, Autarquia Municipal de Saúde de Apucarana, Apucarana, PR, Brazil

* Corresponding author.
E-mail: carolbaldecerra1@gmail.com (C.F. Baldecerra).

Received 10 January 2025; accepted 19 March 2025
Available online 13 August 2025

SOCIEDADE BRASILEIRA DE DERMATOLOGIA

Anais Brasileiros de Dermatologia

www.anaisdedermatologia.org.br

LETTER - TROPICAL/INFECTIOUS AND PARASITIC DERMATOLOGY

Phaeohyphomycosis caused by *Cladosporium cladosporioides*: importance of molecular identification in challenging cases☆

Dear Editor,

The genus *Cladosporium* includes dematiaceous fungi that are widely distributed and frequently contaminate the environment, present in plants and soil, although some species, such as *C. cladosporioides*, *C. herbarum*, *C. oxysporum*, and *C. sphaerospermum*, are pathogenic, causing superficial and deep skin infections.[1,2]

The most typical lesions present as nodules, plaques, suppurative ulcers, or crusted, ecthyma-like lesions located in areas of trauma or skin involvement.[3,4] Misdiagnoses are common due to overlapping presentations with bacterial abscesses, eczema, or other fungal infections.[1,4] This case describes a patient with a fungal infection of late etiological diagnosis, an insidious course, and a severe clinical outcome.

A 75-year-old male patient was seen in the emergency room with asthenia and skin ulcers. He reported reddish and painful nodules for eight months, mainly on his limbs, which developed into ulcers, some resolving spontaneously, with worsening over the last twenty days. He had previously been seen in an outpatient clinic, where two biopsies were performed from different sites, with inconclusive anatomopathological findings, and was treated with the hypothesis of a skin and soft tissue infection unresponsive to antibiotic therapy.

He was undergoing regular treatment for hypertension, type 2 diabetes mellitus, hyperthyroidism with goiter, and rheumatoid arthritis. He had been taking leflunomide and methotrexate for six years.

On examination, he was in fair general condition, hypoactive, and had an enlarged anterior cervical region (goiter). He had a skin lesion on his right thigh and left arm (Fig. 1), as well as dozens of painful erythematous-violaceous nodules up to 1 cm in diameter on his limbs.

The patient was admitted for investigation, and a biopsy was performed on a recent lesion, consistent with erythema nodosum, as the previous lesions did not show satisfactory histopathological findings. The examination revealed a perivascular lymphohistiocytic inflammatory infiltrate in the dermis and a lymphocytic infiltrate with septal neutrophils in the hypodermis, with a positive fungal test, suggesting *Histoplasma*.

Itraconazole 800 mg/day was initiated, and after thirty days, a continuous daily dose of 400 mg/day. The patient showed significant improvement in systemic symptoms and was discharged. After twelve months of regular outpatient follow-up, the patient showed complete healing of the ulcers (Fig. 2), a reduction in the number of lesions, but with recurrence of the erythema nodosum inflammation (Fig. 3). Considering a partial response to treatment, it was decided to perform a new biopsy and perform a polymerase chain reaction (PCR) for fungi and genetic sequencing of the material.

The obtained sequence was analyzed in the BLASTn genomic database (GenBank-NCBI; https://blast.ncbi.nlm.nih.gov/Blast.cgi/) with molecular identification of the *Cladosporium cladosporioides* complex. Maximum identity or similarity was 99.7% to 100% (Fig. 4).

After identifying the dematiaceous fungus, it was decided to maintain treatment with itraconazole and perform surgical resections.

While on treatment, after 24 months, the patient still had recurrent lesions. A change to amphotericin B was scheduled, but the patient was lost to follow-up. He returned to the emergency room complaining of cough and intermittent fever for three weeks. He developed severe acute respiratory failure, requiring orotracheal intubation and mechanical ventilation. A chest computed tomography scan revealed signs of atypical pneumonia, although a fungal etiology could not be ruled out. The patient progressed to septic shock and death within a few hours.

In the case described herein, the patient's age, comorbidities, and chronic medication use made him more susceptible to infection. Some cases occur in immunocompetent individuals,[3] but severity depends on the immune status.[5] Severe disease is more common in immunocompro-

☆ Study conducted at the Hospital Universitário, Universidade Federal de São Carlos, São Carlos, São Paulo, Brazil.

https://doi.org/10.1016/j.abd.2025.501196

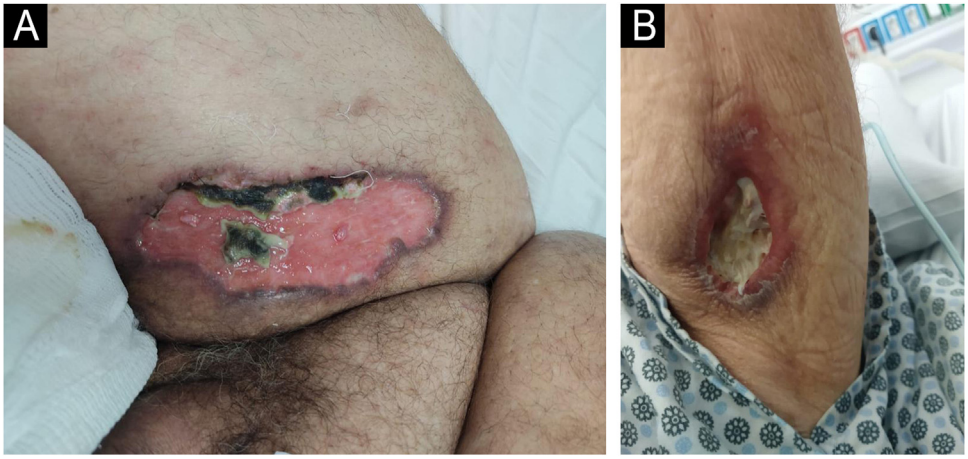

Fig. 1 (A) Shallow ulcer in the right thigh region with necrosis of graft tissue. (B) Ulcer in the proximal lower region of the left arm.

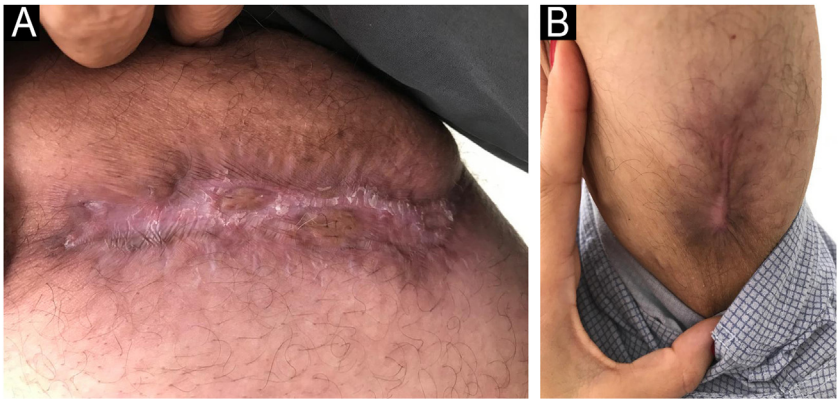

Fig. 2 Ulcer scar on the inner right thigh after 12 months. (B) Ulcer scar on the proximal lower region of the left arm after 12 months.

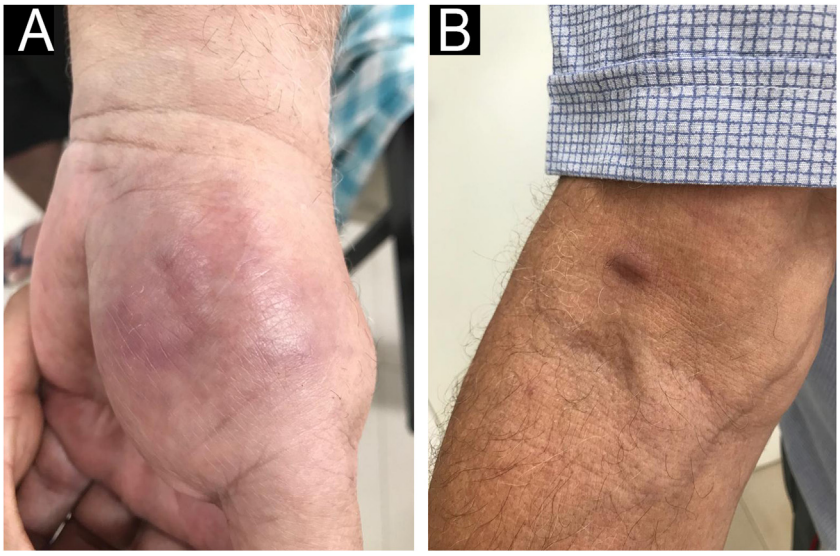

Fig. 3 (A) Erythema nodosum in the palmar region. (B) Erythema nodosum in the cubital fossa region of the right arm.

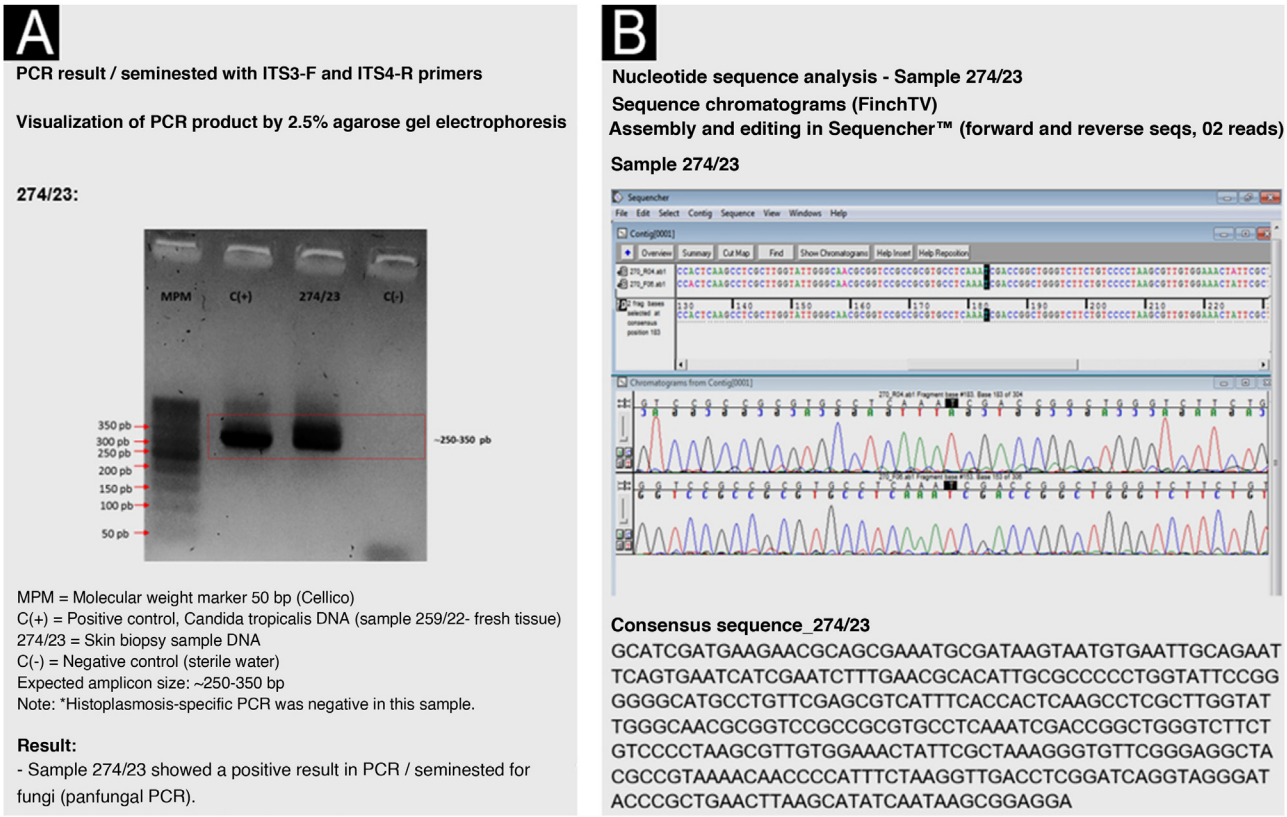

Fig. 4 (A) PCR result for fungi. (B) Analysis of the sample's nucleotide sequences and comparison with the consensus sequence in the database.

mised individuals (e.g., diabetes, steroid use).[6] These fungi invade the skin through previous lesions, produce proteolytic enzymes, and resist phagocytic action, making them highly infectious to the skin, although they can rarely spread to other organs.[2,3]

Itraconazole is the systemic antifungal agent of choice, administered for three to six months, with effective treatment and lesion regression in cases reported in the literature.[2,3,7] Alternative treatments include voriconazole, amphotericin B, and fluconazole, the first two being used/indicated in refractory cases.[3]

The diagnosis was challenging and, as observed in this case, delayed diagnosis can lead to disease progression and unfavorable outcomes, especially with severe systemic manifestations.[4] Molecular identification can differentiate *C. cladosporioides* from other dematiaceous fungi,[8] and is an ally in the resolution of complex and protracted cases. Although still little used, it has potential for growth in dermatology.

Research data availability

Does not apply.

Editor

Sílvio Alencar Marques.

Financial support

None declared.

Authors' contributions

Olivia Silva Zanetti: Approval of the final version of the manuscript; design and planning of the study; drafting and editing of the manuscript; critical review of the literature; critical review of the manuscript.

Maria Paula Barbieri D'Elia: Approval of the final version of the manuscript; design and planning of the study; drafting and editing of the manuscript; critical review of the literature; critical review of the manuscript.

Sigrid de Sousa Dos Santos: Approval of the final version of the manuscript; critical review of the literature; critical review of the manuscript.

Giannina Ricci: Approval of the final version of the manuscript; analysis and interpretation of the anatomopathological examination.

Conflicts of interest

None declared.

References

1. Menezes CP, Pérez ALAL, Lima EO. Cladosporium ssp: Morfologia, infecções e espécies patogênicas. Acta Brasiliensis. 2017;1:23–7.
2. Duquia RP, Almeida HL Jr, Vettorato G, Rocha NM, Castro LAS. Ecthyma-like phaeohyphomycosis caused by Cladosporium cladosporioides. Mycoses. 2010;53:541–3.
3. Vieira MR, Milheiro A, Pacheco FA. Phaeohyphomycosis due to Cladosporium cladosporioides. Med Mycol. 2001;39:135–7.
4. Annessi G, Cimitan A, Zambruno G, Di Silverio A. Cutaneous phaeohyphomycosis due to Cladosporium cladosporioides. Mycoses. 1992;35:243–6.
5. Belvoncikova P, Splichalova P, Videnska P, Gardlik R. The human mycobiome: Colonization, composition and the role in health and disease. J Fungi (Basel). 2022;8:1046.
6. Sandoval-Denis M, Sutton DA, Martin-Vicente A, Cano-Lira JF, Wiederhold N, Guarro J, et al. Cladosporium species recovered from clinical samples in the United States. J Clin Microbiol. 2015;53:2990–3000.
7. Gugnani H, Sood N, Singh B, Makkar R. Case Report. Subcutaneous phaeohyphomycosis due to Cladosporium cladosporioides. Mycoses. 2000;43:85–7.
8. Sang H, Zheng XE, Zhou WQ, He W, Lv GX, Shen YN, et al. A case of subcutaneous phaeohyphomycosis caused by Cladosporium cladosporioides and its treatment. Mycoses. 2012;55:195–7.

Olivia Silva Zanetti [a,*], Maria Paula Barbieri D'Elia [a], Sigrid de Sousa dos Santos [a], Giannina Ricci [b]

[a] *Department of Medicine, Universidade Federal de São Carlos, São Carlos, SP, Brazil*
[b] *Centro de Diagnóstico e Pesquisa em Biologia Molecular Dr. Ivo Ricci, São Carlos, SP, Brazil*

[*] Corresponding author.
E-mail: oliviaszanetti@gmail.com (O.S. Zanetti).

Received 31 January 2025; accepted 14 April 2025
Available online 9 August 2025

SOCIEDADE BRASILEIRA DE DERMATOLOGIA

Anais Brasileiros de Dermatologia

www.anaisdedermatologia.org.br

LETTER - THERAPY

Omalizumab for cholinergic pruritus in a renal transplant and hemodialysis patient☆

Dear Editor,

Cholinergic Pruritus (CholP) is a rare condition characterized by generalized itching, tingling, or burning sensations without any skin lesions, triggered by increased body core temperature, and reversible after cooling. CholP is often resistant to antihistamines H1 (anti-H1), and the choice of medication is even more limited in patients with severe systemic disease. The efficacy and safety of omalizumab in anti-H1-refractory chronic spontaneous urticaria have been widely recognized, and it has also been successfully used in the treatment of Cholinergic Urticaria (CholU),[1,2] but there is little information regarding to this drug for the treatment of patients with concomitant immunosuppression and hemodialysis. Herein, we describe a case of omalizumab use as a treatment for CholP in a renal transplant and hemodialysis patient.

A 45-year-old male presented to our department, with complaints of generalized itching and tingling for more than 2-months. The unpleasant sensation triggered by increased body heat (e.g., hot baths, emotionally charged and taking spicy food) and relieved by cooling. It occurred several times a day and lasted for a few to 10 min each time but without any lesions. He has been taking oral tacrolimus and mycophenolate mofetil for 12-years after renal transplantation and hemodialysis 3 times a week was initiated more than 1-year ago. Since dialysis, he perspired less. Laboratory tests showed normal eosinophils, Immunoglobulin E (IgE), anti-Thyroperoxidase Antibody (anti-TPO Ab), and anti-Thyroglobulin Antibody (anti-Tg Ab). According to the patient's clinical manifestation, CholP, Chronic Kidney Disease-associated Pruritus (CKD-aP) and Acquired Idiopathic Generalized Anhidrosis (AIGA) were considered. However, patients with CKD-aP usually have persistent itching, which is severe at night as compared to daytime. Various factors such as showering, dialysis, heat, pressure, and cold can exacerbate itching, rather than just being induced by increased body core temperature.[3] AIGA is characterized by anhidrosis/hypohidrosis without any apparent causes and is often troubled by tingling dermal pain upon sweating but not itching.[4] Therefore, the final diagnosis is CholP. Considering the physical condition of the patients, we did not perform exercise challenge tests.

Table 1 The clinical scores at baseline and 12–24 weeks after omalizumab treatment.

Time points	Clinical scores		
	itch NRS	UCT	DLQI
Baseline	8	1	12
Week 12	0–1	16	2
Week 24	4	12	6

NRS, Numeric Rating Scale; UCT, Urticaria Control Test; DLQI, Dermatology Life Quality Index.

He was given cetirizine 10 mg qd, which provided partial relief in the first 2 weeks, but the effect gradually declined. Then, loratadine 10 mg daily was prescribed but was discontinued because of palpitation. Omalizumab (300 mg/4 weeks) in combination with cetirizine 10 mg qd was used with overall consideration of his underlying disease and drug accessibility and affordability. At the baseline, he had an itch Numeric Rating Scale (NRS) of 8/10, an Urticaria Control Test (UCT) score of 1/16, and a Dermatology Life Quality Index (DLQI) score of 12/30. Fortunately, the patient reported an obvious resolution after 4 weeks of treatment. He reached complete remission at 12 weeks (itch NRS of 0–1/10, UCT score of 16/16, DLQI score of 2/30). However, at 24 weeks, there was some recurrence of symptoms, but still showed significant improvement from baseline (itch NRS of 4/10, UCT score of 12/16, DLQI score of 6/30). Table 1 shows the clinical scores at different time points. The patient did not report any adverse effects and there was no change in his immunosuppressive drugs and hemodialysis regimen.

CholP is a rare variant of Cholinergic Urticaria (CholU) without any lesions.[5] The main treatment remains anti-H1, but it is usually less effective.[5] Omalizumab, a recombinant humanized monoclonal antibody that inhibits IgE, has

☆ Study conducted at the Sichuan Provincial People's Hospital, School of Medicine, University of Electronic Science and Technology of China, Chengdu, China.

https://doi.org/10.1016/j.abd.2025.501167

been approved for the treatment of chronic spontaneous urticaria. In recent years, there have been few reports of omalizumab for the treatment of CholP,[6,7] and reports in patients with combined renal transplantation and hemodialysis are lacking. Omalizumab has a relatively good safety profile, with rare serious adverse reaction such as anaphylactic shock. Since omalizumab is removed primarily by the reticuloendothelial system, it is less likely to affect renal function.

This CholP patient, with a history of renal transplantation and undergoing hemodialysis, had a good response and tolerance to omalizumab. Omalizumab did not have a notable impact on his renal function and relative medications. This case confirms the efficacy of omalizumab in CholP and seems to support that omalizumab treatment can be practiced in renal transplant and hemodialysis patients without apparent interference with the efficacy and safety of the drug. This may provide some reference for the use of omalizumab in patients with concomitant transplant status and/or hemodialysis. However, a longer follow-up period, as well as larger studies are needed to validate findings.

Editor

Hiram Larangeira de Almeida Jr.

Research data availability

Does not apply.

Financial support

None declared.

Authors' contributions

Qing Shu: Data collection, analysis and interpretation of data; preparation and writing of the manuscript.

Xiang Zhong: Data collection, analysis and interpretation of data; preparation and writing of the manuscript.

Lixia Zhang: Critical review of the literature; approval of the final version of the manuscript.

Qian Wang: Study conception and planning; critical review of the literature; approval of the final version of the manuscript.

Conflicts of interest

None declared.

References

1. Tharp MD, Bernstein JA, Kavati A, Ortiz B, MacDonald K, Denhaerynck K, et al. Benefits and harms of omalizumab treatment in adolescent and adult patients with chronic idiopathic (spontaneous) urticaria: a meta-analysis of ''real-world'' evidence. JAMA Dermatol. 2019;155:29–38.
2. Gastaminza G, Azofra J, Nunez-Cordoba JM, Baeza ML, Echechipía S, Gaig P, et al. Efficacy and safety of omalizumab (xolair) for cholinergic urticaria in patients unresponsive to a double dose of antihistamines: a randomized mixed double-blind and open-label placebo-controlled clinical trial. J Allergy Clin Immunol Pract. 2019;7:1599–609.e1.
3. Agarwal P, Garg V, Karagaiah P, Szepietowski JC, Grabbe S, Goldust M. Chronic kidney disease-associated pruritus. Toxins (Basel). 2021;13:527.
4. Takahagi S, Okamoto M, Ishii K, Tanaka A, Mizuno H, Harada N, et al. Clinical and histological characterization of transient dermal pain triggered by sweating stimuli. Allergol Int. 2022;71:362–72.
5. Kim HJ, Lee MG. Cholinergic urticaria: more than a simple inducible urticaria. Australas J Dermatol. 2017;58:e193–8.
6. Hasan SB, Ali FM, Ingram JR. Cholinergic pruritus responding to omalizumab. Clin Exp Dermatol. 2020;45:264–6.
7. Bréhon A, Hamelin A, Cariou C, Senet P, Sonigo G, De Risi T, et al. Cholinergic pruritus treated with omalizumab: Seven cases. J Eur Acad Dermatol Venereol. 2024;38:e933–5.

Qing Shu [a], Xiang Zhong [b], Lixia Zhang [a,*], Qian Wang [a,*]

[a] *Institute of Dermatology and Venereology, Sichuan Provincial People's Hospital, School of Medicine, University of Electronic Science and Technology of China, Chengdu, China*

[b] *Department of Nephrology and Institute of Nephrology, Sichuan Provincial People's Hospital, School of Medicine, University of Electronic Science and Technology of China, Sichuan Clinical Research Center for Kidney Diseases, Chengdu, China*

* Corresponding authors.
E-mail: zlx007895@163.com (L. Zhang), wqian1111@126.com (Q. Wang).

Received 17 December 2024; accepted 28 January 2025
Available online 4 August 2025

SOCIEDADE BRASILEIRA DE DERMATOLOGIA

Anais Brasileiros de Dermatologia

www.anaisdedermatologia.org.br

LETTER - THERAPY

Paradoxical morphea-like reaction after initiation of dupilumab for nodular prurigo☆

Dear Editor,

Localized morphea, or localized scleroderma, is an autoimmune connective tissue disorder characterized by inflammation and sclerosis of the skin and sometimes deeper tissues. The pathophysiology is not fully understood, likely multifactorial, involving interactions among genetic factors, infections, medications, and immune pathway alterations that promote fibrosis.[1]

A 68-year-old male with a history of epithelioid hemangioma in the proximal right ulna presented with pruritic, excoriated erythematous-violaceous papules and plaques (Fig. 1). Histopathology revealed focal epidermal erosion accompanied by marked epidermal hyperplasia, hypergranulosis, and spongiosis, along with a perivascular and interstitial lymphocytic infiltrate in the superficial dermis; findings consistent with nodular prurigo (Fig. 2). Treatment with dupilumab was initiated with an initial dose of 600 mg, followed by 300 mg administered every two weeks. After six months of treatment, painful skin lesions appeared on the right elbow and trunk. Physical examination revealed an indurated, shiny brownish plaque extending from the mid-arm to the distal third of the forearm on the right upper limb, as well as several oval plaques on both flanks of the trunk (Fig. 3). The patient's blood count was normal, without eosinophilia, and autoimmunity and serology studies showed no abnormalities.

Histopathology of the trunk lesion showed dermal changes, including edema, vascular ectasia, and progressive sclerosis extending into the subcutaneous tissue (Fig. 4). Additionally, a predominantly lymphohistiocytic inflammatory infiltrate was observed, along with perivascular and interstitial involvement. Immunohistochemical staining for CD34 revealed the loss of dermal dendritic cells (Fig. 2).

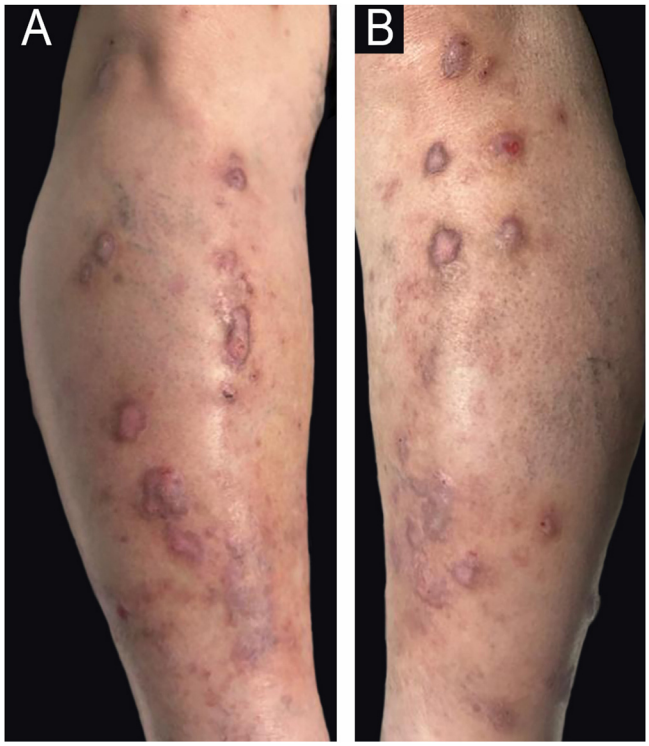

Fig. 1 Excoriated bilateral erythematous-violaceous papules and plaques on the pretibial regions.

Dupilumab was discontinued, and treatment with weekly methotrexate (15 mg), oral prednisone (tapering regimen), and topical clobetasol (once daily) was initiated, resulting in progressive improvement of the lesions.

Morphea is a multifactorial connective tissue disorder. It is thought to involve two stages of pathophysiology: an early inflammatory stage mediated by the Th1 and Th17 axes, followed by a fibrotic stage mediated by the Th2 axis.[1] The Th2 response has been implicated in the development of fibrotic disorders by promoting fibroblast proliferation and collagen production, suggesting that blocking the IL-4/IL-13 axis might prevent fibrosis. Dupilumab, a monoclonal antibody targeting the α subunit of the Interleukin-4 Receptor (IL-4Rα), blocks IL-4 and IL-13 signaling and has been proposed as a potential treatment for localized scleroderma.[2]

☆ Study conducted at the Dermatology Department and Department of Pathological Anatomy, Hospital Clínico Universitario Lozano Blesa, Zaragoza, Spain.

https://doi.org/10.1016/j.abd.2025.501193

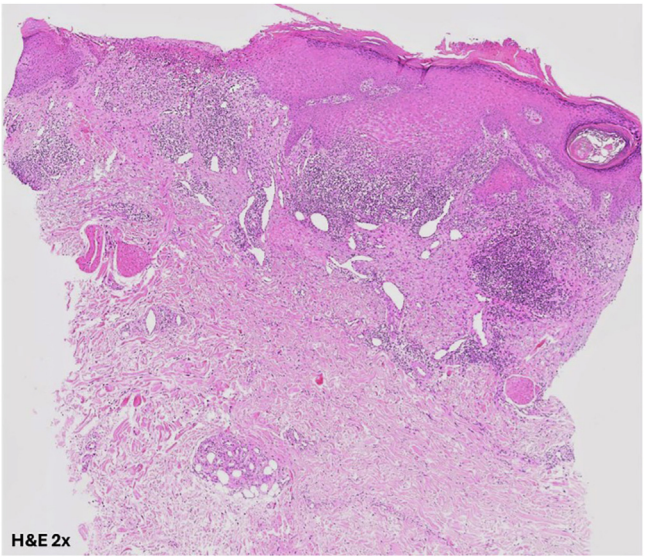

Fig. 2 At low power view, histopathology shows an epidermis with acanthosis and focal excoriation (Hematoxylin & eosin, ×20).

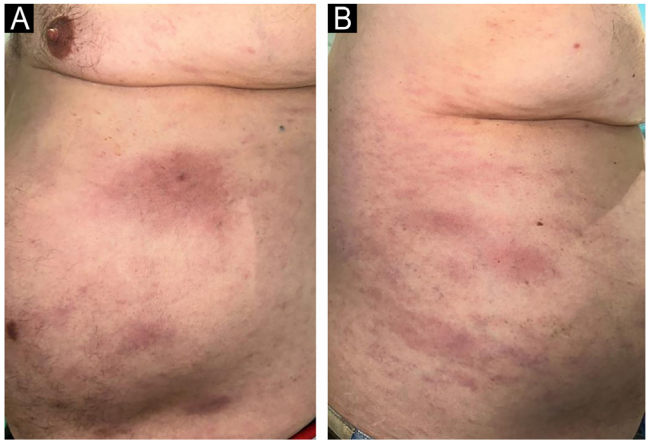

Fig. 3 Morphea plaques. (A and B) Oval erythematous-violaceous plaques on the left and right flanks.

Although only four cases of dupilumab-associated morphea and localized sclerosis have been reported in the literature to date (Table 1), numerous cases of psoriasiform dermatitis mediated by the Th1 and Th17 pathways have been reported following initiation of dupilumab therapy.[1,3–5] In our case, this may be attributed to the inhibition of IL-4, which can promote overproduction of the IL-4δ2 variant. This IL-4 variant increases levels of IFN-γ and TNF-α, activating the Th1 pathway and inflammation, ultimately facilitating collagen deposition in the extracellular matrix.[3]

CD34+ dermal dendritic cells are usually distributed throughout the reticular dermis and are thought to play roles in wound healing and maintaining dermal architecture.[6] The loss of CD34 expression helped distinguish morphea from other dermatoses with lymphohistiocytic infiltrates in the dermis and is a phenomenon seen in disorders involving collagen degeneration, such as morphea.[7,8] CD34 expression in the dermis is inversely proportional to the extent of morphea; thus, in a case like ours, where CD34 expression was

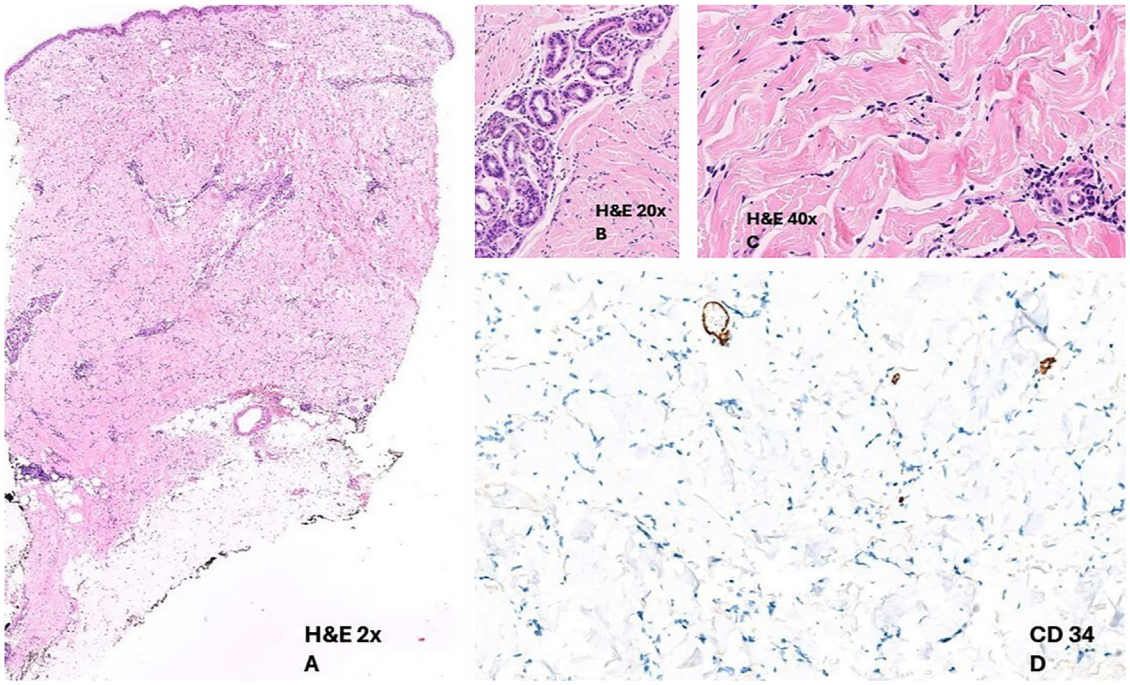

Fig. 4 (A) Preserved epidermis and the presence of a perivascular inflammatory infiltrate in the dermis (Hematoxylin & eosin, ×20). (B-C) Eccrine glands without adipose stroma, along with dense collagen. The perivascular infiltrate consists predominantly of lymphohistiocytic elements with occasional plasma cells. This infiltrate is also observed in the interstitium at this magnification (Hematoxylin & eosin, ×200 and ×400). (D) IHC: CD34 staining shows a loss of dermal dendritic cells normally present in healthy skin.

Table 1 Demographic and clinical characteristics of morphea cases following initiation of dupilumab.

Patient	Age	Sex	Underlying condition	Latency period	Clinical presentation	Treatment
1	10 years	Female	Atopic dermatitis	34 weeks after initiation	A plaque on the ankle and foot	Discontinuation of dupilumab. Initiation of methotrexate and oral prednisone
2	14 years	Male	Atopic dermatitis	5 months after initiation	A linear plaque on the scalp	Discontinuation of dupilumab. Initiation of topical corticosteroids; after failure, methotrexate and intravenous methylprednisolone
3	20 years	Female	Atopic dermatitis	8 months after initiation	Multiple plaques on the upper and lower extremities	Discontinuation of dupilumab. Initiation of mycophenolate mofetil
4	67 years	Female	Asthma and chronic rhinitis	5 days after initiation	Multiple lesions on the trunk	Continued dupilumab. Resolution one week after the second injection

lost, there is a higher likelihood of deep tissue involvement. This overlap between deep morphea and eosinophilic fasciitis has been noted.[6] Given the absence of dermal eosinophils and a normal blood count, a diagnosis of morphea was established. Methotrexate and corticosteroids were chosen for treatment due to their efficacy in both nodular prurigo and morphea.

In conclusion, we present a case of generalized morphea following the initiation of dupilumab for nodular prurigo. Blocking IL-4 and IL-13 represents a potential target for treating sclerotic disorders; however, this blockade may disrupt healing mechanisms, favoring collagen deposition, and increase scar tissue through dysregulation of Th1/Th2 signaling pathways.

Research data availability

Does not apply.

Editor

Hiram Larangeira de Almeida Jr.

Financial support

None declared.

Authors' contributions

José González Fernández: Manuscript preparation and supervision; final manuscript approval.

Mariano Ara Martín: Intellectual participation in the diagnostic and therapeutic management of the case; manuscript review.

Sergio García González: Manuscript preparation; participation in guiding the case.

Sara Pilar Martínez Cisneros: Concept and planning of the study; literature review.

Mar García García: Literature review; manuscript review.

Sonia de la Fuente Meira: Manuscript preparation; final manuscript approval; final decision on the diagnostic and therapeutic management of the case.

Conflicts of interest

None declared.

References

1. Wang S, Berry CT, Treat JR, Jen M. Morphea after initiation of dupilumab in two pediatric atopic dermatitis patients. Pediatr Dermatol. 2023;40:540–3.
2. Nguyen JK, Austin E, Huang A, Mamalis A, Jagdeo J. The IL-4/IL-13 axis in skin fibrosis and scarring: mechanistic concepts and therapeutic targets. Arch Dermatol Res. 2020;312:81–92.
3. Kassamali B, Elman SA, Sheets AR, LaChance AH, Merola JF. A case of paradoxical fibrosis and development of morphea in a patient on dupilumab. JAAD Case Rep. 2021;17:7–8, http://dx.doi.org/10.1016/j.jdcr.2021.08.018.
4. Falcinelli F, Giorli A, Biagini C, Romano A, Sorrentino E, Defraia C, et al. A case of transient paradoxical early morphea-like eruption after the first injection of dupilumab in a patient with chronic rhinosinusitis with nasal polyps. Ital J Dermatol Venerol. 2023;158:495–7.
5. Su Z, Zeng YP. Dupilumab-associated psoriasis and psoriasiform manifestations: a scoping review. Dermatology. 2023;239:646–57.
6. Lee JS, Park HS, Yoon HS, Chung JH, Cho S. CD34 stromal expression is inversely proportional to smooth muscle actin expression and extent of morphea. J Eur Acad Dermatol Venereol. 2018;32:2208–16.
7. Onajin O, Wieland CN, Peters MS, Lohse CM, Lehman JS. Clinicopathologic and immunophenotypic features of eosinophilic fasciitis and morphea profunda: a comparative study of 27 cases. J Am Acad Dermatol. 2018;78:121–8.
8. Daruish M, Zidan A, Greenblatt DT, Stefanato CM. Loss of CD34 expression within an interstitial dermal lymphoid cell infiltrate is a helpful clue to the diagnosis of morphea. Dermatopathology (Basel). 2023;10:70–4.

José González Fernández [a,b,c,*],
Mariano Ara Martín [a,b,c], Sergio García González [a,b,c],
Sara Pilar Martínez Cisneros [a,b,c],
Mar García García [b,c,d], Sonia de la Fuente Meira [a,b,c]

[a] *Department of Dermatology, Lozano Blesa University Clinical Hospital, Zaragoza, Spain*
[b] *Instituto de Investigación Sanitaria de Aragón, Zaragoza, Spain*
[c] *Faculty of Medicine, University of Zaragoza, Zaragoza, Spain*
[d] *Department of Pathology, Lozano Blesa University Clinical Hospital, Zaragoza, Spain*

[*] Corresponding author.
E-mail: jgonzalezfe@salud.aragon.es
(J. González Fernández).

Received 2 December 2024; accepted 23 January 2025
Available online 15 August 2025

SOCIEDADE BRASILEIRA DE DERMATOLOGIA

Anais Brasileiros de Dermatologia

www.anaisdedermatologia.org.br

LETTER - THERAPY

Successful treatment of recalcitrant Sneddon-Wilkinson disease with secukinumab☆

Dear Editor,

In 1956, Drs. Ian Bruce Sneddon and Darrell Wilkinson first described subcorneal pustular dermatosis (SPD), later named Sneddon-Wilkinson disease (SWD) in their honor. They described an unusual chronic blistering eruption that could not be classified as dermatitis herpetiformis or pemphigus.[1] Whether it is a separate entity, or a variant of generalized annular pustular psoriasis (GAPS) remains controversial. Clinically, it is more common in middle-aged women and is characterized by flares of pustular lesions, often with an annular pattern and predominantly involving the flexures. These lesions usually progress to erosions, crusts or scales, and residual hyperpigmentation. Histopathologically, SWD is characterized by the presence of subcorneal neutrophilic pustules with negative direct and indirect immunofluorescence tests. It is most commonly associated with monoclonal gammopathies, predominantly IgA. Dapsone is the treatment of choice. However, relapses in a chronic course are frequent.[2] In this article, we present a case of SWD with a satisfactory response to secukinumab, a monoclonal antibody that selectively inhibits Interleukin (IL) 17A.

A 62-year-old man presented with skin lesions of two years' duration. He had previously been treated with topical and systemic corticosteroids, systemic antihistamines, and doxycycline without improvement. On examination (Figs. 1 and 2), there were generalized multiple flaccid pustules on an erythematous base, eroding into crusted lesions predominantly in the axillary and inguinal folds. There were no other mucocutaneous lesions and no other systemic symptoms. Histopathology (Fig. 3) showed multiple subcorneal neutrophilic pustules and a mixed perivascular and interstitial infiltrate in the superficial dermis. Direct Immunofluorescence (DIF) was negative. Indirect Immunofluorescence (IIF) was negative for antibodies against epidermal intercellular substances and basement membrane antigens. Immunoblotting confirmed these results and was also negative for antibodies against desmocollin 1 and 3. Genetic testing to exclude IL-36 receptor antagonist deficiency (DITRA syndrome) was also negative. Blood and urine analysis and electrophoresis with immunofixation revealed IgA kappa gammopathy of uncertain significance. Treatment was started consecutively with dapsone, methotrexate, and acitretin, with therapeutic failure with all three agents. Finally, treatment with secukinumab at a dose of 300 mg/week for 4 weeks followed by 300 mg/4 weeks of maintenance was chosen, with a complete response achieved after 2 months of treatment and maintained after 18 months of treatment (Fig. 4). No

Figure 1 Clinical presentation of inguinal lesions before initiation of secukinumab. Erythematous papules and plaques with overlying peripheral pustules.

☆ Study conducted at the Hospital Universitario y Politécnico La Fe, Valencia, Spain.

https://doi.org/10.1016/j.abd.2025.501178

Figure 2 Dermoscopic presentation of the lesions. Pustule with a slightly erythematous base.

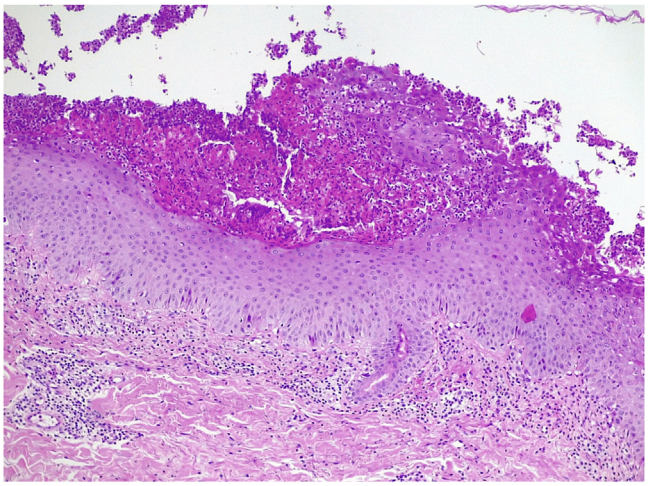

Figure 3 Histopathological presentation of the lesions (Haematoxylin & eosin 100×). Moderate perivascular and interstitial inflammatory infiltrate in the dermis, predominantly polymorphonuclear, and in the epidermis minimal spongiosis, parakeratosis and clusters of polymorphonuclear leukocytes forming subcorneal microabscesses. There were no bacterial colonies, acantholysis, papillary atrophy, suprapapillary atrophy or confluent parakeratosis.

adverse effects were reported, and the patient remained haematologically stable.

SWD can be challenging both diagnostically and therapeutically. For some authors, it represents a variant of GAPS, while for others it is a separate entity based on its characteristic predilection for folds, non-involvement of nails, palms, soles, and hair, and histological findings with less psoriasiform hyperplasia, fewer tortuous telangiectasias in the dermal papilla and less mitotic figures. However, it must be distinguished from SPD-type IgA pemphigus, which is clinically and histologically identical, although DIF studies show IgA immunoreactivity to desmocollin 1, a desmosomal component of keratinocytes, at the subcorneal level. The presence of anti-desmocollin 1

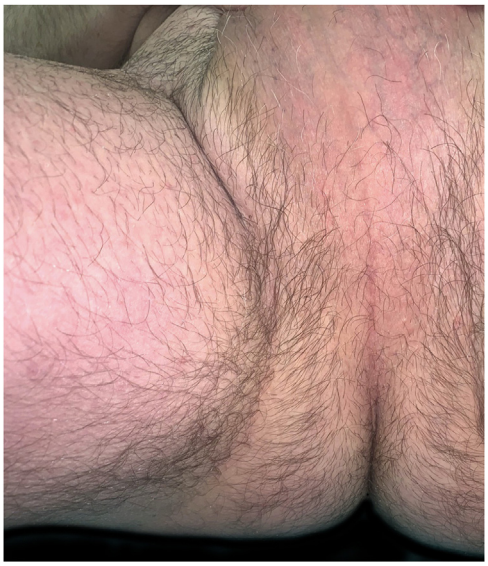

Figure 4 Clinical presentation of the inguinal lesions after 18 months of secukinumab treatment. Complete resolution of the lesions.

IgA antibodies is also demonstrated in SPD-type IgA, by using Enzyme-Linked Immunosorbent Assay (ELISA), IIF, or immunoblotting. It must also be distinguished from DITRA syndrome, a rare autoinflammatory disorder caused by mutations in the IL36RN gene, which also causes generalized pustular psoriatic lesions. The classic treatment in SWD, which generally produces a good response, is dapsone.[2] However, sometimes other treatments must be used because of treatment failure or side effects. In recent years, favorable results have been reported after treatment with anti-TNF agents (adalimumab, etanercept, infliximab), IL-23 inhibitors (guselkumab), phosphodiesterase-4 inhibitors (apremilast, roflumilast) and, more recently, secukinumab.[3–5] We postulate that the response to this drug in our patient with SWD is explained by the role of IL-17A in neutrophil chemotaxis and the demonstrated efficacy of anti-IL-17 agents in pustular psoriasis, an entity closely related to SWD.[5] In conclusion, we present a case of refractory SWD with a satisfactory response to secukinumab. IL-17 inhibitors may be promising therapeutic agents for the treatment of patients with recalcitrant SWD.

Research data availability

Does not apply.

Editor

Hiram Larangeira de Almeida Jr.

Financial support

None declared.

Authors' contributions

Miguel Mansilla-Polo: Managed clinical treatment and procedures, and wrote the initial version of the article.

Daniel Martín-Torregrosa: Managed clinical treatment and procedures, and wrote the initial version of the article.

Vicent Martínez-Cozar: Managed the pathological study.

Rafael Botella-Estrada: Supervised the work.

Conflicts of interest

None declared.

References

1. Sneddon IB, Wilkinson DS. Subcorneal pustular dermatosis. Br J Dermatol. 1956;68:385–94.
2. Watts PJ, Khachemoune A. Subcorneal pustular dermatosis: a review of 30 years of progress. Am J Clin Dermatol. 2016;17:653–71.
3. Romagnuolo M, Muratori S, Cattaneo A, Marzano AV, Moltrasio C. Successful treatment of refractory Sneddon-Wilkinson disease (subcorneal pustular dermatosis) with infliximab. Dermatol Ther. 2022;35:e15552.
4. Teraki Y, Sugai S. Treatment of recalcitrant subcorneal pustular dermatosis with guselkumab. Int J Dermatol. 2021;60:e153–4.
5. Liu F, Tang Y, Li X, Wang L, Zhang J. Successful treatment of recalcitrant subcorneal pustular dermatosis with Secukinumab: a case report. J Dermatol. 2024;51:e178–9.

Miguel Mansilla-Polo [a,b,*], Daniel Martín-Torregrosa [a,b], Vicent Martínez-Cozar [c], Rafael Botella-Estrada [a,b,d]

[a] *Department of Dermatology, Hospital Universitario y Politécnico La Fe, Valencia, Spain*
[b] *Instituto de Investigación Sanitaria La Fe, Valencia, Spain*
[c] *Department of Pathology, Hospital Universitario y Politécnico La Fe, Valencia, Spain*
[d] *Department of Medicine, Facultat de Medicina i Odontología, Universitat de Valencia, Valencia, Spain*

[*] Corresponding author.
E-mail: miguel_yecla96@hotmail.com (M. Mansilla-Polo).

Received 26 December 2024; accepted 21 January 2025
Available online 13 August 2025

SOCIEDADE BRASILEIRA DE DERMATOLOGIA

Anais Brasileiros de Dermatologia

www.anaisdedermatologia.org.br

LETTER - THERAPY

Successful treatment of refractory eosinophilic annular erythema with tofacitinib☆

Dear Editor,

Eosinophilic Annular Erythema (EAE) is a rare eosinophilic dermatosis characterized by annular erythematous plaques with varying degrees of pruritus. Treatment options for EAE are often limited and the disease is often refractory with a recurrent course. Highlighting the potential of tofacitinib in the treatment of EAE, we report a case of refractory EAE that was effectively treated with tofacitinib.

A 34-year-old female was admitted to our department with pruritic annular plaques on the trunk and proximal extremities. The patient had no history of food or drug allergies or other chronic diseases. Physical examination revealed scattered dark red annular plaques with raised borders on the neck, anterior chest, waist, and abdomen (Fig. 1A–D). Oral hydroxychloroquine and antihistamines were given for two weeks with no response. Laboratory tests revealed an elevated eosinophil count (0.78×10^9/L), while no abnormalities were observed in liver enzymes, renal function, urinalysis, total serum IgE levels, antinuclear, anti-DNA, and HIV tests. A skin biopsy showed a superficial perivascular infiltration composed predominantly of eosinophils. There was no evidence of vasculitis, flames figures, dermal mucin, or vacuolar changes. Direct immunofluorescence was negative. Given the clinical presentation and the lack of flame figures, Wells syndrome was excluded. The diagnosis of EAE was made on the basis

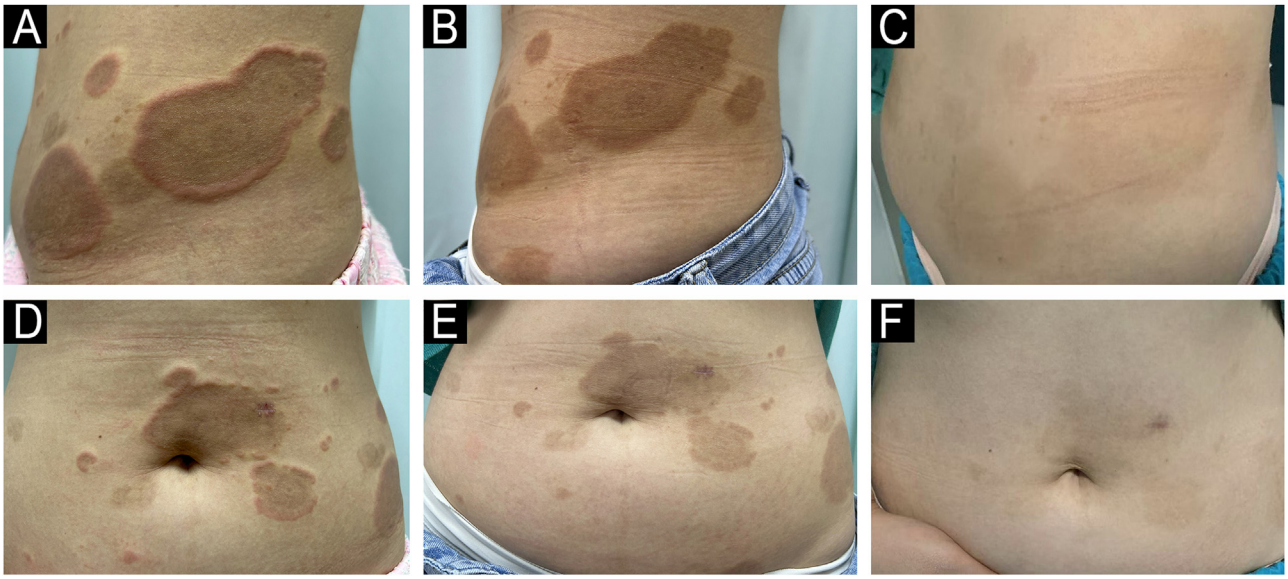

Fig. 1 Clinical image of the patient treated with tofacitinib. (A–D) The patient presented with scattered dark red annular plaques with raised borders on the truck before treatment. (B–E) Remission of clinical manifestations after treatment with tofacitinib in a week. (C–F) The lesions were completely cleared without any recurrence in a 4-month-follow up.

☆ Study conducted at the Department of Dermatology, the First Affiliated Hospital of Chongqing Medical University.

https://doi.org/10.1016/j.abd.2025.501194

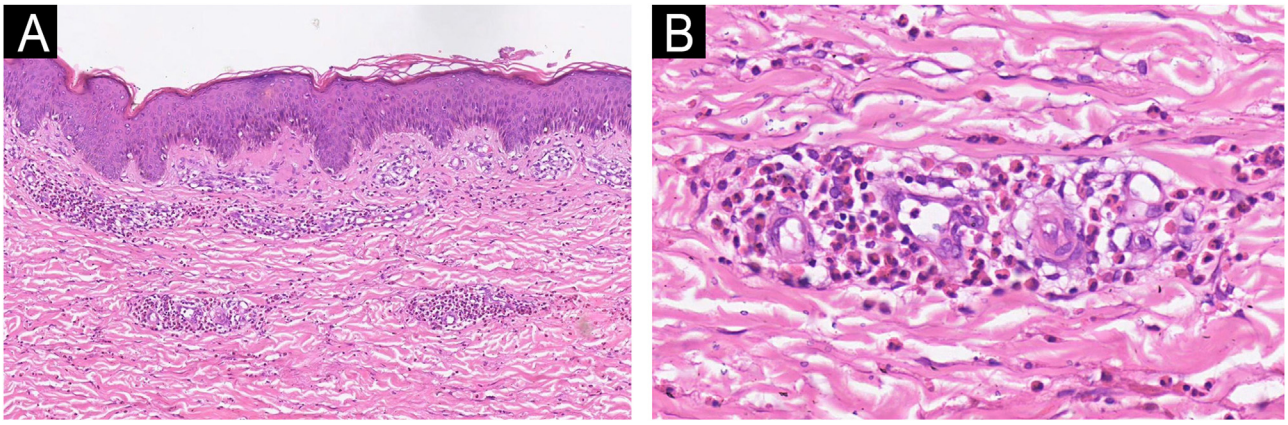

Fig. 2 (A) Histopathology showed a superficial perivascular infiltration (Hematoxylin & eosin, ×100). (B) A high-power field showed perivascular infiltration composed predominantly of eosinophils (Hematoxylin & eosin, ×400).

of the above findings. Monotherapy with tofacitinib 5 mg twice daily was started. After one week of treatment, the patient showed remarkable improvement. The annular erythema became lighter in color, blurred in outline and the raised margins disappeared (Fig. 1B–E). She was treated for a further two weeks. At a follow-up visit four months after treatment, we observed that the lesions were almost completely cleared without recurrence (Fig. 1C–F). The histopathological characteristics are shown in Fig. 2 (Fig. 2A–B). In a follow-up phone call after 8 months, the patient was completely cured and there was no relapse.

EAE is a rare self-limited eosinophilic dermatosis with a relapsing and remitting course. It can affect individuals of all ages, though it is more commonly seen in young adults. While the exact incidence remains unclear, EAE has been associated with drug reactions, allergic responses, and underlying systemic conditions, such as systemic lupus erythematosus and eosinophilic gastroenteritis. An interesting case report highlights a potential association between EAE and Primary Biliary Cholangitis (PBC), a systemic disease that has not been previously reported in the literature.[1] The differential diagnosis of EAE includes Wells syndrome, rheumatoid erythema annulare, erythema annulare centrifugum, and other eosinophilia-associated skin diseases, and some authors consider it to be a subtype of Wells syndrome.[2] Wells' syndrome and EAE are two eosinophil-associated dermatoses that share some similarities in clinical presentation and histopathology, but there are important differences. Wells' syndrome presents as erythematous, edematous plaques that resemble cellulitis, and the lesions may be accompanied by pruritus or pain. The dermis is heavily infiltrated with eosinophils, with characteristic ''flame figure'', while lesions of EAE are circular or arcuate erythematous plaques with raised margins and fading in the center, and the lesions are usually asymptomatic or mildly pruritic, with eosinophilic infiltration of the dermis, but without the ''flame figure''.

Due to the rarity of EAE, there is no standard treatment for the disease. Currently, first-line therapies are glucocorticoids, antihistamines, chloroquine, and hydroxychloroquine. Alternative treatment options include ciclosporin, mepolizumab, dapsone, narrowband UVB, doxycycline, and benralizumab (Table 1).[3] However, the treatment of EAE remains a challenge due to the high relapse rate and unsatisfactory therapeutic efficacy.

EAE has not been clearly elucidated, but hypersensitivity reactions to unidentified antigens have been proposed, while aberrant tissue-resident eosinophils may participate in the disease. Tofacitinib selectively inhibits JAK1 and JAK3 to modulate immune cell activity and reduce inflammation. It inhibits the activation of T cells and B cells through the JAK-STAT pathway. It can suppress the production of several inflammation-related cytokines such as IL-4, IL-5 and IL-13, which play critical roles in proliferation, activation, and recruitment of eosinophils.[4–6] Recent studies suggested that inhibiting JAK-STAT signaling, especially JAK1 signaling, can both suppress Th2 differentiation and eosinophil activation.[7] As the JAK-STAT pathway mediates important cellular processes such as immune response and inflammation, tofacitinib can be used as a targeted therapy by blocking these pathogenic pathways.[6]

To conclude, to the best of our knowledge, we first reported a case of refractory EAE successfully treated with tofacitinib. Our observation supported that JAK inhibitors may be a promising therapy option and shed a bright light on the treatment of EAE. However, further studies are needed to provide more evidence and confirm the findings.

Research data availability

The data that support the findings of this study are available from the corresponding author upon reasonable request.

Editor

Hiram Larangeira de Almeida Jr.

Table 1 Alternative treatment options for EAE and the outcome.

Treatment	Treatment Mechanisms	Reported Outcomes	Administration	Potential Side Effects
Ciclosporin	Calcineurin inhibitor, suppresses T-cell activation	Effective in reducing inflammation and improving symptoms in some cases	Oral	Hypertension, nephrotoxicity
Upadacitinib	JAK1 inhibitor, reduces immune cell activation	Reduced disease activity and inflammation; limited data in EAE	Oral	Headache, upper respiratory infections
Mepolizumab	IL-5 inhibitor, reduces eosinophil counts	Decreased eosinophil infiltration and inflammation; limited evidence for EAE	Subcutaneous, monthly	Headache, nasopharyngitis
Dapsone	Anti-inflammatory, antimicrobial properties	Improvement in skin symptoms in EAE; limited data on systemic improvement	Oral	Hemolysis, methemoglobinemia
Narrowband UVB	UV radiation, reduces skin inflammation	Effective for skin lesions in EAE; minimal evidence for systemic benefit	Topical	Skin irritation, erythema
Doxycycline	Antibiotic with anti-inflammatory effects	Possible benefits for chronic inflammation; limited evidence in EAE	Oral	Gastrointestinal upset, photosensitivity
Benralizumab	IL-5 receptor antagonist, reduces eosinophil counts	Significant eosinophil reduction; potential benefit in EAE-related inflammation	Subcutaneous, every 4 weeks	Headache, upper respiratory tract infections

Financial support

None declared.

Authors' contributions

Ying-Luo Niu: Collected clinical data, including images and medical records, and drafted the manuscript; participated in the diagnostic discussion and contributed to case interpretation.

Hai-Yang He: Assisted with data collection; participated in the diagnostic discussion and contributed to case interpretation.

Sheng Fang: Supervised the project and provided critical revisions; participated in the diagnostic discussion and contributed to case interpretation.

Conflicts of interest

None declared.

References

1. López Sanz P, de Sande Rivera N, Guerrero Ramírez C, Manso Córdoba S, Rodríguez de Vera Guardiola C, et al. A case of eosinophilic annular erythema as a presenting sign for primary biliary cholangitis. An Bras Dermatol. 2024;99:951–3.
2. Rongioletti F, Fausti V, Kempf W, Rebora A, Parodi A. Eosinophilic annular erythema: an expression of the clinical and pathological polymorphism of Wells syndrome. J Am Acad Dermatol. 2011;65:e135–7.
3. Chastagner M, Shourik J, Jachiet M, Battistella M, Lefevre G, Gibier JB, et al. Treatment of eosinophilic annular erythema: retrospective multicenter study and literature review. Ann Dermatol Venereol. 2022;149:123–7.
4. Okazaki T, Takahashi T, Asano Y. Eosinophilic annular erythema successfully treated with dupilumab: a case report. J Dermatol. 2024;51:e249–50.
5. Aguilar-Pimentel A, Graessel A, Alessandrini F, Fuchs H, Gailus-Durner V, Hrabě de Angelis M, et al. Improved efficacy of allergen-specific immunotherapy by JAK inhibition in a murine model of allergic asthma. PLoS One. 2017;12:e0178563.
6. Miot HA, Criado PR, de Castro CCS, Ianhez M, Talhari C, Ramos PM. JAK-STAT pathway inhibitors in dermatology. An Bras Dermatol. 2023;98:656–77.
7. Keohane C, Kordasti S, Seidl T, Perez Abellan P, Thomas NS, Harrison CN, et al. JAK inhibition induces silencing of T Helper cytokine secretion and a profound reduction in T regulatory cells. Br J Haematol. 2015;171:60–73.

Ying-Luo Niu, Hai-Yang He, Sheng Fang *

Department of Dermatology, the First Affiliated Hospital of Chongqing Medical University, Chongqing, China

* Corresponding author.
E-mail: fangshengderm@163.com (S. Fang).

Received 12 December 2024; accepted 14 February 2025
Available online 18 August 2025